

## Superior Venacava Thrombus-A Case Report

Bijay Sah, Krishna Gopal Shrestha, Kaushal Kishor Tiwari, D. Jayapal Reddy

Department of CTVS, CMS-TH Bharatpur, Nepal

### Correspondence

Dr. Bijay Sah  
Department of CTVS,  
College of medical sciences-  
Teaching Hospital  
Bharatpur, Nepal  
Email: bijaysah@hotmail.com

DOI: <http://dx.doi.org/10.3126/jcmsn.v12i1.14392>

### ABSTRACT

Superior venacava (SVC) thrombus is a condition requiring immediate diagnosis and treatment. SVC thrombus causes abnormal blood flow through the SVC resulting in delay in venous return from the head, neck and upper extremity to the heart. The presenting symptoms of SVC obstruction include headache, hoarseness of voice, dyspnea, and laryngeal edema, dizziness, swelling of face, neck, and upper extremity. We hereby present a case of SVC thrombus who presented to the casualty department of COMS-TH with features of SVC syndrome which was diagnosed and managed promptly.

**Key words:** Superior venacava obstruction, superior vena cava thrombus. Superior venacava syndrome (SVCS)

**Citation:** Sah B, Shrestha KG, Tiwari KK, Reddy DJ. Superior Venacava Thrombus-A Case Report. JCMS Nepal. 2016;12(1):33-5.

### INTRODUCTION

The superior venacava (SVC) is a thin walled, vascular structure surrounded by stiff parts like paratracheal and perihilar lymph nodes, rigid trachea, bronchus and the sternum and therefore it can get compressed easily. The low intravascular pressure also allows for the possibility of thrombus formation or collapse of the vessel.<sup>1-3</sup>

Complete SVC obstruction may be due to intravascular thrombosis combined with external pressure whereas incomplete SVC block is more common due to external pressure from the surrounding structures without thrombosis. The common cause of SVC obstruction in western countries is malignancy whereas in developing countries, nonmalignant causes like mediastinal fibrosis, catheters or pacemaker wires induced thrombosis, idiopathic thrombosis continue to be of significant percentage.<sup>1-2</sup>

The principal collateral venous return of SVC are the azygos vein, intercostals veins, mediastinal veins, paravertebral veins, hemiazygos vein, thoracoepigastric vein, internal mammary vein, thoracoacromioclavicular venous plexus, anterior chest wall veins, superior/inferior phrenic vein, pericardiophrenic vein, superficial epigastric vein, accessory hemiazygos vein, and umbilical vein. Despite these collateral veins, venous pressure is almost raised in the upper venous parts in obstructed SVC. Pressure of between 200-500 cm H<sub>2</sub>O, has been documented in some SVC obstruction.<sup>2</sup>

The SVC obstruction features develops when the

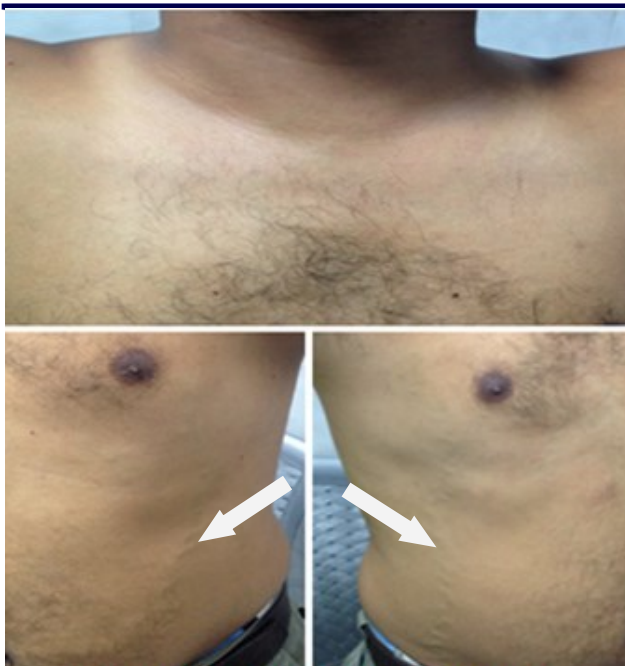ability of collateral blood vessels exceeds its capacity to compensate for the SVC obstruction. The typical symptoms of SVC obstruction are dyspnea, swelling of the extremity and trunk, cough, orthopnea, nasal stuffiness and headache. Neurological symptoms such as dizziness and confusion are late findings as cerebral edema occurs.

Death from SVC obstruction depends on underlying cause and the degree of obstruction of the blood flow. Patients with features of throat and brain edema have the dangerous life alarming complains of SVC obstruction. Ten percentages of patients with carcinoma bronchus and around 45 % of patients with lymphoma, who presented with SVC thrombus post radiation therapy, lived less than 30 months. Patients who are not treated for malignant SVC obstruction survive only for few weeks.<sup>3</sup>

### CASE PRESENTATION

A 31 year old man presented to the emergency department complaining shortness of breath (NYHA III-IV) for three day, swelling of the face, neck and upper extremities for 30 days (Fig 1). The swelling was slow and progressive and there was no obvious relieving and exervating factors.

Two years back, he had suffered from Scleredema adultorum and was treated with steroids and other supportive measures for six weeks. After that he was doing fine with no any regular medications. He denied any history of trauma, acute or chronic medical or surgical illness and his family history was not significant. He was non-smoker but had

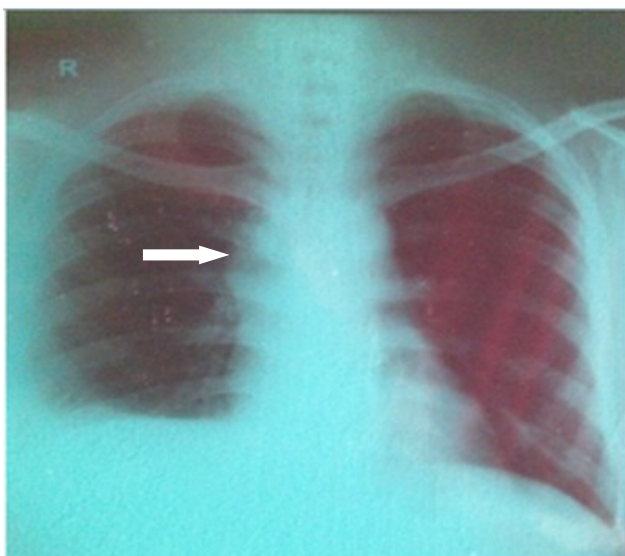


**Fig 1:** Dilated Superficial Veins

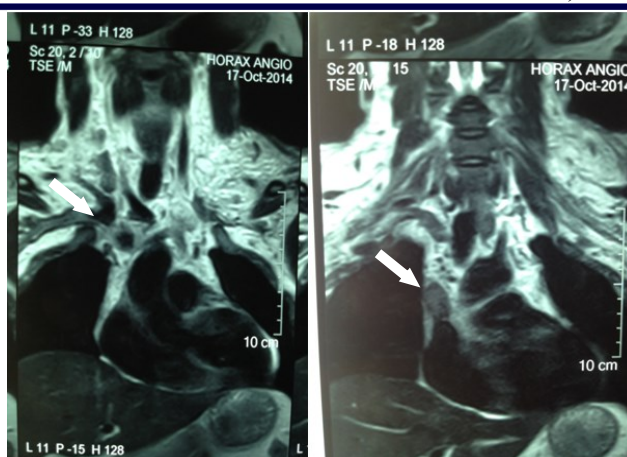
habit of chewing tobacco almost every time after meal for last five years.

His general condition was fair and his chest, cardiovascular and abdominal examination was normal. He did not have jaundice, anemia, lymphadenopathy, clubbing, and cyanosis. He had pitting edema of his upper extremities, chest and neck. His vitals were within normal range with oxygen saturation of 92% in room air.

His routine blood tests like blood sugar random, complete blood count, renal function tests, liver function tests, bleeding profile, serology and urine routine examination was within normal range. His chest x-ray showed mildly widened mediastinum and superior venacava (Fig 2) and ECG showed



**Fig. 2:** Chest X-Ray with SVC thrombus



**Fig 3:** MRI showing SVC thrombus

tachycardia (HR 108/m) with RVH.

Ultrasound of the abdomen showed mild hepatomegaly with mild thickened urinary bladder wall. Echocardiography showed normal study with LVEF of 70% with suspicion of superior venacava obstruction. Further investigation with Magnetic Resonance Imaging showed SVC thrombus with multiple collaterals (Fig 3).

The patient was managed with oxygen supplement of two liters per minute and intravenous line was inserted for anticoagulants, fluids, analgesic and diuretics. Patient was admitted to intensive care unit and continuous ECG, vitals, oxygen saturation and urine output was monitored. Low molecular weight heparin, 1mg/kg bodyweight was prescribed along with oral aspirin 75 mg/d and overlapped with oral warfarin 5 mg/day to reach the PT INR of 2-3 times control.

After four to five days the patient swelling started decreasing and was mild symptomatic (SOB NYHA I-II). The patient was shifted to the general ward and mobilized. The intramuscular LMWH was discontinued after fifth day and patients was discharged on oral warfarin 2 mg/d and aspirin 75 mg/d and followed up every week with PT, INR report till targeted INR was reached.

The patient remained on warfarin for one year till last follow-up with only mild symptoms and small impacted thrombus in the superior venacava still existed on CECT chest.

**DISCUSSION**

Superior vena cava (SVC) thrombus is a condition requiring immediate diagnosis and management. SVC thrombus causes gradual, insidious obstruction of the superior venacava and is often associated with delayed symptoms. The symptoms develop slowly as the collateral venous pressure, to

compensate for the SVC obstruction increases, resulting in interstitial edema and retrograde collateral flow.<sup>4,5</sup>

In our case the patient had swelling of the upper extremities, chest wall and neck which was compressing the trachea and causing severe dyspnoea. The CECT showed the thrombus in the superior venacava and there was no evidence of malignancy, so immediately anticoagulant overlapped with oral anticoagulant was started and the patient responded well. The swelling decreased and the patient was able to breathe and able to walk. The cause for the superior venacava obstruction was idiopathic in this case. All the investigations were negative for malignancy and any other lesions were not detected by the multi-planner MR imaging performed in 3.0 T MR Platform.

Open surgical reconstruction (OSR) is the main surgical treatment for benign cause of superior venacava obstruction. However, it's not always feasible in several surgical centers. Newer advances in endovascular repair (EVR) with stent or graft seem to be promising but data on its durability remain scarce. Anticoagulant and thrombolytic therapy are initial approach for management in nonmalignant patients and many patients with idiopathic lesions respond to the treatment.<sup>6,7</sup>

## CONCLUSION

Superior venacava (SVC) thrombus is a condition requiring immediate diagnosis and management and if not treated promptly, may land up into devastating consequences.

## REFERENCES

1. Kinney TB, Rose SC. Intraarterial pressure measurements during angiographic evaluation of peripheral vascular disease: techniques, interpretation, applications, and limitations. *AJR Am J Surg.* 1996;166(2):277-84. DOI: 10.2214/ajr.166.2.8553930.
2. Chen JC, Bongard F, Klein SR. A contemporary perspective on superior vena cava syndrome. *Am J Surg.* 1990;160(2):207-11. DOI: 10.1016/S0002-9610(05)80308-3.
3. Abner A. Approach to the patient who presents with superior vena cava obstruction. *Chest.* 1993;103(4 Suppl):394S-7S. DOI: 10.1378/chest.103.4\_Supplement.394S. PMID:8462332
4. Schwartz EE, Goodman LR, Haskin ME. Role of CT scanning in the superior vena cava syndrome. *Am J Clin Oncol.* 1986;9(1):71-8. DOI: 10.1097/00000421-198602000-00017. PMID:3953493.
5. Adelstein DJ, Hines JD, Carter SG, Sacco D. Thromboembolic events in patients with malignant superior vena cava syndrome and the role of anticoagulation. *Cancer.* 1988;62(10):2258-62. DOI: 10.1002/1097-0142(19881115)62:10<2258::AID-

CNCR2820621031>3.0.CO;2-I.

6. Rosch J, Bedell JE, Putnam J, Antonovic R, Uchida B. Gianturco expandable wire stents in the treatment of superior vena cava syndrome recurring after maximum-tolerance radiation. *Cancer.* 1987;60(6):1243-6. DOI: 10.1002/1097-0142(19870915)60:6<1243::AID-CNCR2820600614>3.0.CO;2-5
7. Sato R, Noma A, Kurachi Y, Irisawa H. Effects of intracellular acidification membrane currents in ventricular cells of the guinea pig. *Circ Res.* 1985;57(4):553-61. DOI: 10.1161/01.RES.57.4.553. PMID:2412722.