

Cardiac Myxoma-Surgical Treatment and Outcome

D. Jayapal Reddy¹, Bijay Sah²

¹Professor and Head of Department, ²MCh Resident, Department of CTVS, College of Medical Sciences, Teaching Hospital, Bharatpur, Nepal

Correspondence

Dr. D. Jayapal Reddy,
Department of CTVS,
College of Medical Sciences,
Bharatpur, Nepal.

Email:

djayapalreddy@gmail.com

DOI: <http://dx.doi.org/10.3126/jcmsn.v11i2.13673>

ABSTRACT

Background & Objectives: Cardiac Myxomas include benign and malignant neoplasms, arising within the cardiac chambers or in the myocardium. Because, it is a rare tumor of the heart, there seems a lack of adequate data and its recent optimal treatment for both benign and malignant tumors is limited. **Materials & Methods:** Literature was searched for review and prospective study of cardiac myxoma surgery done between August 1990 and February 1996 was presented. A total of six patients underwent surgery for cardiac myxoma. All patients (five female; one male) underwent complete excision of the tumor and none of them showed features of remission after six month follow-up. **Results:** Cardiac Myxoma is a rare disease and it most commonly occurs in the fourth decade of life. Out of six patients operated, five were female and one was male and the age of the patients was between 22 and 50 years (mean age 31). The location of tumors was: LA myxoma in five cases, RA myxoma in one case. Preoperative symptoms were dyspnea (NYHA class III) in four cases, orthopnea in two cases, postural giddiness or syncope in three cases, palpitation in two cases and chest pain in two cases. The mean duration of onset of symptoms to diagnosis was eight months. Echocardiography showed abnormalities in all six cases including mitral stenosis in five cases, and tricuspid stenosis in one case. No recurrence was noted after six months of follow-up after the surgery. **Conclusion:** Cardiac myxoma is considered an emergency condition which needs urgent procedure, particularly if the patient has a history of embolism or syncope. Atrial Myxoma tends to have more secondary scenarios by embolization.

Key words: Atrial Myxoma, Cardiac Myxoma, Cardiac Tumors, Heart Tumors

Citation: Reddy DJ, Sah B. Cardiac Myxoma-Surgical Treatment and Outcome. JCMS Nepal. 2015;11(2):27-30.

INTRODUCTION

Cardiac tumours include benign and malignant neoplasms, arising within the cardiac chambers or in the myocardium. Metastatic neoplasms to the heart are not included.

Among the earliest surgical approaches to myxoma was that of Bahanson and Newman, who in 1952 removed a myxoma from the right atrium via a right anterior thoracotomy using a short period of caval occlusion at normothermia. The patient died 24 days later from complications related to transfusion and electrolyte imbalance.¹⁻³

Using cardiopulmonary bypass (CBP), Crafoord in 1954 successfully excised a myxoma from the left atrium as did Bigelow in 1955, using hypothermia and inflow occlusion. Successful excision of a right atrial myxoma was reported in 1957 and in 1958. A left ventricular myxoma was excised in 1959 by Kay. The first successful excision of a right

ventricular myxoma was undertaken in 1960. By 1964, only 60 cases of intracardiac myxoma had been successfully removed. Bilateral myxoma was removed in 1967. In 1967, Gerbode described recurrence of a left atrial myxoma four years after initial excision.⁴⁻⁷

Myxomas may produce symptoms of hemodynamic derangement from the obstruction of flow within the cardiac chambers or from deformation of a cardiac valve, with resultant incompetence, they may produce symptoms by embolization; and, least commonly, they may produce so called constitutional symptoms.⁸⁻¹¹

Surgical removal is indicated whenever diagnosis of cardiac myxoma is confirmed. Generally it is considered an urgent procedure, particularly if the patient has history of embolism or syncope since it has been noted that many patients dies from embolic complications while waiting for

operation.^{12, 13}

MATERIALS AND METHODS

This Six patients underwent cardiac surgery for cardiac myxoma in Osmania Medical College, Hyderabad, between August 1990 and February 1996. The medical records were retrospectively studied and case file submitted. This article intends to review some of the clinical features and operative technique of cardiac myxoma with associated mortality and morbidity conditions.

During this period, six patients were preoperatively diagnosed as cardiac myxoma by echocardiography. Cardiac catheterization was avoided and coronary angiography was done only if the patients had history of chest pain with ECG changes.

Out of six patients, five were female and one was male and the age of the patient was between 22 and 50 years (mean age 31). Preoperative symptoms were dyspnea (NYHA class III) in four cases, orthopnea in two cases, postural giddiness or syncope in three cases, palpitation in two cases and chest pain in two cases (Table 1).

Table 1. Demographic Data

S. No	Age	Sex	Diagnosis	Complication	Operation Technique
1	50	M	LA Myxoma	None	Excision of Myxoma under CPB
2	45	F	LA Myxoma	None	Excision of Myxoma under CPB
3	40	F	LA Myxoma	None	Excision of Myxoma under CPB
4	35	F	RA Myxoma	None	Excision of Myxoma under CPB
5	45	F	LA Myxoma	None	Excision of Myxoma under CPB
6	22	F	LA Myxoma	Renal Failure	Excision of Myxoma under CPB

The mean duration of onset of symptoms to diagnosis was eight months. Chest x-ray showed abnormalities in two patients including straight left heart border, cardiomegaly and increased pulmonary vasculature. Echocardiography showed abnormalities in all six cases including atrial fibrillation, left atrial enlargement, right axis deviation, mitral stenosis in five cases, and tricuspid stenosis in one case (Table 2).

Median sternotomy was done in all the patients, and the operative procedure was performed under normothermia in five patients and moderate hypothermia in one patient under cardio pulmonary

Table 2: Clinical Features

Features	No.
Sex	
Female	5
Male	1
Location of Tumors	
LA septum	5
RA Septum	1
Symptoms	
Dyspnea	4
Palpitation	2
Chest Pain	2
Syncopal Attacks	2
Past History	
Hypertension	1
RHD	1

bypass. Cardio Pulmonary Bypass (CPB) with aortic and bicaval cannulation was used. Myocardial protection was by cold antegrade blood or crystalloid cardioplegia. LA myxoma was approached by right atrial trans-septal incision and right atrial incision for RA myxomas and RV myxoma. Manipulation of the tumors was avoided till the aorta was cross clamped. All the tumors were completely excised with a cuff of interatrial septum and the four cardiac chambers were inspected for any remaining myxomas (Table 3).

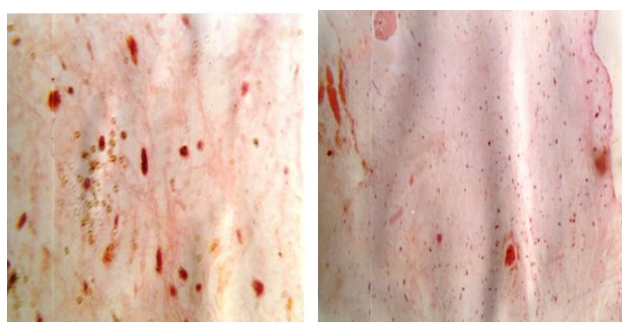Routine histopathological examination was done in all patients were conformed myxoma. All the patients were followed up till six months with clinical examination, chest x-ray, electrocardiography and routine echocardiography.

Table 3: Operation Methods

Methods	No
Left atriotomy	1
Right atriotomy	4
Bilateral approach	1
Direct closure of defect	6

RESULT

All patients with LA myxoma had rough and thickened mitral valve leaflets with mild rheumatic mitral stenosis and did not require any mitral commissurotomy. The location of tumors was: LA myxoma in five cases, RA myxoma in one case. Pedunculated myxoma was present in three cases



C1. HYALINE MATRIX AND STELLATE CELLS BLOOD VESSEL FILLED WITH RBC

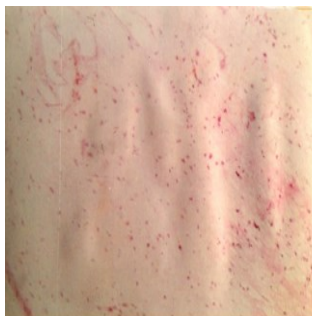C1. STELLATE CELLS IN MATRIX

while sessile myxoma was present in other three cases (Figure C1-C2).

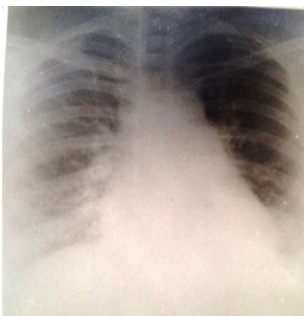Two patients underwent disc excision and two patients underwent direct closure after cauterization. No patients had necrosis of septum or

any post operative complication. All the patients received fresh blood transfusion to normalize the hemoglobin level.

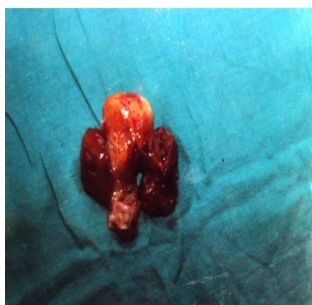
All patients survived and none of them developed



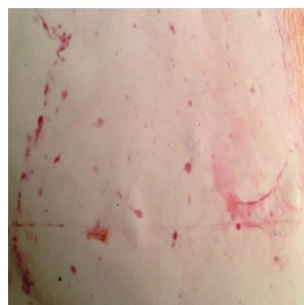
C1. ENDOTHELIAL LINING, STELLATE CELLS IN HYALINE MATRIX



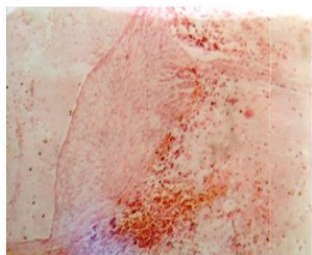
C2. STRAIGHT LEFT HEART BORDER, INCREASED PULMONARY VASCULATURE



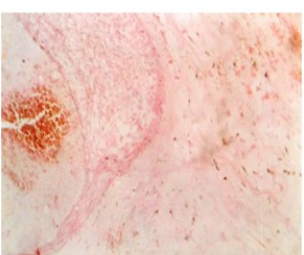
C2. CARDIAC MYXOMA SPECIMEN



C2. ENDOTHELIAL LINING OVER THE TUMOR MARGIN



C5. CLEFT LINED BY ENDOTHELIUM



C5. FEEDING VESSEL FILLED WITH RBC

any kind of complication like atrial fibrillation, myocardial infarction or CVA. Complete follow-up was done and could be traced till six months. There was no late death and all the patients were asymptomatic in NYHA class I (Table 2).

The tumors ranged from 3x3 cm to 6x8 cm in size and weighed 4 to 30 grams. The tumors looked like a gelatinous or pedunculated mass villous or smooth surface. Histopathological examination revealed proliferation of capillaries, blood extravasations and fibrin deposits and microscopic examination confirmed the diagnosis in all the cases (Figure C1-C5).

DISCUSSION

In this study, six cases of cardiac myxomas were studied which were operated and managed in Osmania General Hospital during

1990 to 1996 (seven Years). Five cases were diagnosed clinically as mitral stenosis initially, one case as tricuspid stenosis and were treated in medical wards. With the wide use of 2D echocardiography and colour Doppler, these cases were confirmed as cardiac myxomas, which coincide with the literature on myxomas and some of the textbook standards. The cardio pulmonary bypass, fibrillatory and cardioplegia techniques have contributed for the better results.¹¹

Among the six cases, five cases were female patients. This is in accordance with the well known female dominance in the literature, the age group is in between 22 to 50 years and in these series no familial incidence could be made out. Site of myxoma was low, left side of inter atrial septum in five cases and one was on right side of it and this is of commonality of location.¹²⁻¹³

X-ray wise the five cases have shown the features of mitral stenosis like straightening of left heart border, cardiomegaly, increased pulmonary vascularity of upper zones and increased pulmonary artery size. The one case with RA myxoma has presented with features of tricuspid stenosis.

The right atrial myxoma and the two cases of LA myxoma have shown clear-cut pedicles and other three cases were sessile with a broad based attachment. Two of the LA myxomas required excision of two mm disc of septum around the attachment and the defect was directly closed with three 'O' prolene. In two cases, after the excision of myxoma the site was cauterized which was suggested in the literature and there was no subsequent necrosis at that side during follow up.¹⁴

¹⁵ All the cases in a period of six months were asymptomatic and there was no recurrence. After six months of follow up, they were not traceable.

Out of five LA myxoma cases, one case required Bi-atrial approach, four cases required RA approach and no case required a patch closure. There is no evidence of post operative tumor embolism. Three cases required ventilator support for four to six hours. Two cases required inotropic support for more than 72 hours.

All the tumors were confirmed to the myxomas by histopathological study and RA myxoma was covered by multiple layers of organized and fresh clots. The histological features were common in almost all the cases like stellate cells in hyaline matrix. Tumour is lined by single layer of endothelium including the crevces. There was a demonstrable feeding blood vessel in the pedicle. In RA myxoma the part of the myxoma was covered by organized thrombus and a fresh layer of clot. All

the cases had presented with single myxoma in a single chamber only.

All the six patients were kept on preoperative, intraoperative and postoperative broad spectrum antibiotics and there was no post operative sepsis of median sternotomy wound or drains sites. All the cases were kept on dioxin and diuretic line of management. In all six cases, right pleural, pericardial and retrosternal drains were kept and no evidence of tamponade or excess bleeding was seen. All the patients were given additional fresh blood transfusion during immediate post-operative period in anticipation of excess bleeding tendency in myxoma cordial.

Though the cases are small in number all the features published in the literature were coinciding with our study at Osmania general hospital and the cauterization technique was practiced and proved to be safe without recurrence or any necrosis of inter atrial septum.

CONCLUSION

Cardiac myxoma is a rare tumor of the heart and once the diagnosis is confirmed, urgent surgical treatment is indicated. The principle of surgery includes its wide complete excision with adequate surgical margin and cauterization if needed. Histopathological examination and follow up of all the patients after the surgery is mandatory as there are documented recurrence at various intervals.

REFERENCES

1. Bahnon HT, Newman EV. Diagnosis and surgical removal of intracavitary myxoma of the right atrium. *Bull Johns Hopkins Hosp.* 1953;93(3):150-63. PMID:13094264.
2. Senning A. Developments in cardiac surgery in Stockholm during the mid and late 1950s. *J Thorac Cardiovasc Surg.* 1989;98(5 Pt 2):825-32. PMID:2682018.
3. Newman HA, Cordell AR, Prichard RW. Intracardiac myxomas. Literature review and report of six cases, one successfully treated. *Am Surg.* 1966;32(4):219-30. PMID:5326200.
4. Dein JR, Frist WH, Stinson EB, Miller DC, Baldwin JC, Oyer PE, et al. Primary cardiac neoplasms. Early and late results of surgical treatment in 42 patients. *J Thorac Cardiovasc Surg.* 1987;93(4):502-11. PMID:3560997.
5. Tomassini B, Torta D, Bobba F, Albano T. A left atrial myxoma. The clinical aspects. *Minerva Med.* 1990;81(3 Suppl):45-8. PMID:2325870.
6. Takahara H, Mori A, Tabata R, Watarida S, Onoe M, Okabe H. Left atrial myxoma with production of interleukin 6. *Nihon Kyobu Geka Gakkai.* 1992;40(2):326-9.
7. Stratakis CA, Salpea P, Raygada M. Carney complex. In:

- Pagon RA, Adam MP, Ardinger HH, Wallace SE, Amemiya A, Bean LJH, et al., editors. *Gene reviews.* Seattle (WA); 1993. p.463.
8. Salcedo EE, Cohen GI, White RD, Davison MB. Cardiac tumors: diagnosis and management. *Curr Probl Cardiol.* 1992;17(2):73-137. DOI:10.1016/0146-2806(92)90025-J.
9. Klein MV, Schwaighofer BW, Sobel DF, Hesselink JR. Primary myxoma of the posterior fossa. *Neuroradiology.* 1990;32(3):250-1. DOI:10.1007/BF00589124. PMID:2215912.
10. Angleu G, Carrion D, Gimenez L, Camacho G, Ortega T. Diagnosis by echocardiography of a case of myxoma in the left ventricle. *An Esp Pediatr.* 1996;45(4):415-6.
11. Jelic J, Milicic D, Alfirevic I, Anic D, Baudoin Z, Bulat C, et al. Cardiac myxoma: diagnostic approach, surgical treatment and follow-up. A twenty years experience. *J Thorac Cardiovasc Surg.* 1996;37(6 Suppl 1):113-7.
12. Sanjurjo R, Puerta C, Lista S, Valbuena Bueno RD, Montero B, Crespo MG. Cardiac myxoma. Anatomical and immunohistochemical study of 13 cases. *Rev Esp Cardiol.* 1996;49(10):741-6.
13. Burke A, Virmani R. More on cardiac myxomas. *N Engl J Med.* 1996;335(19):1462-63. DOI:10.1056/NEJM199611073351912; PMID:8927083.
14. Gawdzinski MP, Sypula S. The long term results of treatment of heart myxomas with special attention to very rare myxoma of the right ventricle. *J Thorac Cardiovasc Surg.* 1996;37(6 Suppl 1):121-9.
15. Suvarna SK, Royds JA. The nature of the cardiac myxoma. *Int J Cardiol.* 1996;57(3):211-6. DOI:10.1016/S0167-5273(96)02827-6.