



Detection of Epithelial Cells Abnormality on Pap Smear and Correlation with Cervical Punch Biopsy in a Tertiary Level Hospital

Suman Poudel¹, Sunita Ranabhat¹, Sharmila Shahi¹, Gita Pun¹, Mlendu Tiwari¹, Pretty Shrestha¹

¹Department of Pathology, Gandaki Medical Collage Teaching Hospital, Pokhara, Nepal.

ABSTRACT

Background

Cervical cancer is the leading cause of death among female population of Nepal. In the low resource settings in a developing country like Nepal, where ancillary tests may not be available, a Papanicolaou (Pap) test is the mainstay of screening system for cervical cancer. Pap test is a cytological screening technique proposed by The Bethesda System for Reporting Cervical Cytology (TBSRC) at 1988. It is a simple, safe and non-invasive method for detection of epithelial cells abnormalities on cervical smear. The study aimed to assess the accuracy of the Pap smear test in reference to cervical biopsy.

Methods

This is a hospital based cross sectional study conducted over a period of 18 months, from January 2024 to June 2025. Study included 5543 Pap smear and 149 cervical biopsies over the period. Data were collected in Microsoft excel and subjected to SPSS to see the association of pap smear test and biopsy.

Results

In our study, the samples were received from patients aged 21 to 83 years of age. Only 1.4% of total cases studied showed epithelial cell abnormality. The study showed that Pap smear test has high sensitivity, specificity, positive predictive value and negative predictive value of 77.9%, 84%, 80.3% and 81.9% respectively with diagnostic accuracy of 81.20%.

Conclusions

This study revealed that Pap smear test is still a good screening technique to detect epithelial cell abnormality in cervical smear with high diagnostic accuracy in the developing country like Nepal.

Keywords: Pap smear; Biopsy; Epithelial cell abnormality; Nepal.

***Correspondence:** Dr. Suman Poudel, Department of Pathology, Gandaki Medical Collage Teaching Hospital, Pokhara, Nepal. Email: batigsu@gmail.com, Phone: +977-9856068418. **Article received:** 2026-01-16. **Article accepted:** 2026-04-06 **Article published:** 2026-06-30.

INTRODUCTION

Cervical cancer is one of the leading cancers among women in Nepal. The mortality due to cervical cancer is almost 11 women for every 100,000.¹ There is still 3.69% prevalence of cervical neoplasia among women in a rural region of mid-western, Nepal based on cytology report.²

A Papanicolaou (Pap) test is the mainstay of screening system for cervical cancer. It is simple, safe and non-invasive method. However, Pap test with Human Papilloma Virus (HPV) DNA virus co-testing is coming up in urban areas where there is advanced molecular diagnostics facility.^{3, 5} The Bethesda System for Reporting Cervical Cytology (TBSRC) at 1988 proposed a standard reporting terminology which aids pathologists to communicate relevant information to the gynecologists and other health care providers.⁴

The pap smear test with the cervical biopsy is considered the gold standard as the cervical biopsy aids in definitive diagnosis.⁶ The study aimed to assess the accuracy of the Pap smear test in reference to cervical biopsy.

METHODS

Study Design

A retrospective cross-sectional study was carried out over a period of 18 months

Study Area

This study was conducted in the Department of Pathology at Gandaki Medical College and Teaching Hospital, Pokhara, Nepal.

Sample size and sampling

During the study period, a total of 5,543 Pap smear examinations were performed. Among these, 149 cases had undergone both Pap smear testing and cervical biopsy and were included for cytohistopathological correlation. A continuous sampling technique was used, whereby all eligible cases during the study period were included in the analysis.

Data Collection Procedure

Clinical information was retrieved from the requisition forms submitted along with the

cytological and histopathological specimens received in the department. Cervical samples for cytological examination were collected using Liquid-Based Cytology (LBC) kits. Cervical biopsy specimens were received in 10% formalin, fixed overnight, and subsequently processed according to standard histopathological procedures. Difficult or equivocal cases were subjected to peer review to ensure diagnostic accuracy. Data were recorded using a structured proforma.

Data Analysis

The study was conducted from 1 January 2024 to 30 June 2025, after obtaining ethical approval from the Institutional Review Committee of Gandaki Medical College and Teaching Hospital (IRC Ref. No.: 92/081/082-F). As this was a retrospective record-based study, confidentiality and anonymity of patient information were maintained throughout the study. The collected data were entered and analyzed using the Statistical Package for Social Sciences (SPSS) version 21. The first dataset, comprising all Pap smear cases, was analyzed to determine the spectrum of epithelial cell abnormalities on Pap smear. The second dataset, consisting of cases that had undergone both Pap smear and cervical biopsy, was analyzed to assess the association between cytological and histopathological findings and to determine the diagnostic performance of the Pap smear test, including sensitivity, specificity, positive predictive value, and negative predictive value, using histopathological diagnosis as the reference standard.

RESULTS

A total of 5543 Pap smear samples and 149 histopathology samples were obtained from patients who visited Gynecology Department of GMC-TH during the period of 18 months. The cytology and histopathological analysis was done in the Department of Pathology after receiving the cervical biopsy sample of the same individual. The variables were analyzed in SPSS and the results are illustrated below.

Table 1: Age wise distribution according to Pap smear results (n=5543).

Age Group	NILM n (%)	ASCUS n (%)	ASC-H n (%)	LSIL n (%)	HSIL n (%)	SCC n (%)
19-20	49 (0.9)	0 (0.0)	0 (0.0)	0 (0.0)	0 (0.0)	0 (0.0)
20-29	1238 (22.7)	1 (10.0)	1 (4.3)	3 (12.5)	3 (14.3)	0 (0.0)
30-39	1765 (32.3)	5 (50.0)	2 (8.7)	8 (33.3)	0 (0.0)	0 (0.0)
40-49	1457 (26.7)	2 (20.0)	7 (30.4)	5 (20.8)	6 (28.6)	0 (0.0)
50-59	690 (12.6)	1 (10.0)	7 (30.4)	6 (25.0)	5 (23.8)	0 (0.0)
60-69	246 (4.5)	0 (0.0)	6 (26.1)	2 (8.3)	6 (28.6)	2 (100.0)
70-79	17 (0.3)	1 (10.0)	0 (0.0)	0 (0.0)	1 (4.8)	0 (0.0)
80-89	1 (0.0)	0 (0.0)	0 (0.0)	0 (0.0)	0 (0.0)	0 (0.0)

NILM- Negative for intraepithelial lesion or malignancy, ASCUS- Atypical Squamous Cell of Undetermined Significance, ASC-H- Atypical Squamous Cell- Cannot Exclude High Grade, LSIL-Low Grade Squamous

Majority of the age group involved in the study was 30-39 years (32.11%), followed by 40-49 years (26.65%). Similarly, the least age group involved was 80-89 years (0.018%). The age of the patients ranged from 21 to 83 years, with a mean age of 38.75 ± 11.05 (Mean \pm SD).

Out of 5543 cases studied, the most common spectrum of diagnosis on Pap smear was NILM accounting for 5463 cases (98.6%). The epithelial cell abnormality on Pap smear was seen only in 1.4%. ASC-H, LSIL, HSIL each accounts for 0.4% of the total cases i.e. 23, 24 and 21 cases respectively. Only 2 cases of SCC were diagnosed on Pap smear test.

Out of the epithelial cell abnormality, ASCUS (50%) was seen most commonly in the age group of 30-39 years. ASC-H was seen in the age group of 40-49 and 50-59 accounting 30.4% in each. Similarly, LSIL was seen commonly in 30-39 years (33.3%) and HSIL was seen in the age group of 40-49 and 60-69 years with 28.6% in each group. Both cases of SCC were seen in the age group of 60-69 years on Pap Smear results.

In this histopathological examination (HPE), findings revealed that benign conditions like chronic cervicitis, atrophy and polyp were common diagnosis, observed in 81 patients (54.4%) followed by CIN I in 34 (22.8%), CIN II in 20 (13.4%) patients, CIN III in 9 (6.0%) patients and SCC in 5 (3.4%).

Out of 65 cases of Chronic cervicitis on biopsy, 57(87.7%) were diagnosed as NILM on PAP

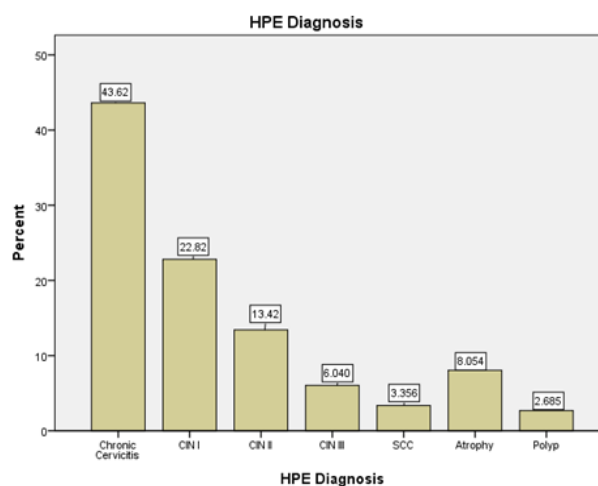


Figure 1: Distribution based on HPE Diagnosis among study patients (n=149).

diagnosis and rest 8 cases showed epithelial cell abnormality. Similarly, out of 34 cases of CIN I on biopsy, 22 showed epithelial cell abnormality on cytology examination with predominance of ASCUS accounting for 35.3%. Likewise, out of 20 cases of CIN II on biopsy, 85% showed epithelial cell abnormality with predominance of HSIL (30%). All the cases of CIN III (9) on biopsy were diagnosed as epithelial cell abnormality on PAP with predominance of ASC-H (5). All the cases of SCC (5) on biopsy showed epithelial cell abnormality on cytology as well.

In this study, 77.9% patients with a positive Pap smear had also histopathologically confirmed the same positive results, while 16% had negative histopathology despite a positive Pap result. Among those with a negative Pap smear, 22.1% were found

Table 2: Comparison of Pap smear results and Histopathological diagnosis (n=149).

PAP Diagnosis	HPE Diagnosis						
	Chronic Cervicitis	CIN I n (%)	CIN II n (%)	CIN III n (%)	SCC n (%)	Atrophy n (%)	Polyp n (%)
NILM	57 (87.7)	12 (35.3)	3 (15.0)	0 (0.0)	0 (0.0)	8 (66.7)	3 (75.0)
ASCUS	6 (9.2)	12 (35.3)	2 (10.0)	1 (11.1)	0 (0.0)	2 (16.7)	0 (0.0)
ASC-H	1 (1.5)	3 (8.8)	5 (25)	5 (55.6)	1 (20)	1 (8.3)	0 (0.0)
LSIL	1 (1.5)	5 (14.7)	4 (20.0)	0 (0.0)	0 (0.0)	0 (0.0)	1 (25.0)
HSIL	0 (0.0)	2 (5.9)	6 (30.0)	3 (33.3)	2 (40.0)	1 (8.3)	0 (0.0)
SCC	0 (0.0)	0 (0.0)	0(0.0)	0 (0.0)	2 (40.0)	0 (0.0)	0 (0.0)

to have a positive histopathology result, whereas 84% had negative histopathological findings.

This association between Pap smear and histopathology was statistically significant ($p < 0.0001$).

Table 3: Comparison of Pap smear results with Histopathology diagnosis (n=149).

PAP Smear	Histopathology		p-value
	Positive	Negative	
Positive PAP	53 (77.9%)	13 (16%)	<0.0001
Negative PAP	15 (22.1%)	68 (84%)	

In this study, the Pap smear had a sensitivity of 77.9%, specificity of 84%, positive predictive value (PPV) of 80.3%, and negative predictive value (NPV) of 81.9% with diagnostic accuracy of 81.20%.

Table 4: Indicators for the Pap smear diagnosis (n=149).

Indicator	Frequency n (%)
Sensitivity (TP/(TP+FN) * 100)	116 (77.90)
Specificity (TN/(TN+FP) * 100)	125 (84.00)
Positive predictive Value (PPV) (TP/(TP+FP) * 100)	120 (80.30)
Negative Predictive Value (NPV) (TN/(TN+FN) * 100)	122 (81.90)

DISCUSSION

The exfoliative cytology like Pap smear is a simple, safe, noninvasive and cost effective method for detection of precancerous, cancerous and benign conditions of the cervix in different age group.⁷ In our

study, the most common age group that underwent pap screening test was 30-39 years (32.11%) followed by 40-49 years (26.65%). The least number of patients that underwent pap screening falls in the age group 80-89 years (0.018%). The study done by *Belekar et al.*,⁸ also showed predominance of Pap screening test done on the age group of 41-50 years followed by 31-39 years. This might be due to increased awareness through different sources like gynecologists, news, social media is high regarding pap smear test in the above mentioned age group.⁹ Out of 5543 cases studied, the most common spectrum of diagnosis on Pap smear was NILM accounting for 5463 cases (98.6%). The epithelial cell abnormality on Pap smear was seen only in 80 cases (1.4%) with predominance of LSIL, ASC-H and HSIL each accounting 24, 23 and 21 cases respectively. Among the epithelial cell abnormality, only 23 cases were encountered below the age of 40 years and most bulk of epithelial cell abnormality (57) were noted in 40 years and above. Similar to ours, the study done by *Banik et al.*,¹⁰ also showed bulk of epithelial cell abnormality in the age of 45 or above.

Pap smears are a valuable screening tool but cervical biopsies are considered superior for definitive diagnosis. So, the suspicious cases detected or not detected by Pap smear test should undergo cervical biopsy. Only combined tests of pap smear and cervical biopsy can give definitive diagnosis.¹¹ In our study 149 cases undergo cervical biopsy and findings revealed that benign conditions like chronic cervicitis, atrophy and polyp were common diagnosis, observed in 81 patients (54.4%) followed

by CIN I in 34 (22.8%), CIN II in 20 (13.4%) patients, CIN III in 9(6.0%) patients and SCC in 5(3.4%). The study done by *Mainali et al.*,¹² also showed similar findings with more prevalence of chronic cervicitis (66.1%) followed by CIN I (10.17%), CIN II (5.08%), CIN III (5%) and SCC (4.2%) on cervical biopsy. The author performed study on 118 cases.

Out of 65 cases of chronic cervicitis on biopsy, only 8(12.3%) showed epithelial cell abnormality on PAP diagnosis and rest 57 (87.7%) were diagnosed as NILM on PAP. Similarly, out of 34 cases of CIN I on biopsy, 22 also showed epithelial cell abnormality on cytology examination with predominance of ASCUS accounting for 35.3%. Likewise, out of 20 cases of CIN II on biopsy, 85% showed epithelial cell abnormality with predominance of HSIL (30%). All the cases of CIN III (9) on biopsy were diagnosed as epithelial cell abnormality on PAP with predominance of ASC-H (5). All the cases of SCC (5) on biopsy showed epithelial cell abnormality on cytology as well. However, out of 12 atrophic cases on biopsy, 8 showed NILM on PAP and 1 case of LSIL diagnosed on PAP test was revealed to be polyp on biopsy.

The present study shows strong association between PAP and HPE diagnosis with statistical significance of p value <0.0001. Similar to ours, the studies done by *Khairwa*¹³, *Dhakal et al.*,¹⁴ also showed significant correlation between the cervical Pap smears and HPE diagnosis.

In this study, the Pap smear had a sensitivity of 77.9%, specificity of 84%, positive predictive value (PPV) of 80.3%, and negative predictive value (NPV) of 81.9% with diagnostic accuracy of 81.20%. There is some similarities to the study done by *Patel et al.*,¹⁵ with the sensitivity and specificity for detecting high-grade lesions were 88.2% and 76.4%, respectively. The positive predictive value was 84.3% and the negative predictive value was 80.5%. In contrast to ours, the study done by *Tiwari et al.*,¹⁶ showed a sensitivity of 25.92%, specificity of 94.59%, PPV of 77.77%, NPV of 63.63%, and a diagnostic accuracy of 65.62% only. This might be

due variation in sample size and techniques of pap smear in two institutes.

Limitations

Since this is a hospital-based study, sample may not represent the general population or asymptomatic ladies. All the epithelial cell abnormality on the pap smear test may not undergo biopsy.

Conclusions

The Pap Smear is the non-invasive, safe and cost-effective method to diagnose the epithelial cell abnormalities in cervical smears. It has high diagnostic accuracy in detecting the intraepithelial neoplasms and cervical cancer. However, it is always mandatory to do cervical biopsy for the confirmation of diagnosis and better management of the patient.

Acknowledgements

The authors express sincere thanks to Head and faculties of Department of Community Medicine, all the residents and faculties of Department of Pathology GMC-TH for their support in data collection, statistical analysis and guidance.

Ethics approval: Ethical approval was obtained from the Institutional Review Committee of Gandaki Medical College and Teaching Hospital (Ref. No.: 92/081/082-F). As this was a retrospective record-based study, confidentiality and anonymity of patient information were maintained throughout the study.

Conflict of interest: The author declares no conflict of interest.

Funding: No funding was received from any agency for conducting this study.

Availability of data and materials: All data analysed during this study will be made available upon reasonable request from the corresponding author.

Author contributions

Conceptualisation: Suman Poudel

Data Curation: Suman Poudel, Sunita Ranabhat, Pretty Shrestha, Gita Pun, Sharmila Shahi, Mlendu Tiwari

Formal analysis: Suman Poudel

Investigation: Suman Poudel, Pretty Shrestha

Methodology: Suman Poudel

Supervision: Suman Poudel

Writing -original draft: Suman Poudel

Writing-review & editing: Sunita Ranabhat, Gita Pun, Pretty Shrestha

REFERENCES

1. Narasimhamurthy M, Kafle SU. Cervical cancer in Nepal: Current screening strategies and challenges. *Front Public Health*. 2022 Nov 17;10:980899. [DOI]
2. Thapa N, Shrestha G, Maharjan M, Lindell D, Maskey N, Shah R, Ge C, Cai H. Burden of cervical neoplasia in mid-western rural Nepal: a population-based study. *J Gynecol Oncol*. 2018 Sep;29(5):e64. [DOI]
3. Banik U, Bhattacharjee P, Ahamad SU, Rahman Z. Pattern of epithelial cell abnormality in Pap smear: A clinicopathological and demographic correlation. *Cytojournal*. 2011;8:8. [DOI]
4. Priyadharisini, J., Bharathi, U., & Pari, P. (2022). Cytomorphological spectrum of cervical Pap smear reports using the 2014 Bethesda system for reporting cervical cytology: A two year study in a tertiary care hospital at puducherry, India. *International Journal of Health Sciences*, 6(S3), 5482-5490. [DOI]
5. Baral, A., Goyal, B., & Pun, C. B. (2025). Association of Epithelial Cell Abnormality in Pap Smear Cytology with Histopathology. *Journal of College of Medical Sciences-Nepal*, 21(1), 17-22. [DOI]
6. P R, K J, N A. Spectrum of Epithelial Cell Abnormality (ECA) and Cyto-Histopathological Correlation: A Hospital Based Prospective Study. *J Chem Health Risks*. 2024 Jul;14(4):824-830. [DOI]
7. Sinha, A., Kafle, S. U., Singh, M., & Kafle, N. (2021). Variation of Cervical Cytology by Pap Smear and its Correlation with Cervical Biopsy in Patients Attending Birat Medical College Teaching Hospital, Morang, Nepal. *Birat Journal of Health Sciences*, 6(3), 1615-1620. [DOI]
8. Belekar SV, Kamal M, Warke AS. Cervical Cytology and Histology Correlation as an Analytic Quality Assurance Exercise: Experience from an Accredited Cytology Laboratory. *J Cytol*. 2023 Oct-Dec;40(4):205-210. [DOI]
9. Annab A, Lataifeh L, Lataifeh I, Al-Rabadi D, Alkouri O, Khader YS. Factors associated with awareness of and undergoing Pap smear tests among Jordanian women. *Narra J*. 2024 Dec;4(3):e1018. [DOI]
10. Banik U, Bhattacharjee P, Ahamad SU, Rahman Z. Pattern of epithelial cell abnormality in Pap smear: A clinicopathological and demographic correlation. *Cytojournal*. 2011;8:8. [DOI]
11. Das S, Mondal SC, Shekhar T, Bhattacharya S. A comparative study of Pap smear and colposcopy with cervical biopsy in evaluation of unhealthy cervix. *New Indian J OBGYN*. 2023 Aug 16. [Link]
12. Mainali, N., Homagai, N., Nepal, N., & Choudhary, P. (2018). A correlation study of cervical cytology on Pap smear with cervical biopsy in a tertiary hospital of Eastern Nepal. *Journal of Pathology of Nepal*, 8(2), 1389-1392. [DOI]
13. Khairwa A. Cytohistopathological Correlation of 884 Cervical Pap Smears as Bethesda System 2014: A Hospital-Based Study. *OBM Genetics* 2022; 6(4): 172; [DOI]
14. Dhakal R, Makaju R, Sharma S, Bhandari S, Shrestha S, Bastakoti R. Correlation of Cervical Pap Smear with Biopsy in the Lesion of Cervix. *Kathmandu Univ Med J (KUMJ)*. 2016 Jul-Sept.;14(55):254-257. [Link]
15. Patel DD, Babaria M, Khandelwal PB. Correlation between Pap smear Findings and Histopathological Diagnosis in Abnormal Cervical Cytology Cases. *Eur J Cardiovasc Med*. 2025 Jun;15(6):572-575. [DOI]
16. Tiwari A, Khanal A, Sapkota P, Karki A. Correlation of Cervical Pap Smear with Cervical Biopsy in Lesions of Cervix. *J Inst Med Nepal*. 2024 Dec;46(3):11-15. [DOI]

Citation: Poudel S, Ranabhat S, Pun G, Shahi S, Tiwari M, Shrestha P. Detection of Epithelial Cells Abnormality on Pap Smear and Correlation with Cervical Punch Biopsy in a Tertiary Level Hospital. *J Coll Med Sci-Nepal*. 2026 Jun. 30;22(2):181-6.