

ORIGINAL RESEARCH ARTICLE

FIBULARIS TERTIUS MUSCLE AMONG PRE-CLINICAL STUDENTS OF A MEDICAL COLLEGE: A DESCRIPTIVE CROSS-SECTIONAL STUDY

Ruku Pandit^{1*}, Hari Prasad Upadhyay², Nitasha Sharma³

¹Department of Anatomy, College of Medical Sciences and Teaching Hospital, Bharatpur, Chitwan, Nepal

²Department of Statistics, Birendra Multiple Campus, Bharatpur, Chitwan, Nepal

³Department of Anatomy, Universal College of Medical Sciences and Teaching Hospital, Bhairahawa, Rupandehi, Nepal

Received: 27 Sep, 2021

Accepted: 7 Dec, 2021

Published: 25 Dec, 2021

Key words: Dorsiflexor; Fibularis tertius muscle; Prevalence.

***Correspondence to:** Ruku Pandit, Department of Anatomy, College of Medical Sciences and Teaching Hospital, Bharatpur, Chitwan, Nepal,
Email: ruukuu252@yahoo.com

DOI: <https://doi.org/10.54530/jcmc.537>

Citation

Pandit R, Upadhyay HP, Sharma N. Fibularis tertius muscle among first and second year medical and dental students of a medical college: a descriptive cross-sectional study. Journal of Chitwan Medical College. 2021;11(38):116-9.



Peer Reviewed

ABSTRACT

Background: The fibularis tertius muscle (FTM) is a variant muscle of the crural compartment of the leg that is thought to have evolved in human as a result of the development of the bipedal gait. The Fibularis tertius muscle, as an ankle dorsiflexor and foot evolver, plays an important physiological role in effective terrestrial locomotion related to midfoot biomechanical stabilization. The objective of this study is to determine the occurrence of the fibularis tertius muscle using a surface anatomical examination of the foot in medical and dental students of a medical college.

Methods: This was a descriptive cross-sectional study comprising 294 pre-clinical medical and dental students of College of Medical Sciences, Chitwan, Nepal. In each student, the fibularis tertius muscle was palpated on both lower limbs for their presence or absence. The data was collected in terms of age and gender and was analyzed using the Statistical Package for Social Science version 20.

Results: The prevalence of fibularis tertius muscle was 50.68%, with females accounting for 23.13% and males accounting for 27.55%. Fibularis tertius muscle was more common bilaterally (37.07%) than unilaterally (13.61%). Among unilateral fibularis tertius muscle, 24 (8.16%) were found only on the right foot and 16 (5.44%) on the left foot only. The bilateral prevalence of the fibularis tertius muscle was 17.01% in females and 20.07% in males, while its unilateral prevalence in females and males was 6.12% and 7.48%, respectively.

Conclusions: The involvement of the fibularis tertius muscle in affecting midfoot stabilization and its potential role in delaying the healing process of John's fracture cannot be ignored. Hence, understanding the theory behind foot biomechanics requires awareness of the existence of the fibularis tertius muscle.

INTRODUCTION

It is debatable whether the fibularis tertius muscles (FTM), the muscle of the crural compartment of the leg is a separate entity or not, but Colombio and Fallopio claimed that it is a part of or 5th digit of the extensor digitorum muscle that is inserted on the fifth toe.¹

The FTM is an ankle dorsiflexor and foot evolver^{2,3} and plays a significant part in efficient terrestrial locomotion linked to biomechanical roles in midfoot stabilization.^{4,5} FTM is considered a secondary gait muscle; hence, there hasn't been much research into its sole role in human gait. However, FTM has recently acquired therapeutic interest as a result of the advent of ankle arthroscopy. Its tendon has also been used to treat ligamentous ankle injuries,⁶ correct pes cavus⁷ and repair ruptured tibialis anterior tendon.⁸ Stress fractures of the base of the 5th metatarsal bone have been traced to the FTM insertion site in a few cases.⁹⁻¹¹ Furthermore, FTM contraction may be a key factor in the delayed healing of a fracture in the 5th metatarsal bone's shaft.

Despite the clinical importance of FTM, its incidence in the Nepalese population has not been studied. Hence, this study is undertaken with an aim of ascertaining the prevalence of FTM and its relationship to gender using a surface anatomical examination of the foot in students of medical college.

METHODS

The cross-sectional observational study was conducted in the Department of Anatomy of College of Medical Sciences, Bharatpur, Chitwan, Nepal. After obtaining ethical clearance from Institutional Review Committee (Ref. No- COMSTH-IRC/2021-59), the data was collected from preclinical medical and dental students from February to April 2021. The students with the age between 17 to 21 years were included in this study, while the students with the history of injury, fracture or congenital anomalies of foot were excluded. Sample size was calculated as below:¹²

$$n = Z^2 \times p \times (1-p) / e^2$$
$$= (1.96)^2 \times (0.50) \times (1-0.50) / (0.04)^2$$
$$= 601$$

The sample size was adjusted for finite population by using the formula,

$$n_o = (nN) / (N + (n-1))$$

$$= (601 \times 300) / (300 + (601-1))$$

$$= 201$$

Where,

n= minimum required sample size for infinite population

Z= 1.96 at 95% Confidence Interval (CI)

p= past prevalence taken as 50% for maximum sample size

e= margin of error, 4%

n_o= adjusted sample size for finite population

N= total number of Preclinical medical and dental students (300)

Taking a 10% non-response rate, the optimal sample size was 221. However, 294 students were enrolled in the study. After taking verbal and written consent data was collected from the students by using non probability (convenient) sampling technique. The gender and the age of the students were noted.

In each student, the FTM was palpated on both lower limbs for their presence or absence. Palpation of FT was carried out based on the following criteria:^{13,14}

Criteria 1: The FT tendon was palpated without any muscle strain on the way to the fifth metatarsal. We labeled any tendon that met these conditions as F1 (Figure 1). If no tendon was palpated, we proceeded to the second criterion.

Criteria 2: The subjects' feet were asked to dorsiflex and evert. If the FT tendon was defined using the same criterion as criteria 1, we designated it as F2 (Figure 2). We went on to third criterion if nothing was noticed here.

Criteria 3: The same procedure as Criteria 2 was followed, but manual resistance was applied to the lateral side of the foot at the fifth metatarsals; if the tendon was visualized or palpated, it was designated as F3 (Figure 3).

During the procedures,

Position of student: The student sat with their knees flexed to about 110°

Position of evaluator: The evaluator kneels on the floor in front of the patient's limb, which was fixed at the ankle joint and palpates the FTM insertion.

The collected data was entered and analyzed by using Statistical Package for Social Science version (SPSS) 20. Then data was analyzed using descriptive statistical tools. For the continuous variable mean and standard deviation was calculated, while categorical variables were expressed in term of frequency and percentage.

Table 1: Distribution of FTM on the basis of gender and laterality

Gender	Number of cases	Cases with FTM	Cases without FTM	Unilateral FTM	Bilateral FTM
Male	150	81 (27.55%)	69 (23.47%)	22 (7.48%) (right- 13 (4.42%); left- 9 (3.06%))	59 (20.07%)
Female	144	68 (23.13%)	76 (25.85%)	18 (6.12%) (right- 11 (3.74%); left-7 (2.38%))	50 (17.01%)
Total	294	149 (50.68%)	145 (49.32%)	40 (13.61%) (right-24 (8.16%); left-16 (5.44%))	109 (37.05%)

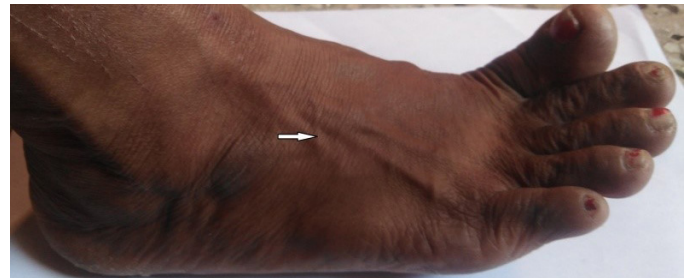


Figure 1: FTM is observed in F1

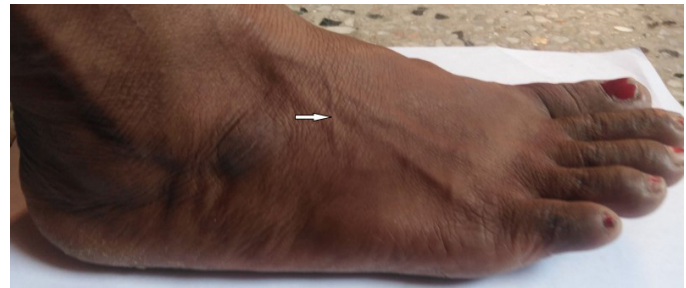


Figure 2: FTM is observed in F2

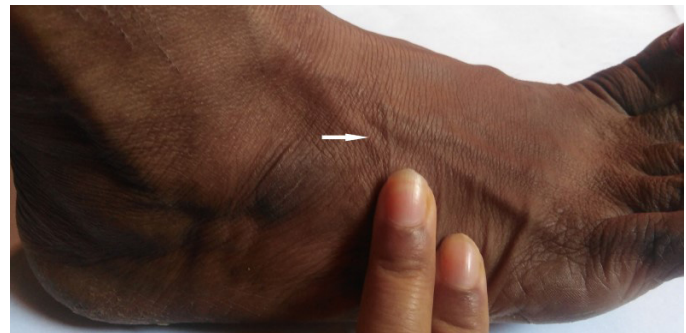


Figure 3: FTM is observed in F3

RESULTS

Of the total 294 students from first and second years of MBBS and BDS, 144 were females (48.98%) and 150 were males (51.02%). The mean age of overall students was 19.52±1.191 years. FTM was found in 149 students, resulting in a prevalence of 50.68%, with females accounting for 23.13 % and males accounting for 27.55 %. FTM was observed bilaterally in 37.07% and unilaterally in 13.61%. Among unilateral FTM, in 8.16% of the students it was present on the right side and in 5.44% on the left side. The bilateral prevalence of FTM was 17.01 % in females and 20.07 % in males, while the unilateral prevalence of FTM was 6.12% in females and 7.48% in males (Table 1).

FTM were palpated by applying manual resistance to the lateral border of the foot which was dorsiflexed and everted at the fifth metatarsal (F3) in 176 feet. In 79 feet, FTM was identified by simply asking them to dorsiflex and evert their foot (F2) while, in three feet, the tendon was visualized on its way to the fifth metatarsal without any muscular tension (F1) (Table 2).

Table 2: Gender wise distribution of FTM based on palpation criteria on right and left feet

Foot	Sex	F1	F2	F3
Right	Male	1	20	51
	Female	0	15	46
Left	Male	1	25	42
	Female	1	19	37
Total		3	79	176

DISCUSSION

The prevalence of FTM is yet to be determined in the majority of the world's population. In surface anatomical studies, the frequency of FTM varies from 49-82 %^{10,15,16}, while in cadaveric studies the incidence of FTM is even higher (83-100%).^{2,17,18} Studies have showed surface palpation of the FTM is more precise and effective than MRI tests.¹⁰

Ramirez et al. used surface analysis to assess the prevalence of FTM in 168 students and discovered that 49.11% of them have FTM,¹⁶ which is close to the result of our research (50.68%). On contrary, Witvrouw et al. noted that 81.5 % of cases had FTM, which is significantly higher than the finding of current study.¹⁰ Ramirez et al. stated that this discrepancy may be due to the subjects in Witvrouw et al.'s sample being young energetic athletes (with increased muscle growth due to strenuous strenuous physical exercise), while Ramirez et al.'s sample consisted of individuals with less muscle growth who did not unduly increase their physical activity.^{10,16} Palomo-López et al., on the other hand, reported that participants age and physical activity were not a deciding factors in the identification of the FTM since palpation-based FTM identification is very accurate even in obese persons.³

In the current study, 37.07% of the 294 students studied had bilateral FTM, while 13.61% had unilateral FTM, with no gender differences. In a study performed in 195 medical students at Saphthagiri Institute of Medical Sciences and Research Centre in Bengaluru, Karnataka State, India, bilateral FTM (41%) was found to be more frequent than unilateral FTM (22.05%) as in our study.¹⁹ Similar findings were observed in the Nigerian population; bilateral FTM- 52%, unilateral FTM- 21%.¹⁵ Amongst unilateral FTM, occurrence on the right foot (8.16%) was higher than that on the left foot (5.44%) in the present study. Similar findings were observed in previous study in which 15% were present on the right and 6% on the left foot.²⁰ Conversely, the prevalence of FTM on the left foot (11.79%) was slightly higher than on the right foot (10.25%) in a study by Potu et al.¹⁹

The occurrence of FTM in our study was slightly higher in males than in females on both the right and left foot in overall sample. The findings are consistent with those of previous studies conducted in Belgian,¹⁰ Chilean¹⁶ and Indian¹⁹ populations respectively. On the other hand, females showed slightly higher prevalence of FTM than male in Bahraini and Tunisian populations.²⁰

Manual resistance to the lateral boundary of the dorsiflexed and everted foot at the fifth metatarsal (F3 criteria) defined the majority of the FTM (176 feet) in our study. FTM was palpated in 79 feet by telling them to dorsiflex and evert their foot (F2 criteria), while the FT tendon was visualized on its way to the fifth metatarsal in three feet without any muscular tension (F1 criteria). Similarly, Potu et al. identified most of the cases (172) by F3 criteria followed by F2 in 31 cases. F1 criteria, on the other hand, failed to identify any of the cases.¹⁹

Clinical studies on the use of vascularised muscle, such as the FTM flap, to treat osteomyelitis by filling soft tissue gaps in the lower limb have been reported, which significantly improves the flow of sufficient oxygen, nutrients, and immune cells to the healing tissue by filling a dead space.²¹ The FTM is an auxiliary muscle for eversion and dorsiflexion of the foot, according to Witvrouw et al, so its absence does not significantly affect the force of eversion and dorsiflexion. Clinicians however, should regard its absence in young or elderly patients as a possible etiologic explanation for a number of talocrural zone stabilization problems.¹⁰

Understanding the surface evaluation of FTM may indubitably help orthopaedic surgeons consider arthroscopic treatment or rehabilitation of lateral ankle instability, thereby minimizing the risk of injury to FTM that may be entrapped the beneath suture during the procedure.^{22,23}

This research was carried out only in single center among preclinical medical and dental students so the finding of this research cannot be generalized to the whole population (students) of Nepal. As the study sample consisted of lower limbs with no apparent pathologies, this research would not illuminate the association between FTM and foot deformities.

CONCLUSION

In the present study, we observed that the FTM was absent unilaterally or bilaterally in some students. As the agenesis of FTM has its major effect on the biomechanics of the foot, this research may be of interest to anatomists, physiotherapists, and orthopedic surgeons. Furthermore, it is essential to conduct detailed studies of this muscle in various populations of normal and abnormal feet and gaits to determine its effect on foot shape and biomechanics.

CONFLICT OF INTEREST: None

FINANCIAL DISCLOSURE: None

REFERENCES:

1. Cowper W. *Myotomia Reformatata: Or an Anatomical Treatise on the Muscles of the Human Body. To which is Prefixed an Introduction Concerning Muscular Motion*: R. Knaplock; 1767.
2. Rourke K, Dafydd H, Parkin I. Fibularis tertius: revisiting the anatomy. *Clinical Anatomy*. 2007;20(8):946-9. [\[DOI\]](#)
3. Palomo-López P, Losa-Iglesias ME, Calvo-Lobo C, Rodríguez-Sanz D, Navarro-Flores E, Becerro-de-Bengoa-Vallejo R, et al. Fibularis tertius muscle in women & men: A surface anatomy cross-sectional study across countries. *PLoS one*. 2019;14(4):e0215118. [\[DOI\]](#)
4. Eliot DJ, Jungers WL. Fifth metatarsal morphology does not predict presence or absence of fibularis tertius muscle in hominids. *Journal of human evolution*. 2000;38(2):333-42. [\[DOI\]](#)
5. Jungers WL, Meldrum DJ, Stern Jr JT. The functional and evolutionary significance of the human peroneus tertius muscle. *Journal of human evolution*. 1993;25(5):377-86. [\[DOI\]](#)
6. Sammarco GJ, Henning C. Peroneus tertius muscle as a cause of snapping and ankle pain: a case report. *The American journal of sports medicine*. 2007;35(8):1377-9. [\[DOI\]](#)
7. Brody P, Grumbine N. Peroneus tertius reconstruction for flexible claw-toes associated with cavus deformity: a preliminary report. *The Journal of foot surgery*. 1984;23(5):357-61. [\[LINK\]](#)
8. Gaulrapp H, Heimkes B. Peroneus tertius tendon repair following rupture of the anterior tibial tendon (a case study). *Unfallchirurg*. 1997;100(12):979-83. [\[DOI\]](#)
9. Das S, Haji Suhaimi F, Abd Latiff A, Pa Pa Hlaing K, Abd Ghafar N, Othman F. Absence of the peroneus tertius muscle: cadaveric study with clinical considerations. *Romanian Journal of Morphology and Embryology*. 2009;50(3):509-11. [\[LINK\]](#)
10. Witvrouw E, Vanden Borre K, Willems TM, Huysmans J, Broos E, De Clercq D. The significance of peroneus tertius muscle in ankle injuries: a prospective study. *The American journal of sports medicine*. 2006;34(7):1159-63. [\[DOI\]](#)
11. Theodorou DJ, Theodorou SJ, Kakitsubata Y, Botte MJ, Resnick D. Fractures of proximal portion of fifth metatarsal bone: anatomic and imaging evidence of a pathogenesis of avulsion of the plantar aponeurosis and the short peroneal muscle tendon. *Radiology*. 2003;226(3):857-65. [\[DOI\]](#)
12. Das S, Mitra K, Mandal M. Sample size calculation: Basic principles. *Indian Journal of Anaesthesia*. 2016;60(9):652. [\[DOI\]](#)
13. Tixa S. *Atlas de anatomía palpatoria*. 2nd ed. Barcelona: Ed. Masson; 2006.
14. Kendall FP, McCreary EK, Provance PG, Abeloff DK, Andrews P, Krause CC, et al. *Músculos: pruebas, funciones y dolor postural*: Marban; 2000.
15. Ashaolu JO, Olorunyomi OI, Opabunmi OA, Ukwenya VO, Thomas MA. Surface anatomy and prevalence of fibularis tertius muscle in a south-western Nigerian population. *Forensic Medicine and Anatomy Research*. 2013. [\[DOI\]](#)
16. Ramirez D, Gajardo C, Caballero P, Zavando D, Cantín M, Suazo G. Clinical evaluation of fibularis tertius muscle prevalence. *International Journal of Morphology*. 2010;28(3):759-64. [\[LINK\]](#)
17. Joshi S, Joshi S, Athavale S. Morphology of peroneus tertius muscle. *Clinical Anatomy: The Official Journal of the American Association of Clinical Anatomists and the British Association of Clinical Anatomists*. 2006;19(7):611-4. [\[DOI\]](#)
18. Marin L, Barbosa FR, de Andrade O, da Costa Bazanelli A, Ruiz CR, Pereira LA, et al. Estudo anatômico do músculo fibular terceiro em humanos. *Arquivos Médicos do ABC*. 2006;31(1). [\[LINK\]](#)
19. Potu BK, Kumar V, Annam S, Salem AH, Abu-Hijleh M. Prevalence of Fibularis Tertius Muscle in Southeastern Indian Population: a Surface Anatomical Study. *European Journal of General Medicine*. 2016;13(3):27-30. [\[DOI\]](#)
20. Salem AH, Kader GA, Almallah AA, Hussein HH, Badie AA, Behbehani N, et al. Variations of peroneus tertius muscle in five Arab populations: A clinical study. *Translational Research in Anatomy*. 2018;13:1-6. [\[DOI\]](#)
21. Arnold PG, Yugueros P, Hanssen AD. Muscle flaps in osteomyelitis of the lower extremity: a 20-year account. *Plastic and reconstructive surgery*. 1999;104(1):107-10. [\[DOI\]](#)
22. Santos FF, Santos NR. Arthroscopic treatment of lateral ankle instability. Is there a safe zone? An anatomic study. *Foot and Ankle Surgery*. 2020;26(1):61-5. [\[DOI\]](#)
23. Sanz DR, Lobo CC, López DL, Morales CR, Marín CS, Corbalán IS. Interrater reliability in the clinical evaluation of myofascial trigger points in three ankle muscles. *Journal of manipulative and physiological therapeutics*. 2016;39(9):623-34. [\[DOI\]](#)