

ORIGINAL RESEARCH ARTICLE

3D-MDCT STUDY OF STYLOID PROCESS OF TEMPORAL BONE AMONG PATIENTS ATTENDING CHITWAN MEDICAL COLLEGE TEACHING HOSPITAL

Gulam Anwer Khan^{1*}, Sushma Khatiwada¹, Shuvechha Shakya¹, Deepak Adhikari², Ajeevan Gautam¹

¹Department of Anatomy, Chitwan Medical College, CMC, Bharatpur, Nepal

²Department of Radiology, Chitwan Medical College, CMC, Bharatpur, Nepal

Received: 23 Nov, 2021

Accepted: 11 Dec, 2021

Published: 25 Dec, 2021

Key words: Computed Tomography; Eagles Syndrome; Ossification; Temporal Bone.

***Correspondence to:** Gulam Anwer Khan, Department of Anatomy, Chitwan Medical College, Bharatpur-13, Chitwan, Nepal.

Email: aanwer227@gmail.com

DOI: <https://doi.org/10.54530/jcmc.577>

Citation

Khan GA, Khatiwada S, Shakya S, Adhikari D, Gautam A. 3D-MDCT study of styloid process of temporal bone among patients attending Chitwan Medical College Teaching Hospital. Journal of Chitwan Medical College. 2021;11(38):52-5.



ABSTRACT

Background: The styloid process of the temporal bone is clinically significant because differences in length and angulations are linked to the symptoms of stylalgia (Eagle's syndrome), and surgical removal of the process can help patients with neck and cervico-facial pain. This study aimed to evaluate the length, angulation and distance between bases and tips of the styloid process.

Methods: A Hospital based cross-sectional study using observation method was carried out in Department of radiology Chitwan Medical College Teaching Hospital, Nepal from 17th September 2021 to 16th November 2021. A total of 107 patients were enrolled as a sample for the study. The length, distance and angulation were measured during routine 3D Multi-detector row computed tomography (MDCT). Obtained data was evaluated by using descriptive statistics with Statistical Package for the social Science (IBM SPSS) 20.0.

Results: Among 107 patients undergoing Computed Tomography (CT) scan, majority i.e 71% have medial angulation of styloid process, 16.80% participants have elongated styloid process on left side and 17.80 % participants have elongated styloid process on right side. Mann Whitney U Test showed that tip to tip and base to base distance are statistically significant between male and female.

Conclusions: The styloid process is in close proximity to a number of essential anatomical structures. Because of differences in the shape of the styloid process, these structures may be compressed or inflamed. Even though the existence of an elongated styloid process and its angulation is uncommon, it emphasizes the need of examining the styloid process on a regular basis in clinical practice.

INTRODUCTION

The styloid process of a temporal bone is a slender, pointed, bony projection from the inferior aspect of the petrous part of a temporal bone. The apex of the styloid process is located between internal and external carotid arteries, just lateral to the tonsillar fossa.¹ Its relationships are of clinical and surgical importance because vital neurovascular structures are presents around it.² The parotid gland covers the styloid process laterally. The stylopharyngeus connects to the start of the internal jugular vein on the medial side. The facial nerve crosses its base, the external carotid artery crosses its tip, buried in the parotid.³ The usual length of this projection varies between 2 to 3 cm with an average of 2.5 cm.⁴ The styloid process develops from the second branchial arch or hyoid arch. Reichert's cartilage of this arch forms styloid process.² Individual ossification centers often fuse throughout late puberty and early adulthood, however non-fusion can occur at any time during life.^{5,6}

Eagle's syndrome is characterized by extension of the styloid process or severe calcification of the stylohyoid ligament,

resulting in pain in the neck, throat, or face, as well as dysphagia. Compression of the glossopharyngeal nerve, which loops around the styloid process, may cause pain. A crooked and elongated styloid process may also induce pain by putting pressure on the internal and external carotid arteries.⁷

The temporal styloid process is an important anatomical landmark for surgeons, radiologists while performing skull surgery. The close proximity of the styloid process to many of the vital neurovascular structures makes it clinically significant. On the temporal bone, the styloid process is a highly varied structure. The knowledge of morphology of the styloid process as well as their anatomical variations not only has great clinical significance but is also of academic interest.^{1,2,3} The present study aims to measure the length of styloid process in the Nepalese population. The styloid process shows variety of morphologies as there are less studies in our context.

METHODS

This was a hospital based cross-sectional study conducted from 17th September 2021 to 16th November 2021 at Department

of Radiology, Chitwan Medical College Teaching Hospital, Chitwan. Ethical clearance for the study was obtained from CMC-IRC (Ref/078/079-038). The study included 107 MDCT undergoing patients at Radiology Department of the College. Among total participants 65 were male and 42 were female. A verbal consent was obtained from all the patients for participation in the study. After removing MDCT reports with fractured styloid process and processes with gross pathology, only CT scan reports with intact styloid processes were included. The length, distance and angulation were measured during routine 3-D MDCT (Siemens Somatom definition AS 128 slice MDCT Siemens GmbH, Germany with syngo.via version VB 20A MPR with 3D reconstruction) (Figure 1 and 2). Scans were obtained with collimation: 128 x 0.6 mm scan time: 5.0 s scan length: 116 mm rotation time: 1.0 s tube settings: 120 kV, 380 eff. mAs CT DIvol: 54.08 mGy DLP: 916 mGy cm eff. dose: 1.92 mSv. Multi-detector 3D images were reconstructed from each individual using multiplanar reconstruction. Data was manually validated and entered into Microsoft Excel 2007 before being exported to IBM SPSS 20.0 for further analysis. Length or distance from tip to tip, base to base and angulation of styloid process was evaluated by using descriptive statistics. The numerical values were expressed as mean±standard deviation, categorical variable as percentage.

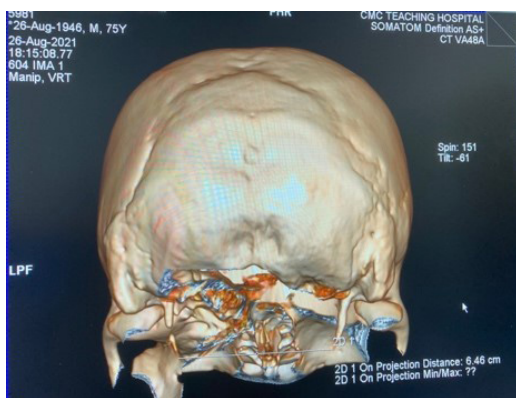


Figure 1: Distribution of Dengue cases according to Symptoms

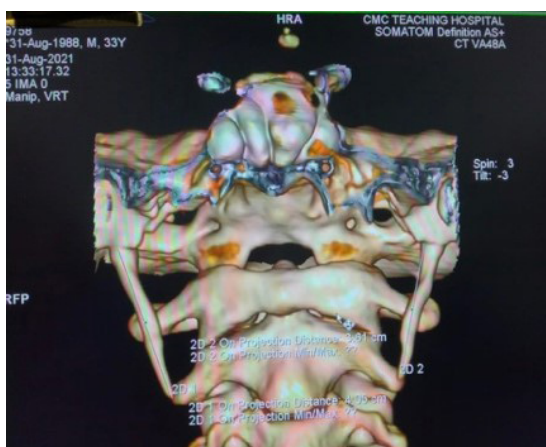

Figure 2: Distribution of Dengue cases according to Symptoms

RESULTS

Male dominance (60.74%) was discovered when the entire number of patients receiving 3D MDCT every month at Chitwan

Medical College was analyzed. We discovered that 58.80% of males were between the ages of 0 and 24, 54.20% were between the ages of 25 and 50, and 71.20% were over the age of 50. Similarly, 41.20%, 45.80% and 28.80% were female on their respective age group. The age median (IQR) was 36(26) (Figure 3).

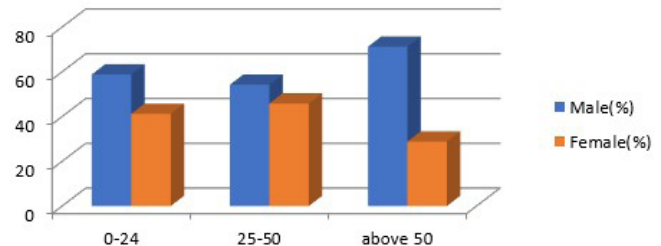


Figure 3: Age-sex distribution among patients undergoing CT scan attending radiology department at CMCTH (n=107)

In the investigation, we also attempted to determine the length of the styloid process. According to our findings, the left side's styloid process was (89)83.20 % normal length, whereas the right side was (88)82.20% normal length. Remaining (18)16.80% and (19)17.80% styloid process were elongated on left and right side respectively.

The styloid process of right-side median of length (IQR) was 2.49(0.78). The median length of left styloid process ± SD was 2.39 ± 0.61 (Figure 4).

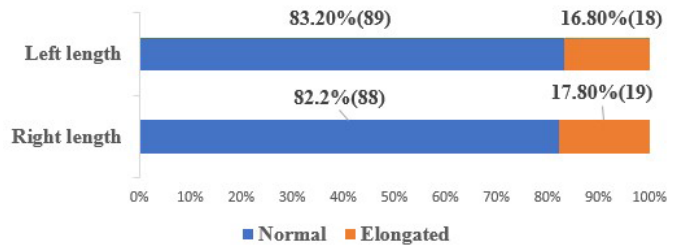


Figure 4: Length of styloid process of temporal bone among patients undergoing MDCT scan attending radiology department at CMCTH (n=107)

In the investigation, an attempt was made to see the angulation of the styloid process. The results revealed that 11.20% of the styloid process was directed vertically down, 17.80% was laterally deviated, and 71% was medially deviated. The angulation was between 53°-87.5° in transverse plane and 72°-102° in sagittal plane (Figure 5).

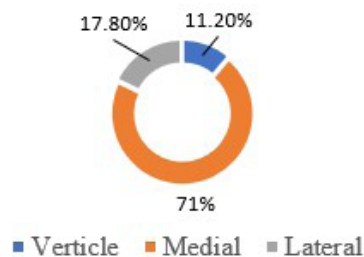


Figure 5: Angulation of styloid process of temporal bone among patients undergoing MDCT scan attending radiology department at CMCTH (n=107)

We also attempted to determine the distance between the tip and base of the right and left styloid processes in the investigation. The study found that the mean tip to tip distance was 6.30 ± 0.64 cm, and the base to base median (IQR) was 7.89 (0.78).

DISCUSSION

The goal of this research was to look into the styloid process factors that could affect the presence of styloid process disorders. 3D-MDCT has previously been shown to be a useful tool for assessing styloid process length, angulation, and other morphological properties.^{8,9}

A styloid process with a length of 2.5 cm is considered normal, whereas one with a length of more than 3 cm is referred to as elongated.^{10, 11, 12} Our study also reported that in most of the individual the length of it is within the normal range.

Eagle et al¹⁰ in their study reported the normal length of the styloid process as 2.5 cm. The findings of their study is in accordance to the findings of ours. Our study reported the length of the styloid in majority of the study sample in between 2.39 to 2.49. This similarity might be because of the ossification process of the compact bones.

BASEKIM et al⁸ looked at 269 styloid processes from 138 patients who had a spiral CT scan. The styloid process lengths in the study ranged from 1.58 to 5.48 cm. The findings of the study is in accordance to ours. We reported the normal range between 2.39-2.49 cm with longest being 6.2 cm. This similarity might be because of the similarity in ossification process of the compact bone and this may vary according to the age and sex.

According to Ayyildiz VA et al¹⁴ in their work Morphometric examination of the styloid process by 3D CT in persons with Eagle syndrome, the majority of the styloid process was deviated medially in males and vertically orientated in females. They contradict our findings, which stated that the majority of styloid processes were deviated medially (71%) followed by lateral (17.8%) and vertical (11.2%). This contradiction might be because of different study group and region.

Vadgaonkar R et al¹⁵ determined the mean length of the styloid process to be 17.89 ± 0.3 mm for the right side and 18.25 ± 0.6 mm for the left side in their study on morphological analysis of the styloid process in India. Our findings contradict theirs. The styloid process of the right side median (IQR) was found

to be 2.49 in our investigation (0.78). The left styloid process has a median SD of 2.39 ± 0.61 mm. This might be because of different age group as styloid process increases with age⁴. In a study of 848 patients, KAUFMAN et al.¹⁷ found elongated styloid process to be 28%. The findings are similar to us. Our findings shows the elongated styloid process in 16.8% in left side and 17.8% in right side of the total sample. This similarity suggests ossification process as a major factor.

The distance between the styloid process's tip and base has clinical relevance as well. Our research found that tip to tip distance was 6.30 ± 0.644 cm on average, and base to base distance was 7.89 cm on average (0.78). Our findings contradict those of Vadgaonkar R et al. The tip-to-tip distance is 60.72.4 cm, while the base-to-base distance is 68.9 ± 4.3 cm, according to the researchers. We reported a much greater distance, which could be due to the diverse age groups.⁴

Our study reported the angulations of the styloid process between 53° to 87.5° in the transversal plane, and in between 72° to 102° in the sagittal plane. These findings are similar to the result of Onbas O et al¹⁶ as 55° to 90.5° in the transversal plane, and 76° to 110° in the sagittal plane. This similarity might be because of similar age group, process of ossification.

CONCLUSION

This research contributes to our knowledge of the length and variability of the styloid process in a previously unstudied group. It also demonstrates that while classifying process lengths, the distribution of styloid process lengths must be considered. Aside from its anatomic value, doctors should be aware of SP variability when treating unusual pain in the head and neck area and medico legal issues.

ACKNOWLEDGEMENTS

We would like to thank the ethical committee of Chitwan Medical College for providing us the consent to conduct this study at this esteemed institute. We would also like to whole heartedly thank the administration and department without whom the study would not have been possible.

CONFLICT OF INTEREST: None

FINANCIAL DISCLOSURE: None

REFERENCES:

1. Grays Standing S: Skull and Mandible. In Gray's Anatomy. The Anatomical basis of clinical practice. 39th edition. Elsevier, Edinburg; 2005:470.
2. Principles of Human Anatomy - 12th Edition- G. Tortora, M. Nielsen (Wiley, 2012) BBS.pdf
3. Moore KL, Persaud TVN. The developing human clinically oriented embryology. 8ed. Philadelphia: Saunders; 2008. 522 p.
4. Sokler K, Sandev S. New classification of the styloid process length—clinical application on the biological base. Collegium antropologicum. 2001 Dec 17;25(2):627-32. [\[DOI\]](#)
5. De Paz FJ, Rueda C, Barbosa M, Garcia M, Pastor JF. Biometry and statistical analysis of the styloid process. Anatomy Rec. 2012; 295(5): 742- 7. [\[DOI\]](#)
6. Ghosh LM, Dubey SP. The syndrome of elongated styloid process. Auris Nasus Larynx. 1999;26(2):169-75. [\[DOI\]](#)
7. Gozil R, Yener N, Calguner E, Arac M, Tunc E, Bahcelioglu M. Morphological characteristics of styloid process evaluated by computerized axial tomography. Ann Anatomy. 2001;183:527-35. [\[DOI\]](#)
8. Başekim ÇÇ, Mutlu H, Güngör A, Şilit E, Pekkaşali Z, Kutlay M, et al. Evalu-

- ation of styloid process by three-dimensional computed tomography. *Eur Radiol.* 2005 Jan;15(1):134-9. [\[DOI\]](#)
9. Chung, Kyung Won. *Gross anatomy / Kyung Won Chung, Harold M. Chung.* - 7th ed. p.; cm. - (Board review series) Includes bibliographical references and index. ISBN 978-1-60547-745-9.
 10. Burulday V, Akgül MH, Bayar Muluk N, Yağdiran B, Inal M. The importance of medial-lateral styloid process angulation/coronal plane angle in symptomatic eagle syndrome. *Clin Anat* 2017;30(4):487-491. [\[DOI\]](#)
 11. Eagle WW. Elongated styloid process: symptoms and treatment. *AMA Arch Otolaryngol.* 1958;67(2):172-6. [\[DOI\]](#)
 12. Naik SM, Naik SS. Onsillo-Styloidectomy for Eagle's Syndrome: A Review of 15 Cases in KVG Medical College Sullia. *Oman Med J.* 2011; 26(2): 122-126. [\[DOI\]](#)
 13. Palesy P, Murray GM, De Boever J, Klineberg I (2000) The involvement of the styloid process in head and neck pain: a preliminary study. *J Oral Rehabil,* 27: 275-287. [\[DOI\]](#)
 14. Ayyildiz VA, Senel FA, Dursun A, Ozturk K. Morphometric examination of the styloid process by 3D-CT in patients with Eagle syndrome. *Eur Arch Otorhinolaryngol.* 2019 Dec;276(12):3453-9. [\[DOI\]](#)
 15. Vadgaonkar R, Murlimanju BV, Prabhu LV, Rai R, Pai MM, Tonse M, et al. Morphological study of styloid process of the temporal bone and its clinical implications. *Anat cell Biol.* 2015; 48(3): 195-200. [\[DOI\]](#)
 16. Onbas O, Kantarci M, Murat Karasen R, Durur I, Cinar Basekim C, Alper F, et al. Angulation, length, and morphology of the styloid process of the temporal bone analyzed by multidetector computed tomography. *Acta Radio.* 2005 Dec;46(8):881-6. [\[DOI\]](#)
 17. Kaufman SM, Elzay RP, Irish EF. Styloid process variation: radiologic and clinic study. *Arch Otolaryngol* 1970; 91: 460-3. [\[DOI\]](#)