

## CASE REPORT

### PURTSCHER'S RETINOPATHY: A CASE REPORT

Sushma Chaudhary<sup>1,\*</sup>, Sharad Gupta<sup>1</sup>, Reena Yadav<sup>1</sup>, Vinit Kumar Kamble<sup>1</sup>, Satbodh Shrestha<sup>1</sup>

<sup>1</sup>Sagarmatha Choudhary Eye Hospital, Lahan, Siraha, Nepal.

Received: 17 Jul, 2020

Accepted: 16 Aug, 2020

Published: 27 Sept, 2020

**Key words:** Purtscher's flecken; Purtscher's retinopathy; Unilateral.

**\*Correspondence to:** Sushma Chaudhary, Sagarmatha Choudhary Eye Hospital (SCEH), Lahan, Siraha, Nepal.  
Email: [sus56chaudhary@gmail.com](mailto:sus56chaudhary@gmail.com)

#### Citation

Chaudhary S, Gupta S, Yadav R, Kamble VK, Shrestha S. Purtscher's retinopathy: a case report. Journal of Chitwan Medical College. 2020;10(33):103-05.



Peer Reviewed

#### ABSTRACT

Purtscher's retinopathy is a rare haemorrhagic and vaso-occlusive vasculopathy following severe head trauma associated with sudden blindness. Here we report a case of 28 years old male presented to out-patient department with history of sudden and painless loss of vision in his right eye for two days. He gave history of head injury following bike accident. At the time of presentation his best corrected visual acuity was 1/60 in the right eye and 6/6 in the left eye. On examination, anterior segments of both eyes were normal. On fundus examination, right eye revealed retinal whitening in the peripapillary region (Purtscher's flecken), an intraretinal hemorrhage and signs of macular edema whereas left eye was unremarkable. Findings were suggestive of right eye Purtscher's retinopathy. Optical coherence tomography and fundus fluorescence angiography was done to support the diagnosis. Purtscher's retinopathy should not be neglected because it is associated with different systemic disease. Its pathophysiology remains unclear and there is no definite treatment but meticulous management is urgent to prevent from severe complications.

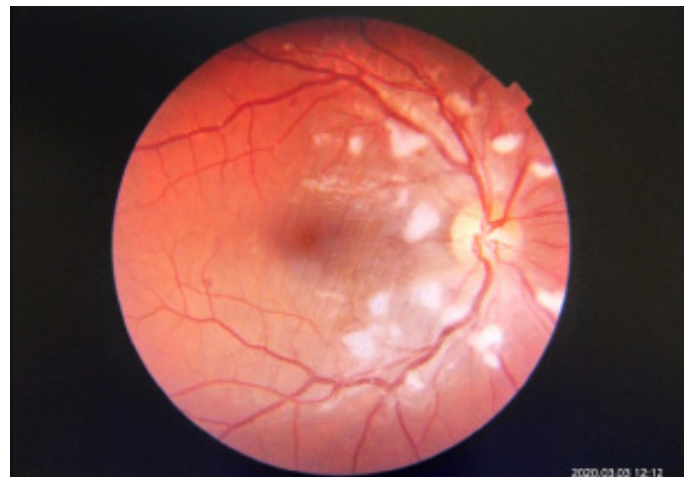#### INTRODUCTION

Purtscher's retinopathy also known as angiopathia retinae traumatica is haemorrhagic and vaso-occlusive vasculopathy which was first described as a syndrome of sudden and painless blindness associated with severe head trauma by Otmar Purtscher in 1912. Fundus examination revealed multiple areas of retinal whitening (Purtscher's flecken) with intraretinal hemorrhages, sometimes associated with macular edema.<sup>1</sup> A similar fundus picture has also been observed in nontraumatic conditions such as acute pancreatitis, fat embolism, renal failure, connective tissue disorders, childbirth and bone marrow transplant and was named as Purtscher's like retinopathy.<sup>2,3</sup> Here we report a rare case of unilateral Purtscher's retinopathy following head injury.

#### CASE REPORT

A 28 years old male came to out-patient department with chief complaints of sudden and painless loss of vision in his right eye for 2 days. He gave history of head injury following bike accident 7 days back. There was no history of loss of consciousness, direct ocular or chest trauma. He had no significant medical and surgical history. His best corrected visual acuity

was 1/60 in right eye and 6/6 in left eye. On Slit lamp biomicroscopy examination, anterior segment was normal in both eyes. Dilated fundus examination of the right eye showed retinal whitening in the peripapillary region (Purtscher flecken), an intraretinal hemorrhage (Figure 1) whereas left eye was unremarkable (Figure 2).



**Figure 1: Right Fundus: Peripapillary retinal whitening suggestive of Purtscher's flecken and few intraretinal hemorrhage**

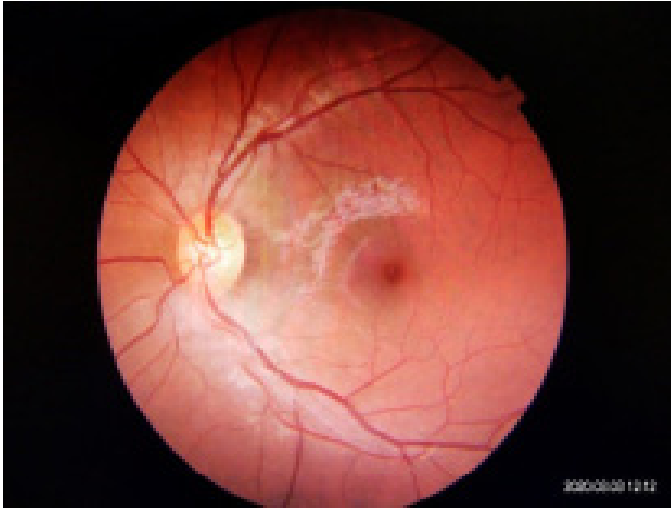

Figure 2: Normal fundus of the left eye

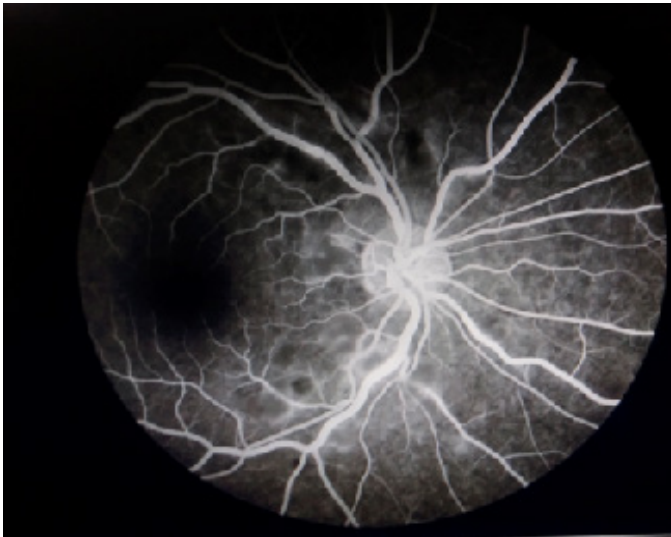


Figure 3: Fundus fluorescence angiography of right fundus showed hypo fluorescence in peripallilary region.

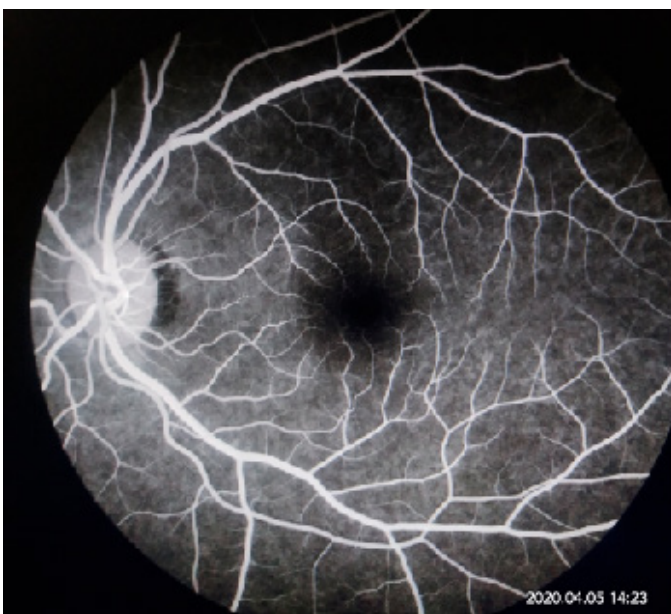

Figure 4: Normal Fundus fluorescence angiography of left fundus

Findings were suggestive of right eye Purtscher's retinopathy. Intraocular pressure of both eyes was within normal limit. Fundus fluorescence angiography of right fundus revealed hypofluorescence in the peripapillary region whereas left fundus was normal (Figure 3 and 4).

Optical coherence tomography (OCT) of the right eye showed mild subretinal fluid in posterior pole suggestive of serous retinal detachment whereas OCT of the left eye was normal (Figure 5 and 6).

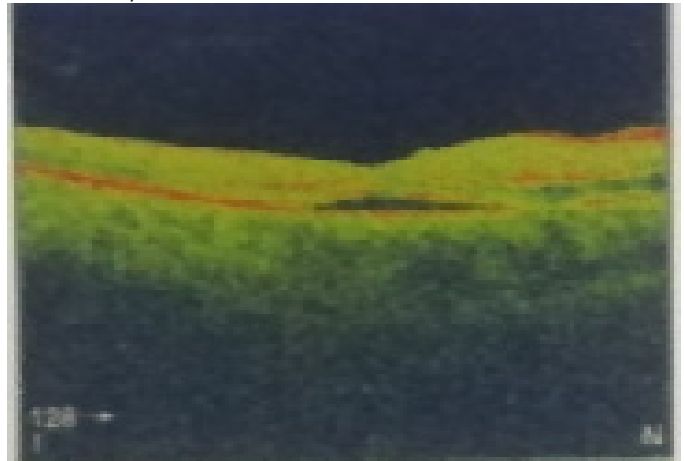


Figure 5: Optical coherence tomography of the right eye showed mild subretinal fluid in posterior pole suggestive of serous retinal detachment.

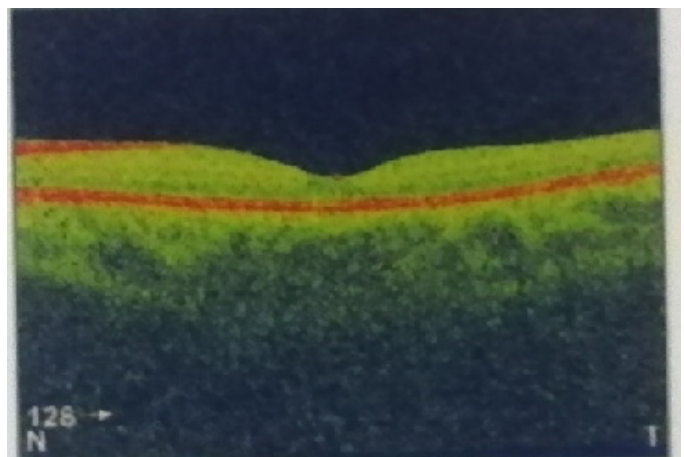


Figure 6: Normal OCT of the left eye

With the above findings patient was treated with oral corticosteroids in tapering dose and advised him to follow up after 2 weeks to see the improvement but he didn't come for follow up.

#### DISCUSSION

Purtscher's retinopathy also called as angiopathia retinae traumatica was first described by Otmar Purtscher in 1912 following head injury.<sup>1</sup> On the other hand Purtscher's like retinopathy can be associated acute pancreatitis, strenuous child birth, connective tissue disorders and retrobulbar anaesthesia<sup>3-5</sup> Previously it was said that due to sudden increase in intracra-

nial pressure secondary to head injury lead retinal changes were due to an extravasation of lymph from retinal vessels.<sup>6</sup> Other causes are angiospasm from acute rise in intracranial or intrathoracic pressure, venous vasculitides and vascular emboli caused by fatty acids, air, fibrin, platelets and leukocytes.<sup>7</sup> Leukoembolization, endothelial damage, activation of complement C5 and blockade of any small arterioles causing infarcts of capillary bed have been implicated in the pathogenesis of Purtscher retinopathy. Leukoembolization is associated with complement C5a. Complement C5a is associated with trauma, acute pancreatitis and systemic vasculitic disease and has been proposed to play a role in the development of Purtscher's retinopathy.<sup>8</sup>

Patients with Purtscher's retinopathy presents with sudden and painless loss of visual acuity in one eye. There might be bilateral fundus abnormality which includes Purtscher's flecken, cotton wool spots, retinal hemorrhage and optic disc swelling. Purtscher's flecken consists of multiple discrete areas of reti-

nal whitening in the superficial aspect of inner retina between arterioles and venules. Retinal hemorrhages are minimal and typically flame shaped but dot and blot hemorrhage may occur. Optical coherence tomography showed thickened nerve fiber layer and signs of macular edema. On fundus fluorescein angiography choroidal fluorescence is masked with retinal whitening or blood, non-perfusion of the smaller retinal arterioles or capillaries may be seen and there may be leakage from retinal vessels in areas of ischemia. There is no definite treatment for the disease but role of corticosteroids is still controversial.

## CONCLUSION

Purtscher's retinopathy should not be neglected because it is associated with different systemic disease. Its pathophysiology remains unclear and there is no definite treatment but meticulous management is urgent to prevent from severe complications.

## REFERENCES:

1. Agrawal A, McKibbin M. Purtscher's retinopathy: Epidemiology, clinical features and outcome. *Br J Ophthalmol.* 2007; 91(11):1456-9. [\[DOI\]](#)
2. Miguel AIM, Henriques F, Azevedo LFR, Loureiro AJR, Maberley DAL. Systematic review of Purtscher's and Purtscher-like retinopathies. *Eye (Lond);* 2013; 27(1):1-13. [\[DOI\]](#)
3. Carrera CR, Pierre LM, Medina FM, Pierre-Filho Pde T. Purtscher-like retinopathy associated with acute pancreatitis. *Sao Paulo Med J.* 2005; 123(6):289-91. [\[DOI\]](#)
4. Blodi BA, Johnson MW, Gass JD, Fine SL, Joffe LM. Purtscher's-like retinopathy after childbirth. *Ophthalmology* 1990; 97(12):1654-9. [\[DOI\]](#)
5. Lemagne JM, Michiels X, Van Causenbroeck S, Snyers B. Purtscher-like retinopathy after retrobulbar anesthesia. *Ophthalmol.* 1990; 97(7):859-61. [\[DOI\]](#)
6. Agrawal A, McKibbin M. Purtscher's and Purtscher like retinopathies: A review. *Surv Ophthalmol.* 2006; 51(2):129-36. [\[DOI\]](#)
7. Buckley SA, James B. Purtscher's retinopathy. *Postgrad Med J.* 1996; 72(829): 409-12. [\[DOI\]](#)
8. Henkind P. Ballotini occlusion of retinal arteries. Collateral vessels. *British Journal of Ophthalmology* 1966; 50(8):482-95. [\[DOI\]](#)