

ORIGINAL RESEARCH ARTICLE

HISTOPATHOLOGICAL EXAMINATION OF TISSUES FOLLOWING A SURGICAL UTERINE EVACUATION IN THE FIRST TRIMESTER BLEEDING: CLINICAL RELEVANCE

Bandana Khanal^{1,*}, Basant Sharma¹, Renuka Tamrakar¹, Prekshya Singh¹

¹Department of Obstetrics & Gynaecology, Chitwan Medical College, Bharatpur, Nepal

Received: 24 Aug, 2020

Accepted: 24 Sept, 2020

Published: 27 Sept, 2020

Key words: Histopathology; Miscarriage; molar pregnancy.

*Correspondence to: Bandana Khanal, Department of Obstetrics & Gynaecology, Chitwan Medical College, Bharatpur, Nepal.

Email: drbandanagaurav@gmail.com

Citation

Khanal B, Sharma B, Tamrakar R, Singh P. Histopathological examination of tissues following a surgical uterine evacuation in the first trimester bleeding: clinical relevance. Journal of Chitwan Medical College. 2020;10(33):91-4.



Peer Reviewed

ABSTRACT

Background: There is no general consensus about the role of routine HPE of the obtained tissue at the time of uterine evacuation. However, it is understood clinically that it is of utmost importance to prove the presence of intrauterine gestation and to exclude gestational trophoblastic disease in the form of partial or complete mole. This study aimed to assess the role of histopathology in cases of first trimester miscarriages and to determine clinical relevance of histopathological examination following surgical evacuation.

Methods: This was a retrospective study of collected data over 12 months (January 2018- December 2018) in an agency for reproductive health setup with predefined inclusion criteria. We included 60 consecutive patients attended with history of first trimester bleeding. Patient's record and the histopathological examination report of products of conception following uterine evacuation were observed. The data was analyzed descriptive statistics including percentage, standard deviation, mean, and range in Microsoft Excel software.

Results: Missed abortion was the most common type and constituted 55% of the studied group. The histopathological reports confirmed the pregnancy in all patients and revealed partial mole in 6(10%) patients and complete mole in 2(3.33%) patients.

Conclusions: Histopathological examination of products of conception detects under diagnosed molar pregnancies that necessitates special follow up and is a key step to do further management.

INTRODUCTION

Normal uneventful pregnancy resulting in a healthy baby and healthy mother is a blessing of the nature, unfortunately, some pregnancies are affected by various complications. The most common problems associated with bleeding in first trimester pregnancy are miscarriages, ectopic and molar pregnancies. These conditions are not clinically differentiated if conceptus tissue is not sent for histopathological examination (HPE). If the molar pregnancies are missed, this would lead to prolonged follow up and serious implications on maternal health. There is no general consensus about the role of routine HPE of the obtained tissue at the time of uterine evacuation, however, it is clinically understood that it is of utmost importance to prove the presence of intrauterine gestation and to exclude gestational trophoblastic disease in the form of partial or complete mole.¹

There is a medicolegal aspect related to clinical practice suggesting that in all uterine evacuations a sample of tissues should be submitted for histopathological examination to confirm the presence of intrauterine fetal tissue.² It is often hoped especially in the clinical setting of recurrent spontaneous miscarriages, the further diagnostic information explain-

ing the underlying cause of pregnancy loss may be obtained from examination.³ An alternative approach is to examine the products only when there is a definite indication, such as when there is uncertainty about the diagnosis either pre-operative or during surgery.⁴

There are limited researches regarding this subject matter in this region. This study aimed to assess the role of histopathology in cases of first trimester miscarriages and to determine clinical relevance of histopathological examination following surgical evacuation.

METHODS

This was a retrospective study of patients attended at an agency for reproductive health in the Department of Obstetrics and Gynecology, Chitwan, Nepal from 2018 January to December 2018 with the diagnosis of miscarriage. All consecutive patients with history first trimester abortion (up to 12 weeks) without any preexisting medical co-morbidities were included while normal pregnancies with IUCD in situ was excluded. We considered first trimester abortion as early pregnancy loss which is defined as non-viable intrauterine pregnancy with either an empty gestational sac or gestational sac containing an embryo

or fetus without fetal heart activity within the first 13 weeks of gestation (NICE, 2012).⁵

The secondary data from patients' record files were collected on different variables like socio-economic status, level of literacy, occupational status of the patients. Demographic data including the age, parity, gestational age, use of medical termination pills (MTP), the surgical evacuation was performed in all patients. In patients included in this study, all the retained products removed surgically are routinely subjected to histopathological examination. The data was analyzed using descriptive statistics like percentage, stander deviation, mean, range in Microsoft Excel software. A p value <0.05 was considered for the statistical significance.

RESULTS

Out of all cases of abortion presenting to the hospital, a total number of 60 cases were diagnosed to have first trimester abortion. The mean age of the women was 27.3 years and ranged from 18 to 40 years. The parity ranged from 0 to 7 showed mean: 2.11± There was no significant difference (p=0.609[95%CI]) in the occurrence of abortions in multigravida 32 (53.33%) and in primigravida 28 (46.66%). Regarding occupations majority (53%) were housewives followed by 23% medical personnel, 10% bankers, 7% teachers, 5% entrepreneurs and 2% students.

Majority of cases had missed miscarriage in 33 patients (55%) followed by incomplete miscarriage in 18 patients (30%), blighted ovum in eight patients (13.33%) and septic abortion in one patient (1.66%), Table 1.

Majority of the patients presented with bleeding per vaginum 23(38.33%), 16 patients (26.66%) presented with scanty spotting per vaginum and the rest of them 21(35%) were detected to have missed abortion at routine first antenatal scan.

Table 1: Types of abortion

Type	Number (%)
Missed abortion	33(55)
Incomplete abortion	18(30)
Blighted Ovum	8(13.33)
Septic abortion	1(1.66)
Total	60(100)

Among patients with bleeding per vaginum, 18 (78.26%) had incomplete abortion and four patients (17.39%) had missed abortions and one patient (1.66%) had septic abortion. Pre-disposing factors such as the use of medical termination pills was seen in 15(25%), the other risk factors being smoking and alcohol consumption in 5(8.33%) and in remaining 40 patients (66.66%) no risk factors were found. Total of 15 (25%) patients in the study required blood transfusion in which most of the patients had incomplete abortion.

The use of MTP was also studied in multigravida and the primi-

gravida. Out of 15 MTP users in this study, multigravidas were observed to have used MTP more frequently 13 (86.66%) than the primigravida 2 (13.33%) (Figure 1). Most common type of abortion encountered in the MTP users was found to be the incomplete abortion 12 (80%) (Table 2).

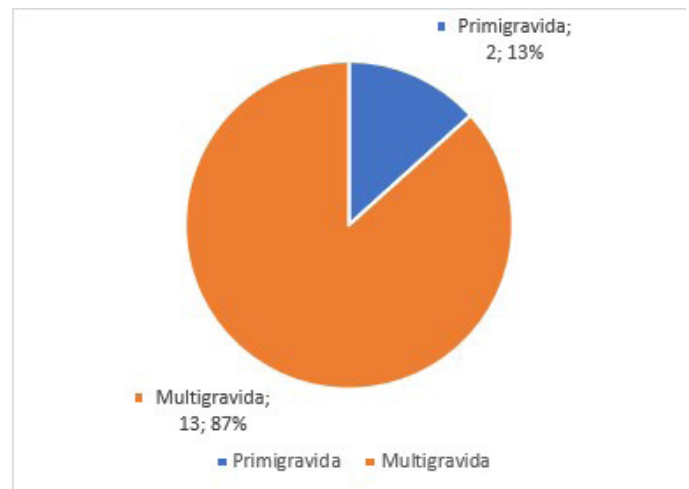
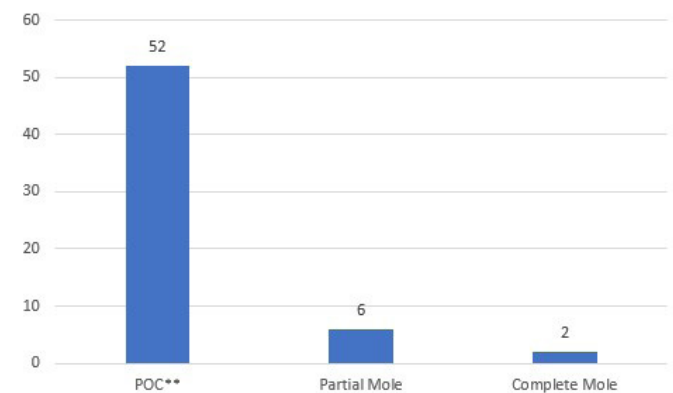


Figure 1: Pie chart showing the proportion of MTP use according to parity

Table 2: Types of abortion among MTP users

Type	Number (%)
Incomplete	12 (80)
Missed	3 (20)
Total	15 (100)

All the HPE reports confirmed the presence of pregnancy. Products of conception (POC) was seen in 52 (86.66%) patients, partial molar pregnancy in 6(10%) patient and a diagnosis of complete molar pregnancy found in 2(3.33%) patients (Figure 2).



**POC: Product of conception

Figure 2: Frequency distribution of histopathological diagnosis

DISCUSSION

The United States Centre for Disease Control and Prevention define miscarriage as a pregnancy termination before 20 weeks of gestation or a fetus weighing less than 500 gram.⁶ Ap-

proximately 10-20% of clinical pregnancies are lost spontaneously during the first trimester which is defined as the first 12 to 14 weeks.⁷⁻⁸ Miscarriage is a common condition in the first trimester of pregnancy and like many other disorders the accurate diagnosis is necessary for the management. But in some cases, it may be misdiagnosed when another condition that requires immediate treatment or long term follow up as an ectopic pregnancy or gestational trophoblastic disease exists.⁹ Ultrasound, quantitative beta human chorionic gonadotropin (B-HCG) testing and histopathologic examination of the uterine products are diagnostic tools to determine the type of miscarriage and to differentiate miscarriages from other conditions.

Some studies^{1,11,12} have found numerous pathologies in tissue from first trimester miscarriages, including complete mole, partial mole, exaggerated placental site, placental site trophoblastic nodule and decidual tissue. The authors of these studies concluded that routine histopathologic assessment of products of first trimester spontaneous miscarriages can lead to the diagnosis of important pathologies, more effectively identify ectopic pregnancies or infections than clinical or other laboratory criteria and may reduce mortality. By contrast, others have recommended against routine histopathological examination of tissues from first trimester miscarriages.

Heath et al⁹ found only two molar changes (0.13%) and two (0.13%) ectopic pregnancies among 1576 patients on histopathological evaluation of tissues removed during therapeutic or emergency uterine evacuation for spontaneous miscarriages. They recommended that histological examination of the products of conception should not be routinely performed at surgical termination of pregnancy.

In our study, we agree with studies by Novak et al¹⁴ and El-Halaby et al.¹² In study by Novak et al that all the tissues should be submitted to histopathological examination to investigate whether the abortion was due to dysmorphic changes or disruptive causes, to exclude the presence of trophoblastic disease and sometimes simply to confirm that pregnancy had occurred by showing the presence of fetal/placental tissues. EL-Halaby et al¹² reported 3.1% cases of partial mole, 1.25 cases of complete mole, 1.2% cases of ectopic pregnancy while Fram et al.¹⁰ reported 17% partial mole from 293 biopsies. They concluded that routine histopathology of first trimester miscarriages is very valuable as important findings like trophoblastic diseases and ectopic pregnancy can be diagnosed thus saving the lives of these patients.^{10,12}

In our study 6 patients (10%) had partial molar pregnancy and 2(3.33%) had complete molar pregnancy. The molar group was

followed up by weekly serum beta human chorionic gonadotropin level measurement till a negative level was obtained, thereafter monthly for next 6 months. The study by Alsibiani et al³ shows the incidence of missed abortion was the commonest (45.3%) during admission as compared to 55% in our study. In our study, 16 patients (48.5%) of missed miscarriage were detected during routine antenatal scan, 14 (42.42%) presented with scanty spotting per vaginum, 3 (9%) presented with heavy bleeding per vaginum.

A remarkable finding in this study is the increased risk of miscarriage among housewives which was significantly higher than rest of the study group.

Another observation was that the use of medical termination pills was found to be higher in multigravida 13(86.66%) than in primigravida 2(13.33%). The mean gestational age at first routine antenatal checkup in primigravida was 8.1 weeks whereas in multigravida it was 11.6 weeks. This gives the emphasis on making antenatal care more effective on making the women aware of the need for early health seeking behavior, the risks of miscarriages and ectopic pregnancies well explained to them.

Another significant finding was that 25% of patients in our study required blood transfusion due to severe blood loss during the process. Out of these 25% patients, 73% patients had incomplete abortion with heavy blood loss. This issue can be addressed by the proper education regarding the use of medical termination pills and to report immediately once they notice heavy flow. This way we can reduce the maternal morbidity and mortality.

The limitations of our study include a risk of potential observer bias, and this being a very small sample size, large-scale studies need to be done before formulating any plans.

CONCLUSION

In our study, histopathological assessment proved to be a vital tool in detecting molar pregnancy. It is very obvious from our study that histological results showing partial mole in 10% patients and complete mole in 3.33% patients. This 13.33% of molar pregnancies would have been missed without the histopathological analysis. We recommend that all the tissues obtained from the uterine evacuation in the first trimester should be routinely submitted for histopathological examination.

CONFLICT OF INTEREST: None

FINANCIAL DISCLOSURE: None

REFERENCES:

1. Fulcheri E, Di Capua E, Ragni N. Histologic examination of products of conception at the time of pregnancy termination. *Int J Gynaecol Obstet.* 2003 Mar;80(3):315-6. [\[DOI\]](#)
2. Bagshawe KD, Lawler S, Dent J, Brown P, Boxer GM, Paradinis FJ. Gestational trophoblastic tumours following initial diagnosis of partial hydatidiform mole. *Lancet.* 1990;335(8697):1074-6. [\[DOI\]](#)
3. Alsibiani SA. Value of histopathologic examination of uterine products after first-trimester miscarriage. *BioMed Res Int.* 2014; , Article ID 863482, 5 pages, 2014. [\[DOI\]](#)
4. Sebire NJ, Seckl MJ. Gestational trophoblastic disease: current management of hydatidiform mole. *BMJ.* 2008;337: a1193. [\[DOI\]](#)
5. National Institute for Health and Clinical Excellence. Ectopic pregnancy

- and miscarriage: diagnosis and initial management in early pregnancy of ectopic pregnancy and miscarriage. NICE clinical guidelines 154. manchester(UK). NICE; 2102. Available at: [\[LINK\]](#) Accessed May 10, 2020
6. Schorge JO, Schaffer J, Halvorson LM, Hoffman BL, Bradshaw KD, Cunningham G. First Trimester abortion. In: Williams Gynaecology, 1st Edition, New York: McGraw-Hill; 2008. p 299-322
 7. Hinshaw K, Fayyad A, Munjuluri P. The Management of Early Pregnancy Loss. RCOG Revised Guideline-25, 2006. [\[LINK\]](#)
 8. Van Look PF, Cottingham J. The World Health Organization's Safe Abortion Guidance Document. Am J Public Health. 2013;103(4):593-6. [\[DOI\]](#)
 9. Heath V, Chadwick V, Cooke I, Manek S, MacKenzie IZ. Should tissue from pregnancy termination and uterine evacuation routinely be examined histologically? BJOG. 2000;107(6):727-30. [\[DOI\]](#)
 10. Fram KM. Histological analysis of the products of conception following first trimester abortion at Jordan University Hospital. Eur J Obstet Gynecol Reprod Biol. 2002;105(2):147-9. [\[DOI\]](#)
 11. Tasci Y, Dilbaz S, Secilmis O, Dilbaz B, Ozfuttu A, Haberal A. Routine histopathologic analysis of product of conception following first-trimester spontaneous miscarriages. J Obstet Gynaecol Res. 2005;31(6):579-82. [\[DOI\]](#)
 12. El-Halaby A, Aziz OA, Elkemani O, Nasr MA, Sanad Z, Samaka R. The value of routine histopathological examination of products of conception in case of first trimester spontaneous miscarriage. Tanta Med Sci J. 2006; 1(4): 83-8. [\[LINK\]](#)
 13. Steigrad SJ. Epidemiology of gestational trophoblastic diseases. Best Pract Res Clin Obstet Gynaecol. 2003; 2003 Dec 1;17(6):837-47. [\[DOI\]](#)
 14. Novak RW, Malone JM, Robinson HB. The role of the pathologist in the evaluation of first trimester abortions. Pathol Annu. 1990; 25 Pt 1:297-311. [\[PMID\]](#)
 15. Al Alaf SK, Omer DI. Pattern of cases of gestational trophoblastic diseases among pregnant women admitted to the Maternity Teaching Hospital in Erbil. WSEAS Transactions on Biology and Biomedicine. 2010;7(3):190-9. [\[LINK\]](#)
 16. Paradinas FJ. The diagnosis and prognosis of molar pregnancy: the experience of the National Referral Centre in London. Int J Gynecol Obstet. 1998;60 Suppl 1: S57-64. [\[PMID\]](#)
 17. Fram KM. Histological analysis of the products of conception following first trimester abortion at Jordan University Hospital. Eur J Obstet Gynecol Reprod Biol. 2002;105(2):147-9. [\[DOI\]](#)
 18. Bagshawe KD, Lawler SD, Paradinas FJ, Dent J, Brown P, Boxer GM. Gestational trophoblastic tumours following initial diagnosis of partial hydatidiform mole. Lancet. 1990;335(8697):1074-6. [\[DOI\]](#)
 19. Bennet MJ. Abortion. In: Symonds I, Arulkumaran S, editors. Essentials of Obstetrics Gynecology. 3rd Edition. Philadelphia; WB Saunders Company: 1998. p.477-487.
 20. Poland BJ, Miller JR, Jones DC, Trimble BK. Reproductive counseling in patients who have had a spontaneous abortion. Am J Obstet Gynecol. 1977;127(7):685-91. [\[DOI\]](#)
 21. Warbuton D, Fraser FC. Spontaneous abortion risks in man: data from reproductive histories collected in a medical genetic unit. Am J Hum Genet. 1964; 16(1):1-25. [\[PMID\]](#)