



CASE REPORT

ORAL PEMPHIGUS VULGARIS: A CASE REPORT

Radha Baral^{1,*}, Bidhata Ojha¹, Dipshikha Bajracharya¹

¹Department of Oral Pathology, Kantipur Dental College, Kathmandu, Nepal

Received: 25 Feb, 2020

Accepted: 11 Mar, 2020

Published: 13 Mar, 2020

Key words: Acantholysis; Desmoglein 3; Pemphigus vulgaris.

***Correspondence to:** Radha Baral, Department of Oral Pathology, Kantipur Dental College, Kathmandu, Nepal.
Email: radhabaral22@gmail.com

DOI: <https://doi.org/10.3126/jcmc.v10i1.28082>

Citation

Baral R, Ojha B, Bajracharya D. Oral Pemphigus Vulgaris: a case report. Journal of Chitwan Medical College. 2020;10(31):91-93.

ABSTRACT

Pemphigus vulgaris is an autoimmune blistering disease clinically presenting as vesicles, bullae and erosion on the skin and mucous membrane. Histopathologically, it is characterized by acantholysis and supra basilar split. The underlying mechanism causing intra epithelial split in pemphigus vulgaris is binding of IgG autoantibodies to desmoglein 3 which belongs to a transmembrane glycoprotein adhesion molecule. Here we present a case of 27 years old male patient suffering from pemphigus vulgaris. This Case report highlights the importance of detailed case history, thorough clinical examination and appropriate investigation to reach a diagnosis of vesiculobullous lesion.



INTRODUCTION

Pemphigus vulgaris (PV) is a rare mucocutaneous autoimmune disease with a potentially lethal consequence. The term "pemphigus" is derived from the Greek word pemphix (bubble or blister) and "vulgaris" is derived from a latin word vulgaris (common).¹ The global prevalence of pemphigus vulgaris is approximately 0.1 to 0.5% per million population per year with higher prevalence in certain ethnic groups, such as Ashkenazi Jews, Japanese, and populations from the Mediterranean ancestry.^{2,3} The disease is mediated by circulating immunoglobulin G (IgG) autoantibodies against the desmosomal cadherin, desmoglein 1 and 3. Desmoglein 1 (dsg-1) is mostly seen within the epithelium of skin, while desmoglein 3 (dsg-3) is commonly seen in mucosal epithelium.^{4,9} Recent study also implicate the role of keratinocyte acetylcholine receptors as potential targets for autoantibodies in pemphigus.⁴ There are five groups of pemphigus: Pemphigus vulgaris (PV), pemphigus foliaceus, paraneoplastic pemphigus (PNP), drug-induced pemphigus and immunoglobulin A (IgA) pemphigus. Oral lesions have been associated with only PV and PNP.⁵ Here, we report a case of pemphigus vulgaris evident on oral mucosa with minor involvement of skin.

CASE REPORT

A 27 years old male patient presented with chief complaint of pain and ulceration in mouth for 3 years. Patient also complained of recurrent itchy skin lesion on trunk. Patient had history of taking Gutkha 5-6 times a day for 3 years but had stopped after the appearance of the lesions. Medical and family history was non-contributory. Intraoral examination of the patient revealed erosion, ulceration and sloughing on the buccal mucosa involving retromolar region bilaterally. Ulceration and fluid filled vesicles were also evident lateral border and ventral surface of tongue, floor of mouth and soft palate (Figure 1). Similar types of few lesions were also present on skin of neck and chest region. Nikolsky sign was positive. Based on the clinical finding differential diagnosis of pemphigus, bullous lichen planus and pemphigoid was given.

Incisional biopsy of the lesion was performed under local anesthesia from the left buccal mucosa and left lateral border of tongue. The specimen received consisted of two tissues. Tissue from left buccal mucosa was brownish white in color firm in consistency measuring 1cm x 0.7cm in size. The other tissue from the left lateral border of tongue was whitish in color firm in consistency measuring 1cm x 0.9cm in size (Figure 2). One

part of each specimen was kept in 10% formalin for histopathological examination. The remaining half of the specimen was kept in Michel's solution for the direct immunofluorescence test.

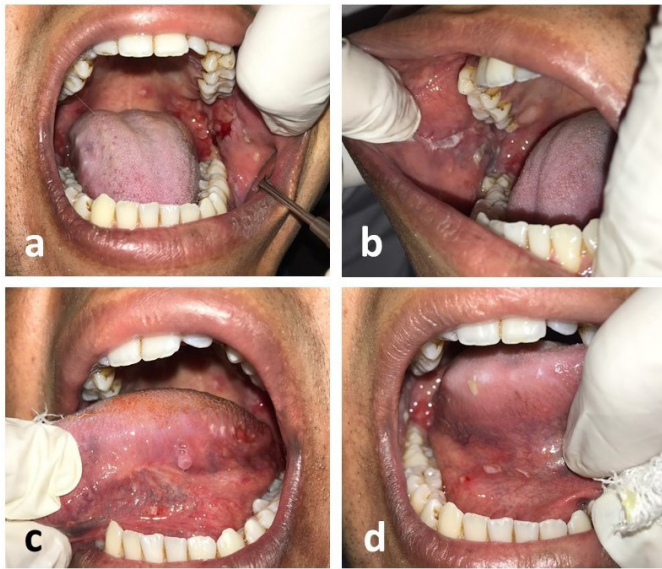


Figure 1: Intraoral presentation (a) ulceration on left buccal mucosa and retromolar area (b) ulceration and sloughing in right buccal mucosa (c) vesicle on ventral surface and ulceration of left lateral border of tongue (d) ruptured vesicle and ulceration on the floor of mouth on right side



Figure 2: Tissue specimen (a) from buccal mucosa (b) from floor of the mouth

Histopathological examination of both the specimen revealed non-keratinized stratified squamous epithelium showing areas supra basal split. The basal cells showed histologic pattern as "row of tombstone". Cluster of Tzanck cells with hyperchromatic nuclei were seen lying freely in the vesicular space. The basal cells were attached to the basement membrane along with underlying connective tissue. The underlying connective tissue revealed dense chronic inflammatory cell infiltration chiefly lymphocytes and plasma cells (Figure 3). The microscopic features were indicative of Pemphigus vulgaris which was further confirmed by direct immunofluorescence test which revealed IgG in intercellular bridges in epithelium. Based on clinical features, histopathological features and immunofluorescence test final diagnosis of Pemphigus Vulgaris was given.

Patient was treated with Prednisolone 1mg/kg/day for two weeks along with topical anesthetic agents and follow up was done on weekly basis. Gradual tapering of the dose was

planned followed by topical application only.

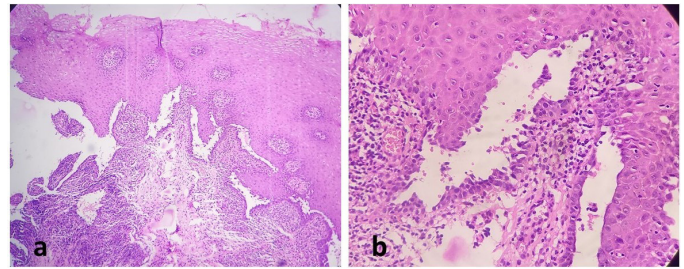


Figure 2: Histopathological features (a) Epithelium showing supra-basal split (H & E, 10X), (b) Epithelium showing supra-basal split and Tzanck cells in the vesicular space (H & E 40X)

DISCUSSION

Pemphigus is a chronic inflammatory disease of autoimmune origin.⁶ The age of onset of disease is usually on 5th and 6th decade of life with male to female ratio of 1:2.^{2,6} The classic clinical presentation of pemphigus vulgaris is a thin walled bulla arising on skin or mucosa. The bullae are fragile and break readily, leaving denuded areas of variable size that tend to enlarge as the epithelium detaches from the dermis at the periphery.⁷ In 70-90% of the cases of pemphigus vulgaris oral mucosa is involved prior to the involvement of the skin.⁵ The common site for oral mucosal lesions are gingiva, buccal mucosa, lips, and soft and hard palate.⁸ In the present case erosive and ulcerative lesions were present on the buccal mucosa, retromolar area, lateral border of tongue, floor of mouth and soft palate. The ulceration and erosion preceded by vesicle formation.

Pemphigus vulgaris exhibits positive "Nikolsky's sign" which is the ability to induce peripheral extension of a blister and/or exfoliation of epithelium as a consequence of applying tangential pressure with an index finger or thumb to the affected skin, peri-lesional skin, or normal skin.^{3,7} Nikolsky's sign was positive in the present case which gave a clue to the diagnosis of the disease.

Classic histopathological feature of pemphigus is acantholysis and supra-basilar split which was seen in this case. The diagnosis of the bullous lichen planus was ruled out on the basis intact basal cells and diagnosis of the mucous membrane pemphigoid was ruled out on the ground of basal cells attached firmly with the basement membrane along with underlying connective tissue and absence of subepithelial split which is the characteristic feature of pemphigoid.

The desmosomal cadherin component Dsg 1 and Dsg 3 are responsible for the adhesion of the cells in epithelium. Epidermis of skin expresses both Dsg 1 and Dsg 3 while oral epithelium mostly expresses Dsg 3. Expression of Dsg 1 is seen in superficial layers of epithelium and expression of Dsg 3 is seen in basal and supra-basal layers. Antibodies against Dsg 3 causes loss of adhesion and formation of bulla in pemphigus vulgaris. Maintenance of skin integrity in this case in maintained by Dsg 1. Blister formation in superficial epidermis in pemphigus folia-

ceous is caused by anti Dsg 1 antibodies. Mucosal involvement is not seen as mucosal integrity is accomplished through Dsg 3.⁹ In the present case auto antibodies (IgG) were seen bound with the component of the desmosome in direct immunofluorescence test.

The systemic corticosteroids are considered as gold standard for the treatment of pemphigus vulgaris, present case was also managed with systemic corticosteroid. Azathioprine and myco-

phenolate mofetil are the first line steroid sparing treatment.¹⁰

CONCLUSION

This case report highlights the importance of detailed case history, thorough clinical examination and appropriate diagnostic modalities such as routine biopsy and immunofluorescence test to differentiate pemphigus vulgaris from other vesiculobullous lesion.

REFERENCES:

1. Hasan S, Ahmed S, Khan NI, Tarannum F. Pemphigus vulgaris—a case report and detailed review of literature. *Indian J Dent.* 2011;2(3):113–9. [\[DOI\]](#)
2. Bascones-Martinez A, Munoz-Corcuera M, Bascones-Ilundain C, Esparza-Gómez G. Oral manifestations of pemphigus vulgaris: Clinical presentation, differential diagnosis and management. *J Clin Exp Dermatol Res.* 2010;1(112):2-5. [\[LINK\]](#)
3. Banerjee I, Bhowmik B, Maji A, Sinha R. Pemphigus Vulgaris- A report of three cases and review of literature. *J Fam Med Prim Care.* 2018;7(5):1109–12. [\[DOI\]](#)
4. Kala N, Manjeu J, Dominic N, Babu SP. Oral pemphigus without skin lesions treated with pulse steroid therapy. *J Indian Soc Periodontol.* 2018;22(6):551–4. [\[DOI\]](#)
5. Kumar SJ, Anand SN, Gunasekaran N, Krishnan R. Oral pemphigus vulgaris: A case report with direct immunofluorescence study. *J Oral Maxillofac Pathol.* 2016;20(3):549. [\[DOI\]](#)
6. Rai A, Arora M, Naikmasur V, Sattur A, Malhotra V. Oral Pemphigus Vulgaris: Case Report. *Ethiop J Health Sci.* 2015;25(4):367–72. [\[DOI\]](#)
7. Dagistan S, Goregen M, Miloglu O, Cakur B. Oral pemphigus vulgaris: a case report with review of the literature. *J Oral Sci.* 2008;50(3):359–62. [\[DOI\]](#)
8. Pettini F, Ballini A, Capodiferro S, Cantore S, Cirulli N, Garofalo A, et al. Management of oral pemphigus vulgaris: A case report and a clinical update. *Eur J Inflamm.* 2015;13(1):53–7. [\[DOI\]](#)
9. Robinson NA, Yeo JF, Lee YS, Aw DCW. Oral pemphigus vulgaris: A case report and literature update. *Ann Acad Med.* 2004;33(4):63–8. [\[LINK\]](#)
10. Gregoriou S, Efthymiou O, Stefanaki C, Rigopoulos D. Management of pemphigus vulgaris: Challenges and solutions. *Clin Cosmet Investig Dermatol.* 2015;8:521–7. [\[DOI\]](#)