

CASE REPORT

LYMPHOEPITHELIAL CYST OF THE PAROTID IN HIV NEGATIVE INDIVIDUAL: A CASE REPORT

Paras Raj Amatya^{1*}, Tilak Raj Limbu¹, Sovit Jung Baral¹, Shankar Bastakoti²

¹Department of ENT, Chitwan Medical College, Chitwan.

²Department of Pathology, BP Koirala Memorial Cancer Hospital, Chitwan

Received: 4 Dec, 2019

Accepted: 20 Dec, 2019

Published: 27 Dec, 2019

Key words: HIV infections; Lymphoepithelial cyst; Parotid gland.

***Correspondence to:** Paras Raj Amatya, Department of ENT, Chitwan Medical College, Chitwan, Nepal.
Email: amatyaparas@gmail.com

DOI: <https://doi.org/10.3126/jcmc.v9i4.26910>

Citation

Amatya PR, Limbu TR, Baral SJ, Bastakoti S. Lymphoepithelial cyst of the parotid in HIV negative individual: a case report. 2019;9(30):81-82.

ABSTRACT

Benign Lymphoepithelial cyst (BLEC) of parotid gland are more common in HIV positive patients and is rare in HIV negative individuals. We present a 16-year-old HIV negative female who presented with a painless, gradually increasing swelling in the left parotid region. Excisional biopsy was done and HPE showed benign lymphoepithelial cysts. The rarity of this lesion in a HIV negative patient is the main reason for reporting this case.



INTRODUCTION

Benign Lymphoepithelial Cysts (BLEC) of parotid gland are more common in HIV positive patients and are virtually pathognomonic for HIV.¹ The term “lymphoepithelial cyst” was introduced by Bernier and Bhaskar to stress that this lesion is not an embryologic remnant. They are slow growing, occur more often in the tail of parotid and may be solitary or multiple.² Males and females are affected equally.¹ These lesions are rare in HIV negative individuals¹ and present as painless mass. In this report, lymphoepithelial cyst was diagnosed in a young HIV negative female.

CASE REPORT

A 16 year old female, from western Nepal, presented to the ENT outpatient department with complaints of recurrent swelling in the left- post- auricular region. The swelling was slowly increasing and painless. The patient has undergone surgical procedure for similar swelling 6 years ago (which was not documented) but the swelling recurred after about 6 months of the procedure. The swelling was not causing any difficulty in moving head. On Inspection, there was a swelling of about 1 cm x 1cm in size just posterior to the ear lobule. There was also

a scar mark of previous surgical procedure in left post auricular region. On palpation 3-4 non tender, cystic swelling of about 1 cm x 1 cm in size was found in the left retro mandibular area. The facial nerve function was intact. The CECT of neck showed

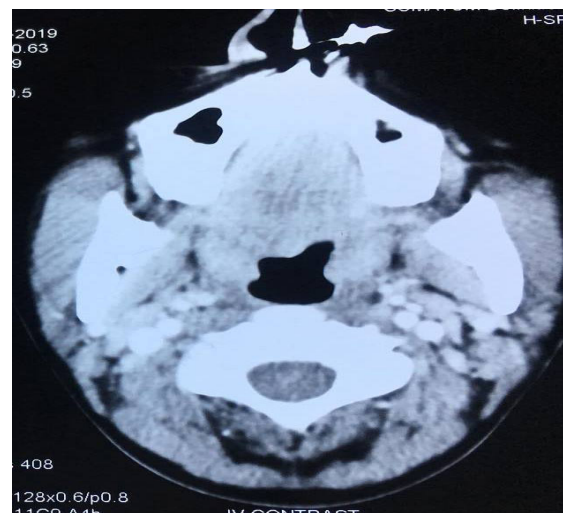


Figure 1: CECT of neck showing solid cystic lesions in left parotid space

heterogeneous enhancing solid cystic lesion in left parotid space involving the superficial and deep part of the left parotid gland with focal involvement and bulkiness of left sternocleidomastoid posteriorly and extending cranially up to the inferior wall of external auditory meatus (Figure 1).

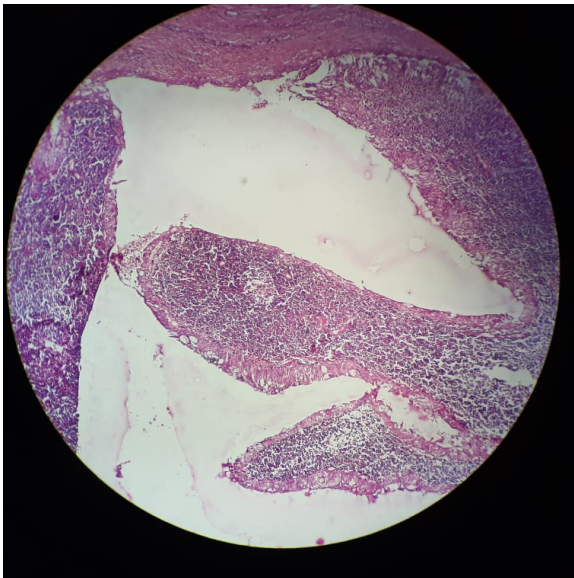


Figure 2: Cystic structure with epithelial lining, underneath lymphocytes forming follicles. (H&E, 10x)

Routine HIV antibody test (IgG/IgM/IgA) was done prior to surgery and was found to be non-reactive. Excisional Biopsy was done under local anesthesia. Multiple cystic swelling containing mucoid material, matted to each other was present in left post auricular and left level II region (Figure 2). HPE showed multiple varying sized cystic spaces lined by squamous and some columnar lining with underlying subepithelium lymphoid aggregates with germinal centers. Secretory material was noted within the cyst suggestive of lymphoepithelial cyst. It was negative for atypical cells and for granuloma and necrosis. On one month follow up, swelling could be palpated on deep palpation but there was no visible swelling and no cosmetic deformity. The patient refused any surgical intervention and has been kept under observation and regular follow up.

DISCUSSION

BLEC are thought to develop from cystic degeneration within the lymph nodes of parotid gland.^{1,2} They present as persistent non tender enlargement associated with cervical lymphadenopathy.³ The majority of salivary gland masses in HIV positive patients are the results of BLEC and this entity occurs in 3% to 6% of adults and 1% to 10% of children with HIV.^{4,5} However BLEC is rare in HIV negative individuals.

Histologically BLEC have cyst wall lined by hyperplastic and metaplastic squamous epithelium and contains aggregation of lymphoid proliferation.³ Though differential diagnosis of salivary gland disease (SGD) in seropositive patients would include diffuse infiltrative lymphocytosis syndrome (DILS), parotitis, intraparotid lymphadenopathy, adenoid cystic carcinoma, Kaposi sarcoma, and lymphoma; their varied clinical, radiological, and microscopic features will differentiate them from BLECs.⁶ Literature review has no mention of these entities in HIV negative patients.

In HIV positive patients, BLEC regresses with antiviral therapy.⁷ For minimally symptomatic patients without significant cosmetic deformity, observation alone represent the best option. Other modalities like low dose radiation, sclerotherapy and repeated aspiration has also been used.^{4,8} Malignant transformation of BLEC has not been reported yet.³ Parotidectomy or enucleation of lesions may be considered if there is rapid change in size, are disfiguring or have significant pressure symptoms. Though multiple treatment are available, there are very few article outlining the management in non HIV patient. In most of the similar case studies, retrospective diagnosis of BLEC was made after parotidectomy. However, in this case, since there was no cosmetic deformity, the patient was kept in observation and routine follow up.

CONCLUSION

Though common in HIV positive patients, BLEC can also occur rarely in HIV negative patients as well. Hence, they should be considered as a differential diagnosis in benign parotid cystic swelling. Further studies in HIV negative individuals are needed to find out appropriate treatment modality.

REFERENCES:

1. Joshi J, Shah S, Agarwal D, Khasgiwal A. Benign lymphoepithelial cyst of parotid gland: Review and case report. *Journal of oral and maxillofacial pathology: JOMFP*. 2018 Jan;22(Suppl 1):S91 – S97. [\[DOI\]](#)
2. Naidoo M, Singh B, Ramdial PK, Moodley J, Allopi L, Lester B. Lymphoepithelial lesions of the parotid gland in the HIV era-a South African experience. *South African Journal of Surgery*. 2007;45(4):136-41.
3. Dave SP, Pernas FG, Roy S. The benign lymphoepithelial cyst and a classification system for lymphocytic parotid gland enlargement in the pediatric HIV population. *The Laryngoscope*. 2007 Jan;117(1):106-13. [\[DOI\]](#)
4. Pillai S, Agarwal AC, Mangalore AB, Ramaswamy B, Shetty S. Benign lymphoepithelial cyst of the parotid in HIV negative patient. *Journal of clinical and diagnostic research: JCDR*. 2016 Apr;10(4):MD05 – 06. [\[DOI\]](#)
5. Michelow P, Dezube BJ, Pantanowitz L. Fine needle aspiration of salivary gland masses in HIV-infected patients. *Diagnostic cytopathology*. 2012 Aug;40(8):684-90. [\[DOI\]](#)
6. Shivhare P, Shankarnarayan L, Jambunath U, Basavaraju SM. Benign lymphoepithelial cysts of parotid and submandibular glands in a HIV-positive patient. *Journal of oral and maxillofacial pathology: JOMFP*. 2015 Jan;19(1):107. [\[DOI\]](#)
7. Mandel L, Surattanont F. Regression of HIV parotid swellings after antiviral therapy: case reports with computed tomographic scan evidence. *Oral Surgery, Oral Medicine, Oral Pathology, Oral Radiology, and Endodontology*. 2002 Oct 1;94(4):454-9. [\[DOI\]](#)
8. Carnelio S, Chandramouli M, Rodrigues G. Parotid Lymphoepithelial Cyst in a HIV-Negative Individual: A Case Report. *Iran J Med Sci*. 2018.43(6):668-670. [\[PMID\]](#)