



ORIGINAL RESEARCH ARTICLE

ADEQUACY OF THREE DIMENSIONAL MINIPLATE IN TREATMENT OF MANDIBULAR FRACTURE IN INTERFORAMINAL REGION

Vivek Singh^{1,*}, Ritesh Giri¹

¹Department of Oral and Maxillofacial Surgery, Nobel Medical College and Teaching Hospital, Biratnagar, Nepal

Received: 14 May, 2019

Accepted: 12 June, 2019

Published: 15 June, 2019

Key words: Interforaminal region; Mandible fracture; Three-dimensional plate.

**Correspondence to: Vivek Singh, Department of Oral and Maxillofacial Surgery, Nobel Medical College and Teaching Hospital, Biratnagar, Nepal.
Email: vivekomfs@gmail.com*

DOI:<http://doi.org/10.3126/jcmc.v9i2.24563>

Citation

Singh V, Giri R. Adequacy of three dimensional miniplate in treatment of mandibular fracture in interforaminal region. Journal of Chitwan Medical College. 2019; 9(28):97-2.



ABSTRACT

Background: Mandible is one of the commonly fractured bone due to trauma, assault and falls. Treatment includes closed and open methods. Methods of open reduction and internal fixation have changed and diversified enormously in the past few years. Champy's miniplate fixation, dynamic compression plating has become a standard approach. More recently, three dimensional miniplates have been developed by Farmand which may be effectively used in mandibular fractures. The aim of this study was to check the adequacy of three dimensional miniplate in management of mandibular fracture occurring in the interforaminal region.

Methods: A prospective clinical study was carried out in patients attending Emergency Department and Department of Oral and Maxillofacial Surgery, Nobel Medical College and Teaching Hospital (NMCTH) suffering from mandibular fractures in interforaminal region from May 2018 to January 2019.

Results: A total of 17 patients with 18 fracture in interforaminal region, all male were included in the study. The age ranged from 16 to 50 years with a mean of 29.17 ± 9.48 . Road traffic accident was the leading cause of injury with 15 out of 17 patients (88.23%). There was no incidence of wound infection, wound dehiscence, malunion, nonunion, plate fracture within the follow up period of 3 months. One fracture was unstable on 1st postoperative day and also had mildly deranged occlusion which was managed with intermaxillary fixation for two weeks.

Conclusions: Three dimensional plates fulfills the treatment goals of adequate stabilization and fixation of mandibular interforaminal fractures.

INTRODUCTION

Mandible is one of the commonly fractured bone due to trauma, assault and falls. Its prominence also makes it very vulnerable to fracture. In the quest of fast transportation, high velocity trauma has increased significantly leading to increased incidence of mandibular fractures.

Treatment of mandibular fractures can be done by closed and open methods. Through the decades various plate and screw osteosynthesis have been

introduced like dynamic compression plate (DCP), Champy's monocortical miniplate, resorbable plates and screws and locking miniplates.¹ More recently, three dimensional miniplate (3D) have been developed by Farmand.^{2,3} Their shape is based on the principle of the quadrangle as a geometrically stable configuration for support. The name 3D is given because it provides three-dimensional stability by the geometric shape that forms a cuboid. Various experimental studies on biomechanics have confirmed sufficient stability of the 3D plating system.⁴⁻⁷ The observations in these few studies are encouraging,

with fewer complications.⁴⁻⁷

This prospective clinical study was carried out to evaluate the adequacy of 3D miniplate fixation in the management of mandibular fractures occurring in between the two mental foramens (interforaminal region).

METHODS

A prospective clinical study was carried out in patients attending Emergency Department and Department of Oral and Maxillofacial Surgery at Nobel Medical College and Teaching Hospital, Biratnagar, Nepal from May 2018 to January 2019. Seventeen patients with 18 fractures in interforaminal region requiring open reduction and internal fixation were selected for the study. Approval was taken from institutional review committee and informed written consent was taken prior to surgery and the source data was collected in enclosed proforma. Those patients who reported within two weeks of injury and who were willing to return for follow-up were included in the study while infected fractures, comminuted fractures, complete edentulous patients, medically compromised patients and fractures associated with body, ramus, condyle and coronoid were excluded. Data were collected and tabulated using Microsoft excel and analysis was done using SPSS version 16.

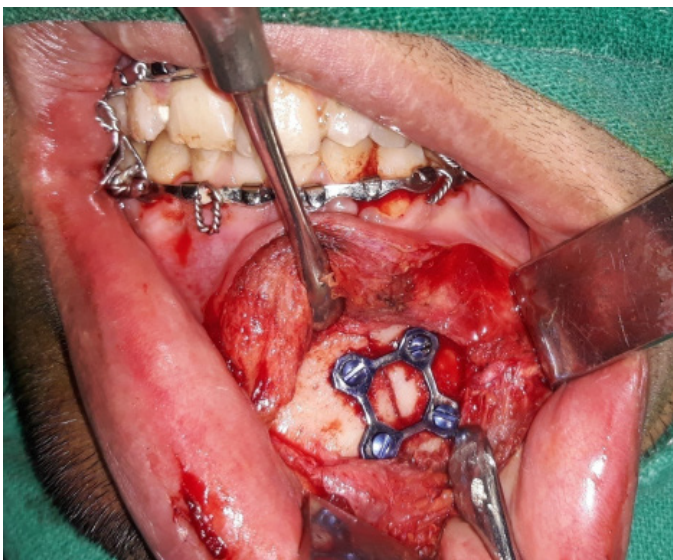


Figure 1: Intraoperative Fixation of Parasymphysis fracture with 3D plate

Emergency care was provided immediately for all

the patients during the time of admission. Antibiotics and analgesics were started as per trauma protocol of the hospital. All patients were treated under general anesthesia with nasotracheal intubation. Upper and lower arch bars or eyelet wires were placed in both the arches to secure occlusion before fixation. Mandibular degloving incision as well as existing lacerations were used for surgical exposure of fracture site. All fractures were fixed with 3D plate and secured with monocortical 2mm X 8mm screws (Figure 1). Occlusion was checked for all the patients before closing the surgical site. Operative site was closed using 4-0 Vicryl suture (Ethicon). An extra oral pressure bandage was applied postoperatively for 72 hours to prevent hematoma, edema and better reattachment of mentalis muscle. All patients were advised to take liquid diet for 5 days and thereafter on a soft diet for 2 weeks. They were also advised to use 0.12% chlorhexidine gluconate mouth rinse frequently to keep the mouth clean.

Patients were followed for 3 months on following parameters: radiological evaluation of reduction and fixation, segmental mobility, postoperative occlusion, additional fixation, infection, wound dehiscence.

In the present study, the definitions for the used parameters are as follows:

Table 1: Radiological Assessment with Post-operative Radiographs (OPG).

Score 3	Radiological evidence of precise anatomic reduction in the fracture site
Score 2	Reduced fractures that were slightly displaced but had a satisfactory occlusion
Score 1	Poorly reduced fractures that required a second operation to correct poor alignment and unacceptable occlusion

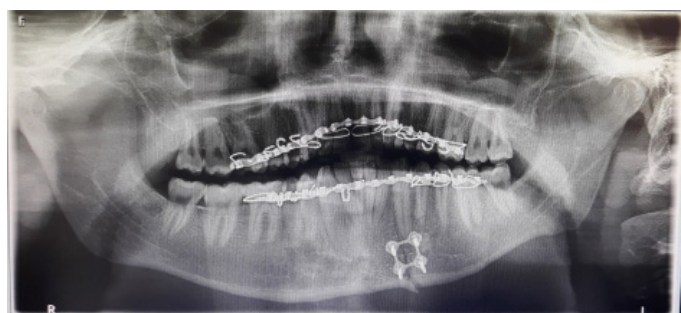

Figure 2: Fixation of Parasymphysis fracture with 3D plate.

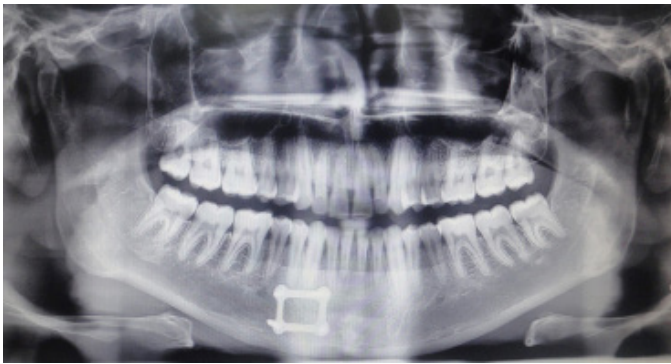

Figure 3: OPG of 90th Post-operative Day

Radiograph was taken preoperatively, on 1st post-operative day (Figure 2) and on 90th postoperative day (Figure 3). Radiological Assessment with Post-operative Radiographs (OPG) was done according to Malhotra et al⁸ and scores given as shown in Table 1.

Table 2: Clinical Assessment of Occlusion.

Satisfactory	No discrepancy between pre trauma occlusion and postoperative occlusion in molar or canine region
Mildly de- ranged	Discrepancy of 1 – 2mm between pre trauma occlusion and postoperative occlusion in molar or canine region
Deranged	Discrepancy more than 2mm between pre trauma occlusion and postoperative occlusion in molar or canine region

Fracture stability in this study was checked by digital palpation i.e. placing index finger of one hand on proximal and another on distal fragments intraorally and thumb of both hand at the inferior border extra-

orally. Stability was assessed by applying pressure alternatively. Scores were given as stable when there was no movement of fragments and unstable when movement was present. Occlusion was assessed as done by Vineeth et al⁹ as shown in Table 2.

Other parameters like need for additional fixation presence or absence of infection presence or absence of wound dehiscence were noted.

RESULTS

All the 17 patients were male. Age ranged from 16 to 50 years with a mean of 29.17±9.48. Distribution of age is given in Table 3. Road traffic accidents was the most common etiological factor with 15 out of 17 patients followed by one fall injury and one self-sustained injury with bamboo stick. A total of 18 fracture were present with 10 right parasymphysial, and six left parasymphysial and two symphysial fracture.

Table 3: Distribution of Age.

Age	Frequency	Percentage (%)
16-25	07	41.17
26-35	06	35.29
36-45	02	11.76
>45	02	11.76
Total	17(100%)	100

Table 4: Radiological Assessment with Post-operative Radiographs on 1st Postoperative day and 90th Postoperative day.

Radiological Assessment with Post-operative Radiographs	1 st post operative				90 th post operative			
	Day				Day			
	Score 1	Score 2	Score 3	Total	Score 1	Score 2	Score 3	Total
(n=18)	0	3	15	18	0	1	17	18
Percentage (%)	0	16.67	83.33	100	0	5.56	94.44	100

Table 4 shows the radiological assessment with post-operative radiographs on 1st post-operative day and 90th post-operative day.

The average time required to perform the surgery was 41 minutes. One fracture was unstable on 1st postoperative day and also had mildly deranged

occlusion which was managed with intermaxillary fixation for two weeks. There was no incidence of infection or wound dehiscence in this study. None of the patients had malunion, nonunion, plate fracture, and within the follow up period of 3 months.

DISCUSSION

The treatment of mandible fractures has been studied over the past century and the treatment philosophies continue to evolve.¹⁰ The objectives in the treatment of mandibular fracture are to re-establish normal occlusion and masticatory function with minimal disability and complications.⁸ Conservative treatment to achieve this is performed by immobilizing the mandible for the healing period by intermaxillary fixation which is achieved by dental wiring, arch bars, cap splints, and gunning splints. Operative treatment of mandibular fractures involves intra or extraoral exposure of the fracture site and direct osteosynthesis with transosseous wires, lag screws, or bone plates.¹¹ A number of fixation methods have been advocated for the treatment of mandibular fractures.⁸ In this study, 3D plate was used for fixation of mandible fractures in interforaminal region.

The predominance of mandible fractures in men is a relatively consistent finding in most studies.¹²⁻¹⁴ In the present study, interestingly all the 17 patients were male. In a retrospective analysis of 279 patients, Veikko et al found that the fractures occurred most frequently in the 20 to 29 years age group.¹³ In another study, the fractures had occurred most frequently in the age of 37 years.¹⁵ The mean age of patient in this study was 29.17 ± 9.48 , ranging from 16 to 50 years. The maximum number of fracture occurred in 16 to 25 (41.17%) age group followed by 26 to 35 years age group (35.29%) with more than two-third cases (76.46%) falling in these two age groups.

The mechanism of facial trauma varies in different cultures and societies but road traffic accident is the leading cause across most population.^{12, 14-17} The most common reason for injury in this study was also road traffic accident (88.23%).

The radiological assessment with post-operative radiographs showed three patients to have reduced fractures that were slightly displaced but had a satisfactory occlusion (Score 2) while rest of the patient

had radiological evidence of precise anatomic reduction in the fracture site (Score 3) on 1st operative day. Similarly, 1 patient had score of 2 and rest patient had score of 3 on 90th postoperative day. However, both these patients had satisfactory occlusion with no signs of infection.

It is of utmost importance to establish the optimum, pre-existing functional occlusion. The slightest deviation of the fragments may cause premature occlusal contacts and malocclusion, which may necessitate extensive restorative dentistry later.¹⁸ Champy et al (1978) found 0.5% malocclusion in a series of 183 patient with mandibular fracture treated with 2 mm miniplates.¹⁹ Similarly, Renton and Wiesenfeld (1996) found 9% malocclusion in 123 patient.¹⁹ Most of these patient were treated with post-operative intermaxillary fixation with guiding elastics while few required hardware removal and subsequent intermaxillary fixation for 4-6 weeks or fixation with a larger hardware.¹⁹ The use of a single 2.0-mm miniplate adapted along Champy's line of ideal osteosynthesis and stabilized with 4 monocortical screws plus two weeks of maxillomandibular fixation was a viable treatment modality for mandibular fractures.²⁰ This technique was used for non-communited, uninfected mandible fractures.²⁰ Wittenberg, in a prospective study, reported the stabilization of 20 fractures of the mandibular angle; 12 were associated with additional fracture of the body using 3D plates. All patients had a stable occlusion after healing of fracture. In five cases, in addition to osteosynthesis, light maxillomandibular elastics bands were placed for two to three days. In two cases, infection occurred because of screw loosening.¹³ In our study one patient had mildly deranged occlusion on 1st post-operative day and this patient was placed on guiding elastics for a period of two weeks resulting in satisfactory occlusion.

With the miniplates the reported incidence of infection varies from 4% to 16%.¹⁹ Communited fracture and mobility of fragments has been shown to predispose to infection.¹⁹ Non-union and delayed union are usually the result of infection or conditions that decrease the blood supply. In the previous literature it was quoted that incidence of malunion and nonunion is between 1% and 2%.²¹ Potter and Ellis encountered 10.8% of plate fracture with 1.3 mm malleable noncompression miniplates which in turn resulted in interfragmentary mobility and non-

union.²² Farmand (1993) in his study with 140 patients treated with 3D titanium miniplate reported one case of plate fracture.³In this study there was no case of infection and dehiscence. There was also no evidence of non-union, malunion and plate fracture.

Only a few follow-up series are presented in the literature, with few studies^{2,5,23,24} emphasizing the hardware-related advantages of 3D plate over conventional miniplate, compression plate and reconstruction plates. These advantages include easy application, simplified adaptation to the bone without distortion or displacement of the fracture, simultaneous stabilization at both superior and inferior borders, and hence less operative time.^{7,23}Our study agrees with them, with an average operative time of 41 minute. However, this reduced time cannot be attributed to simplified adaptation. A 3D plate is much broader and requires to be bent in 3 dimensions, whereas a miniplate or DCP has to be bent only in 2 dimensions. Hence, we experienced a difficulty in perfect adaptation of geometric 3D plate. But due to the fact that there is no need to adapt a second plate and less number of screws in interforaminal region definitely saved some time.

Another advantage of 3D plate is their improved biomechanical stability compared to conventional miniplates.⁷ In our study, stability was adequate in most cases except one case. This might be due to difficulty in achieving principles of 3D plate fixation (horizontal bar perpendicular and vertical bar parallel to fracture line³ and using 4-holed rectangular plates where probably the use of 6-holed rectangular plate would have been more beneficial.

The other advantage of using 3D plates in interforaminal region was use of lesser foreign material, as only one plate and four to six screws are used as compared to two plates and eight to twelve screws in case of conventional miniplates. This reduced the overall cost of the treatment. But in other areas of mandible like body and angle hardware used is more if the Champy's principle is adhered to.

Limitations of the present study include small sample size and bite force evaluation was not done.

CONCLUSION

In conclusion, our study showed 3D plate can be used effectively in interforaminal region whenever

indicated. The system is reliable and effective treatment modality for mandibular fractures. Further, the use of 3D plating system in various procedures of maxillofacial region needs to be explored.

REFERENCES

1. Champy M, Lodde JP, Schmitt R, Jarger JH, Muster D. Mandibular osteosynthesis by miniature screwed plates via a buccal approach. *J Maxillofac Surg.* 1978; 6(14):14-21.PMID: 274501
2. Farmand M, Dupoirieux L. The value of 3-dimensional plates in maxillofacial surgery. *Rev Stomatol Chir Maxillofac.* 1992; 93(6):353-357.PMID: 1475603
3. Jain MK, Manjunath KS, Bhagwan BK, Shah DK. Comparison of 3-Dimensional and Standard Miniplate Fixation in the Management of Mandibular Fractures. *J Oral Maxillofac Surg.* 2010; 68:1568-1572.[https://doi: 10.1016/j.joms.2009.07.083](https://doi.org/10.1016/j.joms.2009.07.083)
4. Piffkò J, Homann Ch, Schuon R, Joos U, Meyer U. Experimental study on the biomechanical stability of different internal fixators for use in the mandible. *Mund Kiefer Gesichtschir.* 2003; 7(1):1-6.[https://doi: 10.1007/s10006-002-0429-9](https://doi.org/10.1007/s10006-002-0429-9)
5. Feledy J, Catterson EJ, Steger S, Stal S, Hollier L. Treatment of mandibular angle fractures with a matrix miniplate. A preliminary report. *Plast Reconstr Surg.* 2004; 114(7):1711-1716.[https://doi: 10.1097/01.PRS.0000142477.77232.F7](https://doi.org/10.1097/01.PRS.0000142477.77232.F7)
6. Wittenberg JM, Mukherjee DP, Smith BR, Kruse RN. Biomechanical evaluation of new fixation devices for mandibular angle fractures. *Int J Oral Maxillofac Surg.* 1997;26:68-73.PMID: 9081259
7. Wusiman P, Taxifulati D, Weidong L, Moming A. Three-dimensional versus standard miniplate, lag screws versus miniplates, locking plate versus non-locking miniplates:Management of mandibular fractures, a systematic review and meta-analysis. *Journal of Dental Sciences.* 2019; 14:66-80.<https://doi.org/10.1016/j.jds.2018.04.004>
8. Malhotra K, Sharma A, Giraddi G, Shahi AK. Versatility of Titanium 3D Plate in Comparison with Conventional

- Titanium Miniplate Fixation for the Management of Mandibular Fracture. *J Maxillofac Oral Surg*. 2012;11(3):284-90. [https://doi: 10.1007/s12663-012-0340-3](https://doi.org/10.1007/s12663-012-0340-3)
9. Vineeth K, Lalitha RM, Prasad K, Ranganath K, Shwetha V, Singh J. "A comparative evaluation between single noncompression titanium miniplate and three dimensional titanium miniplate in treatment of mandibular angle fracture" - A randomized prospective study. *Journal of Cranio-Maxillo-Facial Surgery*. 2013; 41:103-109. [https://doi: 10.1016/j.jcms.2012.05.015](https://doi.org/10.1016/j.jcms.2012.05.015)
 10. Collins CP, Pirinjian G, Tolas A. A prospective randomized clinical trial comparing 2.0mm locking plates to 2.0mm standard plates in treatment of mandible fractures. *J Oral Maxillofac Surg*. 2004; 62:1392-1395. [https://doi:10.1016/j.joms.2004.04.020](https://doi.org/10.1016/j.joms.2004.04.020)
 11. Mukerji R, Mukerji G, McGurk M. Mandibular fractures: Historical perspective. *British Journal of Oral and Maxillofacial Surgery*. 2006; 44:222-228. <https://doi.org/10.1016/j.bjoms.2005.06.023>
 12. Motamedi MHK. An assessment of maxillofacial fractures: A 5 year study of 237 patients. *J Oral Maxillofacial Surgery*. 2003; 61:61-64. <https://doi.org/10.1016/j.bjoms.2005.06.023>
 13. Tuovinen V, Norholt SE, Pedersen SS, Jensen J. A retrospective analysis of 279 patients with isolated mandibular fractures treated with titanium miniplates. *J Oral Maxillofac Surg*. 1994; 52:931-935. PMID: 8064456
 14. Saikrishna D, Shetty SK, Marimallappa TR. A comparison between 2.0-mm standard and 2.0-mm locking miniplates in the management of mandibular fractures. *J Maxillofac Oral Surg*. 2009; 8(2):145-149. [https://doi: 10.1007/s12663-009-0036-5](https://doi.org/10.1007/s12663-009-0036-5)
 15. Bormann KH, Wild S, Gellrich NC, Kokemüller H, Stühmer C, Schmelzeisen Retal. Five-Year Retrospective Study of Mandibular Fractures in Freiburg, Germany: Incidence, Etiology, Treatment, and Complications. *J Oral Maxillofac Surg*. 2009; 67:1251-1255. [https://doi: 10.1016/j.joms.2008.09.022](https://doi.org/10.1016/j.joms.2008.09.022)
 16. Smith BM, Deshmukh AM, Barber HD, Raymond J Fonseca: Mandibular Fractures. In: *Oral and Maxillofacial trauma*. 4th edn. Edited by Fonseca RJ, Walker RV, Barber HD, Powers MP, Frost DE. Philadelphia: W.B.Saunders company. 2013; 293-330. ISBN: 978-1-4557-0554-2
 17. Jaques B, Richter M, Arza A: Treatment of Mandibular Fractures With Rigid Osteosynthesis: Using the AO System. *J Oral Maxillofac Surg* 1997; 55:1402-1406. PMID: 9393399
 18. Haskel R: Applied Surgical Anatomy. In: *Maxillofacial Injuries*. 1st edn. Edited by Williams JL, Rowe NL; 1985; 1-42. ISBN-10: 0443015090
 19. Renton TF, Wiesenfeld D. Mandibular fracture osteosynthesis: a comparison of three techniques. *British journal of oral and maxillofacial surgery*. 1996; 34:166-173. [https://doi.org/10.1016/S0266-4356\(96\)90372-1](https://doi.org/10.1016/S0266-4356(96)90372-1)
 20. Bolourian R, Lazow S, Berger J. Transoral 2.0-mm Miniplate Fixation of Mandibular Fractures Plus 2 Weeks Maxillomandibular Fixation: A Prospective Study. *J Oral Maxillofac Surg*. 2002; 60:167-170. [https://doi:10.1053/joms.2002.29813](https://doi.org/10.1053/joms.2002.29813)
 21. Siddiqui A, Markose G, Moosc KF, McMahond J, Ayoub AF. One miniplate versus two in the management of mandibular angle fractures: A prospective randomised study. *British Journal of Oral and Maxillofacial Surgery*. 2007; 45:223-225. [https://doi: 10.1016/j.bjoms.2006.08.016](https://doi.org/10.1016/j.bjoms.2006.08.016)
 22. Potter J, Ellis EIII. Treatment of Mandibular Angle Fractures with a Malleable Noncompression Miniplate. *J Oral Maxillofac Surg*. 1999; 57:288-292. PMID: 10077199
 23. Wusiman P, Yarbog A, Wurouzi G, Mijiti A, Moming A. Three dimensional versus standard miniplate fixation in management of mandibular fractures: A systematic review and meta-analysis *Journal of Cranio-Maxillo-Facial Surgery*. 2016; 44:1646-1654. [https://doi: 10.1016/j.jcms.2016.07.027](https://doi.org/10.1016/j.jcms.2016.07.027)
 24. Guimond C, Johnson JV, Marchena JM. Fixation of Mandibular Angle Fractures With a 2.0-mm 3-Dimensional Curved Angle Strut Plate. *J Oral Maxillofac Surg*. 2005. 63:209-214. [https://doi: 10.1016/j.joms.2004.03.018](https://doi.org/10.1016/j.joms.2004.03.018)