

## CASE REPORTS

### PANCREATICOPLEURAL FISTULA: A CASE REPORT

Bikas Thapa<sup>1</sup>, Nirajan Subedi<sup>1</sup>, Ramesh S Bhandari<sup>1</sup>

<sup>1</sup>Department of GI Surgery, TUTH, Kathmandu, Nepal

\*Correspondence to: Ramesh S Bhandari, Department of GI Surgery, TUTH, Kathmandu, Nepal.

Email: [rsbhandari09@gmail.com](mailto:rsbhandari09@gmail.com)

#### ABSTRACT

Pancreaticopleural fistula is a diagnostic challenge to physicians. The diagnosis should be suspected if a patient presents with pleural effusion in a setting of chronic pancreatitis. The significantly raised amylase in the pleural fluid offers an important clue to the diagnosis. Computed Tomography (CT), Endoscopic retrograde cholangiopancreatography (ERCP) and Magnetic resonance cholangiopancreatography (MRCP) can reveal the fistulous tract between the pancreas and the pleural space. The therapeutic options include medical, endoscopic, as well as surgical interventions. Here we report a case of pancreaticopleural fistula in a chronic alcoholic that was treated successfully by medical management.

**Key words:** Chronic pancreatitis, Pancreaticopleural fistula (PPF)

#### INTRODUCTION

Pancreaticopleural fistula (PPF) is an unusual complication of pancreatitis with an incidence of 0.4% of patients<sup>1</sup>, and is most commonly associated with chronic alcoholic pancreatitis.<sup>2</sup> PPF results from a disruption of the pancreatic duct (PD), resulting in leakage of pancreatic fluid.<sup>3</sup> The symptoms are usually pulmonary and presents as a pleural effusion, which is usually massive recurrent and exudative in nature. One can suspect the presence of this pathology when there is a high level of amylase in the pleural fluid analysis, or when the imaging work up reveals a fistulous tract between the pancreas and the pleural space. Although it is more common in left side, right effusion can also occur as in this case.

#### Case presentation

A 52 years man with a history of alcohol abuse presented with dyspnoea for 2 weeks, without fever or cough. Physical examination revealed reduced right basal breath sounds and a chest X-ray showed massive right pleural effusion. (figure 1)

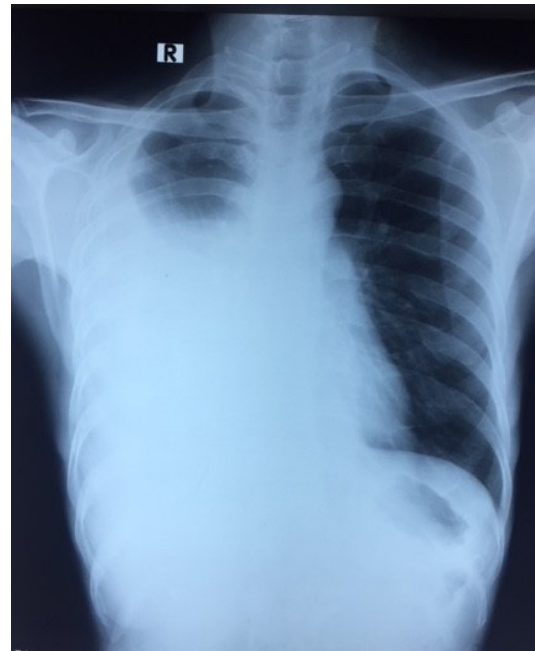


Figure 1: chest-x ray showing rt sided pleural effusion

Blood tests revealed a normal white cell count.

Diagnostic thoracentesis was performed yielding pleural fluid with an exudative pattern with negative microbiology and cytology. However no obvious cause of effusion was found. History of alcohol abuse and recurrent pain abdomen led to suspicion of pancreatitis as a cause of effusion so pleural fluid amylase and lipase were sent. A raised pleural fluid amylase level of 14352 U/L and lipase level of 25350 U/L confirmed the diagnosis. CECT abdomen and thorax showed features of chronic pancreatitis with right pleural effusion, however fistulous tract could not be traced. The patient was initially managed conservatively with chest drainage, and octreotide administration (100 µg three times a day) for 10 days. Following medical treatment, there was clinical improvement as evident by full lung expansion on subsequent chest x-ray (figure 2).

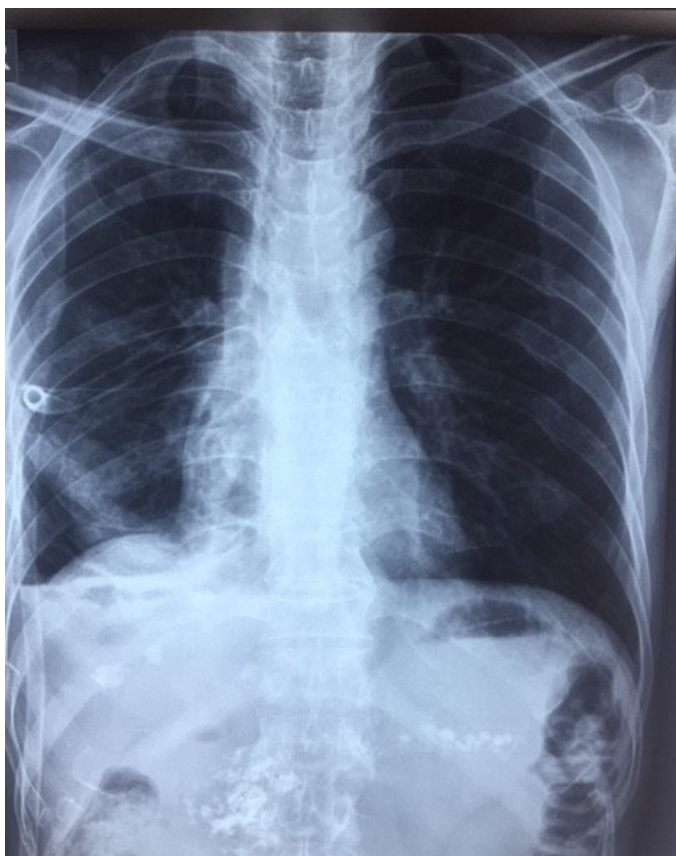


Figure 2: chest x-ray shows expanded lung with ICD in situ and calcification in pancreatic area

On follow up, (MRCP) was done which revealed markedly dilated pancreatic duct with dilatation of branch duct with atrophic pancreas with intraductal calculi, however no evidence of fistulous tract was seen (figure 3). The patient is on regular follow up and doing well. Repeat chest x ray showed lung

expansion. The patient has been planned for Frey's procedure on elective basis.

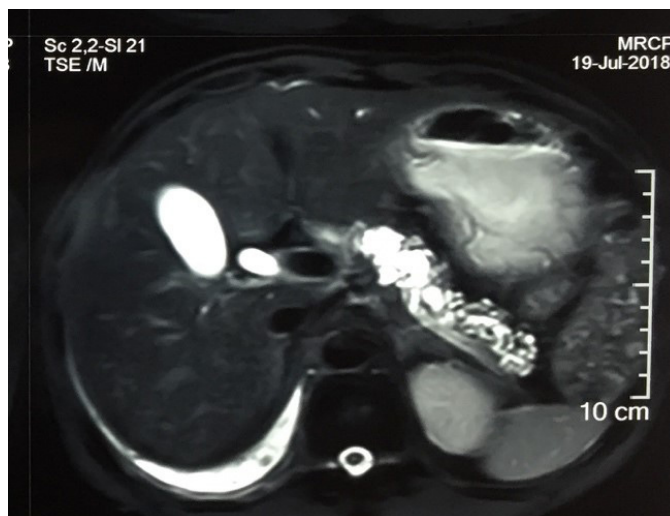


Figure 3: MRCP showing dilated MPD and branching ducts

## DISCUSSION

PPF is an uncommon complication with incidence of 0.4%.<sup>1</sup> It results from a leak of the pancreatic duct which dissect through the aortic or the oesophageal hiatus to the mediastinum, resulting in pleural effusion.<sup>3</sup> It is most common in pancreatitis related to alcohol abuse<sup>2</sup> The patients usually present with predominant pulmonary symptoms, such as dyspnoea (the most common symptom), chest pain or cough,<sup>3</sup> and paucity of symptoms related to pancreatic disease which can result in a delay in the diagnosis. Pleural effusion is more frequently left sided and usually large and exudative; however, right and bilateral effusions can also occur, as in this case.<sup>2</sup> A large and recurrent pleural effusion, despite repeated thoracentesis in a patient with history of pancreatitis, should raise suspicion of a PPF.<sup>4</sup> Although there is no established diagnostic threshold for amylase pleural fluid, but usually it is considerably elevated (>1000 U/L).<sup>5</sup> Imaging with CT and MRCP can reveal the fistulous tract between the pancreas and the pleural space. MRCP is the imaging study of choice for PPF as it enables better characterization of the fistulous tract due to its enhanced sensitivity compared to CT.<sup>2</sup> The management of PPF can be medical, endoscopic or surgical. The choice of treatment must consider the PD anatomy. Thus, in the presence of a normal or mildly dilated duct without stenosis, a medical approach is recommended, with chest drainage,

octreotide administration (to suppress pancreatic exocrine function) and total parenteral nutrition, for 2–3 weeks.<sup>5</sup> 30-60% of patients can be managed successfully this way.<sup>1,2</sup> Failure of medical treatment is an indication for endoscopic or surgical treatment. If there is a ductal stenosis downstream to a disruption, an endoscopic treatment must be attempted by placing a stent.<sup>5</sup> Surgery is recommended in those cases with complete ductal obstruction or if stenting is not feasible.<sup>5</sup> Distal pancreatectomy and pancreaticojejunostomy are the most common surgical procedures reported.

## REFERENCES

1. Rockey DC, et al. Pancreaticopleural fistula. Report of 7 patients and review of literature. *Medicine (Baltimore)*. 1990;69(6):332-44.
2. Tauseef A, et al. Pancreaticopleural fistula. *Pancreas* 2009;38(1):e26-31.
3. Dhebri AR, et al . Nonsurgical management of pancreaticopleural fistula. *JOP*. 2005;10(2):152-61
4. Tay CM, et al. Diagnosis and management of pancreaticopleural fistula. *Singapore Med J*. 2013;54(4):190-4.
5. Wronski M, et al. Optimizing management of pancreaticopleural fistulas. *World J Gastroenterology*. 2011;17(42):4696-703.