

**ORIGINAL RESEARCH ARTICLE****EVALUATION OF OCCURRENCE OF SESAMOID BONES IN THE LOWER EXTREMITY RADIOGRAPHS**Indu Ghimire¹, Surendra Maharjan^{2*}, Ganesh Bahadur Pokharel³, Kamal Subedi⁴¹ Radiographer, Tribhuvan University Teaching Hospital² Lecturer, National Academy of Medical Science, Bir Hospital, Kathmandu³ Professor, National Academy of Medical Science⁴ Lecturer, Tribhuvan University Teaching Hospital, Kathmandu**Correspondence to: Dr. Surendra Maharjan, National Academy of Medical Science, Bir Hospital, Kathmandu. e-mail: suren634634@gmail.com***ABSTRACT**

The purpose of this study was to examine the plain AP radiograph of foot and lateral radiograph of knee in order to determine the prevalence and size of sesamoid bone in different part of foot and on the posterior aspect of the knee joint. A cross-sectional study was performed in Department of Radiology and Imaging, Tribhuvan University Teaching Hospital from July to September 2014. A total of 206 radiographs of foot (55) and knee (155) were collected. 121 (58.7%) were female and 85 (41.3%) were male. The most common site of sesamoid bone in foot was in the first metatarsal joint (96.4%) whereas the sesamoid bone in knee joint, fabella was found in 12.3% of total cases. The prevalence is more common in female than in male. The length and breadth of the sesamoid bones were measured and then area of bones was calculated. The size of medial and lateral sesamoid bone in the first MTP Joint was measured 0.6225 cm² and 0.8261 cm² respectively. The mean size of sesamoid bone of knee, fabella was 0.2818 cm².

Key words: Foot, Knee joint, Radiography, Sesamoid bone.

INTRODUCTION

Sesamoid bones are small, round or oval shaped nodules that are embedded within certain tendons.¹ Sesamoid bones are similar to the flat oval seed of *Sesamum Indicum* in shape and size, an ancient East Indian plant used by Greeks.¹ They are typically found in locations where a tendon passes over a joint, such as hand, wrist, knee, and foot.¹ They act to protect the tendon and to increase its mechanical effect by holding the tendon. Certain sesamoid bones are invariably present in all individuals like patella. The sesamoid bones of the great toe which are small and may appear as insignificant bones can be the site of disabling pathology. Any structural abnormality in them can cause discomfort in gait and hence the increased interest in their study.² When the symptoms arise, the pathologic conditions of these bones can be overlooked and the patients are diagnosed. There may be two or more ossification centers, these may or may not coalesce. Thus, bi, tri and even quadripartite sesamoid may be present

in the adult. The partition is the relatively common finding in the first MTP Joint.¹

Most accessory ossicles and sesamoid bones of the ankle and feet remain asymptomatic but can cause painful symptoms and as a result there has been an increase interest in their study. The clinical importance of the sesamoid bone is due to the great deal of fore foot pain that arises from damage due to trauma and sport.³ Muscular dysfunction has also been associated with the sesamoids. The sesamoids of the first MTP Joint are most important and constant sesamoid of the foot.

The purpose of this study was to examine the plain AP radiograph of foot and lateral radiograph of knee in order to determine the prevalence and size of sesamoid bone in different part of foot and on the posterior aspect of the knee. In foot, the sesamoid bones were found on the plantar surface of the

joints. Two sesamoid bones are almost constant at the first meta-tarsophalangeal joint. Among these two the medial is larger. Occasionally sesamoid bones are also found in other metatarsophalangeal joint, interphalangeal joint and intertarsal joint of the foot.

METHODOLOGY

It was a cross-sectional study including patients presented for radiograph of foot and knee in Department of Radiology and Imaging from July to September 2014. A total of 206 samples were collected for the study. The foot AP and knee lateral radiographs were collected from the CR reader (AGFA). The preponderance of sesamoid bones was evaluated. The length and breadth of the sesamoid bones were measured using the computer software present in the AGFA CR reader 30X and then area of bones was calculated. Proforma was prepared to evaluate the occurrence of sesamoid bones on the lower extremity radiographs of patients. The results were analysed and correlated using SPSS version 20. Admitted patients in ward, emergency patients, portable radiographs and non-nepalese population were excluded from the study.

Results

Out of 206 cases, 55 cases of foot radiographs and 155 cases of knee radiographs were studied. Among them 121(58.7%) were female and 85 (41.3%) were male. In foot radiograph, the prevalence of sesamoid bone in the first MTP joint (the most common location of sesamoid bones in foot) was found to be 96.4% cases. At this joint, single sesamoid bone was found in 3.6%, a pair of sesamoid bone in 90.9% and three in 5.45% cases. The percentage of occurrence of sesamoid bones in male and female was also different. In female, occurrence was found to be 100% and in male, it was 93.1%. In knee radiograph, the prevalence of a sesamoid bone called fabella was found to be 12.3% of the total cases. However, the prevalence was higher in female i.e.14.7% than in male (8.2%) (See figure 1 below).

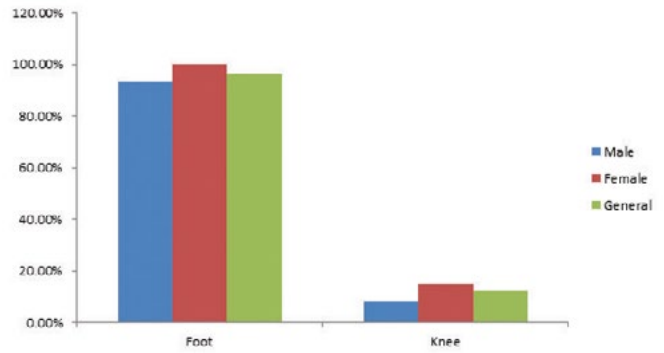


Figure 1: Showing the occurrence of sesamoid bones Among the other least occurring sesamoid bones in the foot, Os peroneum was found in 5.45%, sesamoid bone at first IPJ was found in 3.6%, os-tibial externum in 1.8%, at fourth meta-tarsal head in 1.8% and at third meta-tarsal head in 1.8% cases (See table 1 below).

Table 1: The mean size of different sesamoid bones at first MTP Joint

	Medial	Lateral	Fabella
No of bones	52	51	19
Maximum size	1.17 cm ²	8.0 cm ²	0.78 cm ²
Minimum size	0.19 cm ²	0.24 cm ²	0.07 cm ²
Mean size	0.6225 cm ²	0.8261 cm ²	0.2818 cm ²
Standard deviation	0.2265	1.04679	0.17214

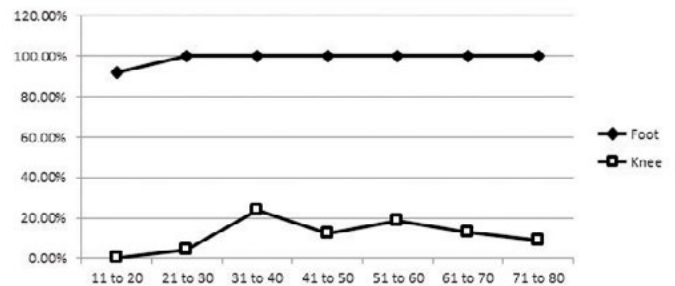


Figure 2: Line diagram showing the percentage occurrence of sesamoid bone in different age group.

In this study, the sizes of the sesamoid bones were also measured. The size of medial and lateral sesamoid bone in the first MTP Joint were measured and mean size of medial and lateral was found to be 0.6225 cm² with SD of 0.2265 and 0.8261 cm² with SD of 1.04679 respectively. The mean size of sesamoid bone of knee, fabella was 0.2818 cm² with SD of 0.17214.

The correlation between size of sesamoid bones and

age was analysed. It showed the correlation between third sesamoid bone at the first MTP joint and age is significant at the 0.05 level of significance ($p < 0.05$) whereas the correlation between other sesamoid bones and age is insignificant at 0.05 level ($p > 0.05$).

DISCUSSION

The study was done to ascertain the prevalence of sesamoid bone in the foot and knee using radiographs. The result obtained showed that the sesamoid bone of first meta-tarsophalangeal joint of foot was most common accounting for the prevalence of 93.1% in male and 100% in female (96.4% of the total population). This value was higher than an early study done on the Nigerians population whose value of prevalence was 81.5%.³ The result obtained in this study was lower on comparing with another study done by Yammine K., who found 100% prevalence.⁴ In the study done by Masaki in 1984, the occurrence in first meta-tarsophalangeal joint was 90.9% amongst the Japanese.⁵ However, Goldberg and Nathan in 1987 recorded 100% occurrence of sesamoid bones for Japanese.⁶ In Africa, Msamati and Igbigbi recorded the 100% occurrence in first meta-tarso phalangeal joint in 2001.⁷ So the result obtained in present study was closely related to the results obtained in those researches.

The result obtained in this study showed that the prevalence of sesamoid bone at IP joint is 3.6% but it was found to be 22.4% in a study done by Yammine K.⁸ The prevalence of sesamoid bone at IP joint in this study was somewhat low. The respective percentages of occurrence of sesamoid bones at the MTP joint of 2nd, 3rd, 4th and 5th toes are 0%, 1.8%, 1.8% and 0% respectively.⁸

This study also recorded the following other rare sesamoid bones among which the most prevalent was Os-peroneum (5.45%) but Os-peroneum (10%) was found in Nigerians population.³ Os-tibiale externum was found in 1.8% of total population in this study which was quite close to the early study done by A.I. Udoaka and B.C. Didia.³ They had a value of 0.3% whereas in Coskun et al study, 2009, accessory ossicles was present in 21.2% and sesamoid bones 9.6%.⁹

The results were correlated with the age and sex of the patient. The results showed that the prevalence

was higher in female than in male in both foot and knee. In foot the prevalence of sesamoid bone was 85.7% in age group of 11-20 years and in all other age groups it was 100%. In knee the highest prevalence (23.5%) was found in age group 31-40 years and lowest (0%) in 11-20 years.

The sizes of sesamoid bones were also measured. The mean size of the lateral sesamoid bone was found to be larger than the medial sesamoid bone at the first metatarsophalangeal joint but the size of the medial sesamoid bone should be larger than lateral sesamoid bone.⁸

The sesamoid is an insignificant bone which is not normally taken care. Different pathological conditions such as stress fractures, turf toe and sesamoiditis may cause various types of problems to the individual. Researches are being done on the percentage of prevalence of sesamoid bones but not in other aspects of them. That is why, further study can be done on effect of various pathological conditions of the sesamoid bones which can cause problems to the individual and correlate them with age, sex, etc. The study can also be done on correlating different problems on foot of the individual with the prevalence of sesamoid bones.

CONCLUSION

The most common and almost constant sesamoid bone in the foot is at the first MTP joint. However, the prevalence is more common in female than in male. At this joint, some individuals had one, some others had two and remaining others had three sesamoid bones. Most of them had two sesamoid bones at first MTP joint. Some individuals also possessed a small sesamoid bone called fabella posterior to the knee joint. The mean size of medial sesamoid bone present at the first MTP joint is smaller than the lateral one in Nepalese population.

REFERENCES

1. Kose, O., Guler, F., Turan, A., Ecanbora, K., & Akalin, S. (2012). Prevalence and distribution of sesamoid bones of the hand. A radiographic study in Turkish subjects. *Int. J. Morphol*, 30(3), 1094-9.
2. Frankel, J. P., & Harrington, J. (1990). Symptomatic bipartite sesamoids. *J Foot Surg*, 29(4), 318-323.
3. Udoaka, A. I., & Didia, B. C. (2013). Prevalence and types of accessory ossicles and sesamoid bones of the feet of adult southern Nigerians. *Res J Med Sci*, 7, 25-27.
4. Yammine, K. (2014). The sesamoids of the feet in humans: a systematic review and meta-analysis. *Anatomical science international*, 90(3), 144-160.
5. Masaki, T. (1984). [An anatomical study of the interphalangeal sesamoid bone of the hallux]. *Nihon Seikeigeka Gakkai Zasshi*, 58(4), 419-427.
6. Goldberg, I., & Nathan, H. (1987). Anatomy and pathology of the sesamoid bones. *International orthopaedics*, 11(2), 141-147.
7. Msamati, B., & Igbigbi, P. (2001). Radiographic appearance of sesamoid bones in the hands and feet of Malawian subjects. *Clin. Anat.*, 14(4), 248-253. doi:10.1002/ca.1042
8. Yammine, K. (2014). The prevalence of the sesamoid bones of the hand: A systematic review and meta-analysis. *Clinical Anatomy*, 27(8), 1291-1303.
9. Coskun, N., Yuksel, M., Cevener, M., Arican, R. Y., Ozdemir, H., Bircan, O., ... & Sindel, M. (2009). Incidence of accessory ossicles and sesamoid bones in the feet: a radiographic study of the Turkish subjects. *Surgical and radiologic anatomy*, 31(1), 19-24.