



## CASE REPORT

## RETROGRADE INTUBATION IN A CASE OF CANCRUM ORIS WITH SYGNATHIA

GP Deo<sup>1\*</sup>, SK Shrestha<sup>1</sup>, S Neupane<sup>1</sup>, H Ojha<sup>1</sup>, IN Shrestha<sup>1</sup>, BS Regmi<sup>1</sup>, S Subedi<sup>2</sup><sup>1</sup> Department of Anaesthesiology & Critical Care, Chitwan Medical College, Bharatpur, Chitwan, Nepal.<sup>2</sup> Department of OMFS, College of Dental Sciences, Chitwan Medical College, Bharatpur, Chitwan, Nepal.**\*Correspondence to:** Dr. Gopendra Prasad Deo, Department of Anaesthesiology & Critical Care, Chitwan Medical College, Bharatpur, Chitwan, Nepal.Email: [gopendradeo@gmail.com](mailto:gopendradeo@gmail.com)

## ABSTRACT

Difficult intubating conditions, anticipated or unanticipated, are part of every anaesthetist's life. A large number of aids and various techniques have been described for intubating in such situations. The primary job of the anesthesiologist is to secure the airway and provide adequate ventilation to the anesthetized patient. Failure to manage difficult airway has led to many of the total deaths attributable to anesthesia. Proper airway examination and selection of appropriate method for airway intervention is of utmost importance. The retrograde intubation technique is one of the valuable alternative options in places where fiberoptic bronchoscope is not readily available or affordable in cases with anticipated difficult airway. We report a case of cancrum oris with sygnathia (fusion of jaw) leading to inability to open mouth posted for bilateral coronoidectomy with osteotomy of fused bone and lip repair. An awake retrograde nasal intubation with light sedation and local block was performed.

**Key words:** *Cancrum oris, Fiberoptic bronchoscope, Retrograde intubation.*

## INTRODUCTION

The curved laryngoscope blade described by Macintosh in 1943 is the most popular device used to facilitate orotracheal/ nasotracheal intubation but there is always risk of trauma and failed intubation<sup>1</sup>. Recently the use of video technology to facilitate intubation is gaining importance. In several studies involving manikins and humans, video laryngoscopes in comparison to the conventional Macintosh blade has been found to improve the visualization of vocal cords (Cormack and Lehane Grading) during oral and nasotracheal intubation in normal as well as in difficult airway scenarios<sup>2-7</sup>. As a result, it is increasingly being used in management of difficult airway these days. Although awake fibre optic intubation has been considered as the gold standard for managing difficult airways, its absence in many institutes due to high cost has led to the use of various other methods to handle difficult airways. The other methods may include blind nasal intubation or retrograde intubation or surgical

airways. Each method has its own advantages and limitations. We present a case of a patient diagnosed as cancrum oris with inability to open mouth who was intubated uneventfully using retrograde nasal intubation technique.

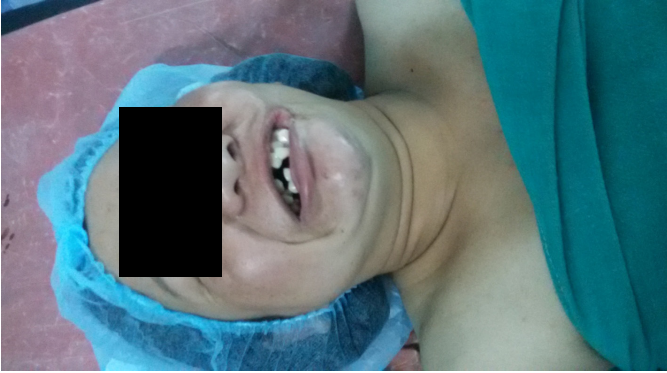## CASE HISTORY

A 18 year old female, ASA-I, weight 48kg, height 148cm was admitted to our hospital with history of inability to open mouth which was progressing to present state since birth. She was a non-tobacco chewer, had a BMI of 21.9 kg/m<sup>2</sup>. She did not have any other significant medical or family history. She had undergone surgery twice for the same cause. Her pulse rate was 70bpm/regular and blood pressure was 104/70 mm of Hg.

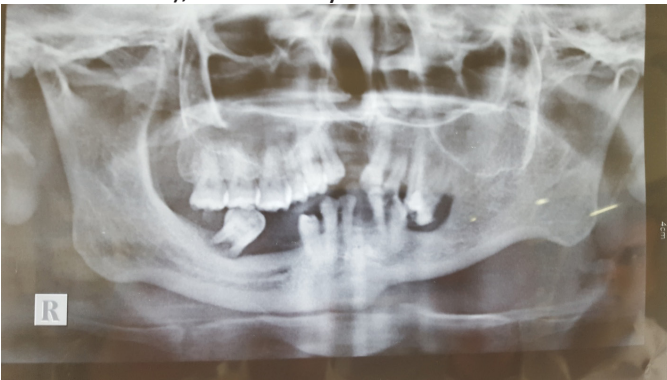**Airway examination:** Airway examination showed no mouth opening but neck movements were

adequate. Thyromental distance was >6 cm and both nostrils were patent.

She was diagnosed to have cancrum oris with sygnathia (fusion of mandible and maxilla) and was posted for bilateral coronoidectomy with osteotomy of fused bone and lip repair.



**INVESTIGATIONS:** Hb- 13.1gm/dl, TC- 5600/ cu. mm, Platelet Count- 320000/ cu. mm, RBS- 107mg/dl, Blood Urea/Creatinine/Electrolytes-WNL (within normal limits), Chest X ray and ECG – WNL.



Securing the airway is the primary goal in such patients. Our options were blind nasal intubation, retrograde intubation, fiberoptic nasal awake intubation, surgical or percutaneous tracheostomy. Retrograde intubation was our first preference, as blind nasal would have been traumatic and fiberoptic intubation would need experience hands and costly equipment.

The risks and possibility of tracheostomy were explained to the patient and relatives. Informed consent was taken for the procedure and photography.

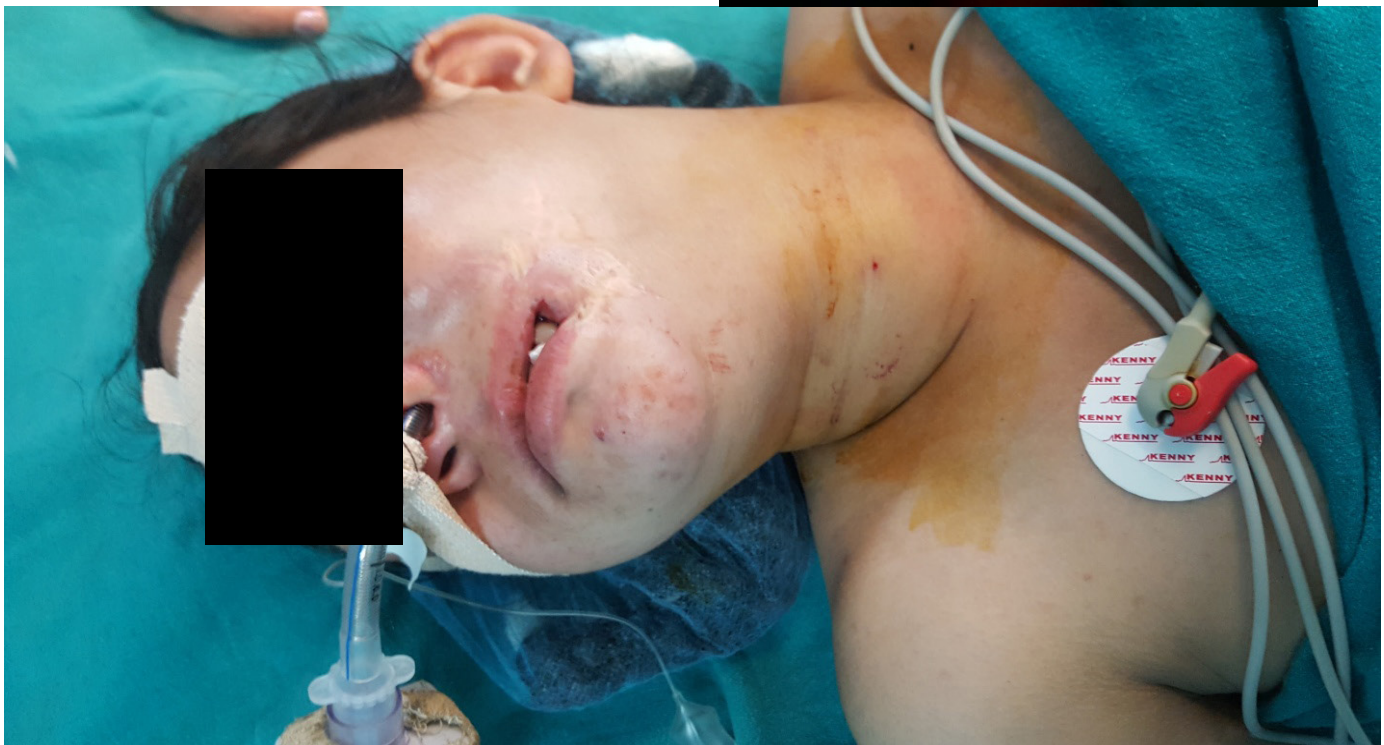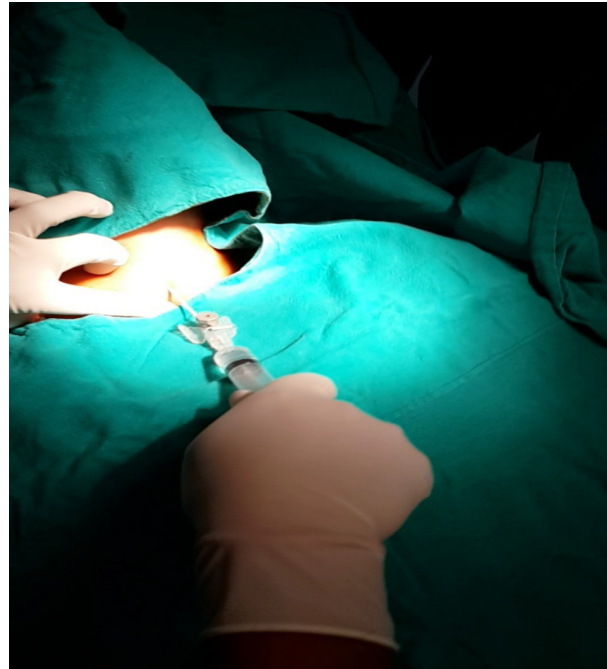
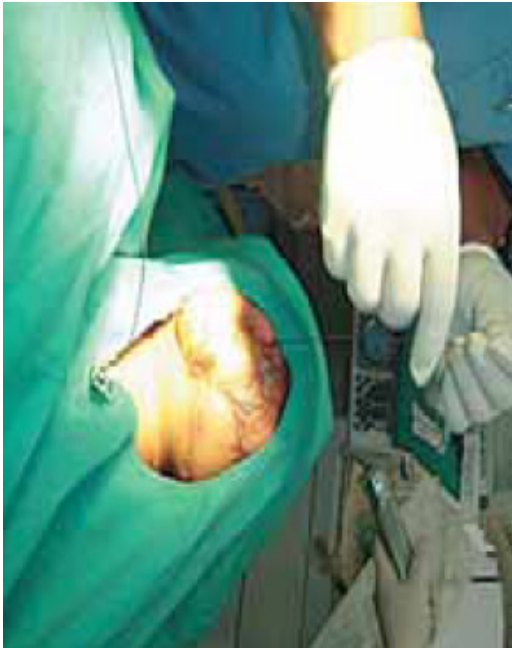**PREMEDICATION :** Intravenous access was achieved via 18G cannula in the wrist of right upper limb. Routine monitors were attached which included ECG,

NIBP and pulse oximeter. Patient was premedicated with Inj. glycopyrrolate 0.2mg iv and Inj. Midazolam 2mg. Nasal decongestant Xylometazoline 0.1 % was instilled in both the nostrils. Lidocaine 10% spray was also applied. Preoxygenation was done for 3 mins. All the emergency drugs, nasopharyngeal airway and tracheostomy kit were kept ready. An ENT surgeon was also stand by for emergency tracheostomy.

Under all aseptic precautions, superior laryngeal block was administered with 2.5 ml of 2% lidocaine after negative aspiration for blood on both sides, and transtracheal infiltration was done with 1.5 ml of 2% lidocaine. After local anesthesia, 16 G IV cannula was passed cranially via the cricothyroid membrane, position confirmed with by air aspiration in a saline filled syringe. Guidewire of Central Venous Catheter was passed through the cannula and the guidewire was retrieved through the left nostril. After that, cuffed ET tube of internal diameter 6.5mm was passed over the guide wire which could not be negotiated through larynx. So neck extension was given. The ET tube was further progressed and patient was intubated. Tube position was also confirmed by capnography. Bilateral air entry was equal. Induction of GA was done with 80mg propofol and 5mg vecuronium. Anaesthesia was maintained with isoflurane and vecuronium. Analgesia was supplemented with repeat doses of fentanyl. Patient tolerated the surgery well, and was haemodynamically stable in peri-operative period. At the end of surgery, 16 Fz NG tube was inserted. After that, patient was reversed and extubated uneventfully.

## DISCUSSION

Cancrum oris, also known as noma, is an opportunistic infection common in people of low socio-economic status. Though it is most common in sub-Saharan Africa, it has been seen in different parts of the world. The peak incidence of acute noma is at ages 1–4 years, coinciding with the period of linear growth. It evolves rapidly from a gingival inflammation to orofacial gangrene. It is commonly preceded by measles, malaria, severe diarrhoea, and necrotising ulcerative gingivitis. The acute stage responds readily to antibiotic treatment. After healing, there may be various functional and aesthetic impairments, which



require reconstructive surgery.

It is always a challenge to secure an airway in such patients. The available options for airway

management in these patients are limited due to the inability to use the oral route for intubation. Therefore, we were left with a few options for airway management, namely blind nasal intubation, retrograde intubation, fibre-optic intubation, surgical or percutaneous tracheostomy. One of

our options was blind nasal intubation, but failure of blind nasal intubation is very common<sup>8,9</sup> and there is risk of an increased trauma with repeated attempts, precipitating complete airway obstruction that necessitates emergency surgical airway, so it was not selected. LMA was not possible to insert in our case due to limitation of the mouth opening. Tracheostomy would have been a better option to secure the airway if multistage reconstructive surgery was planned, with challenges of a difficult

airway each time. However tracheostomy was not performed because it was a single staged surgery. Tracheostomy also carries many risks particularly in the absence of a tracheal tube. Awake fiberoptic intubation is considered the safest and most effective method in known or suspected cases of difficult airway but is technically demanding, though it was unavailable in our institute. Retrograde intubation was originally described by Waters in the early 1960s<sup>10</sup>. RI is an invasive technique that uses the Seldinger technique by way of the cricothyroid membrane to achieve intubation. This technique is recommended as an alternative in situations where the visibility of the trachea is obstructed by blood, secretions or anatomical deformities and direct laryngoscopy and fiberoptic intubation attempts are unsuccessful<sup>11</sup>. We used the central venous catheter because it is cheaper and easy to use. Several problems have been reported with retrograde intubation. Failed intubation is very common caused by the tracheal tube springing into the oesophagus after the removal of guide wire<sup>12</sup>. There are various complications associated with retrograde intubation which includes trauma to the larynx from the introduction of the needle or wire, bleeding, haematoma, inadvertent puncture of oesophagus, subcutaneous emphysema, pneumomediastinum, and infection<sup>12</sup>. Contraindications for retrograde intubation include unfavourable anatomy in the area of the cricothyroid laryngotracheal pathologic conditions, significant coagulopathy, and infection<sup>13</sup>.

In spite of all the limitations, various studies have shown its significance in specific situations such as blood and secretions in the airway, trismus, congenital anomalies, limited mouth opening, and bone and joint disorders such as rheumatoid arthritis, ankylosing spondylitis, airway tumours or failed intubation with the direct laryngoscopic technique. Retrograde intubation can be used even when blood and secretions are present in the upper airway where fiberoptic bronchoscope has limited use<sup>14</sup>. Besides it has shorter procedural duration and a lower risk of subglottic oedema and stenosis than fiberoptic bronchoscope<sup>15</sup>. On the other hand, retrograde intubation is less invasive than needle cricothyrotomy and surgical cricothyrotomy so it can be a useful alternative when the intubation or ventilation scenarios are not possible. However the

success rate of retrograde intubation is variable<sup>16</sup>. Some authors claim that those who use the technique frequently, retrograde intubation has a higher success rate<sup>17</sup>. Harris et al. expressed belief that training in retrograde intubation could increase the success rate of the technique and simultaneously decrease the complications associated with it<sup>18</sup>. However, the success of retrograde intubation and other intubation techniques when performed with the patient who is awake depends on the patient's collaboration. Considering all the circumstances, we decided to secure airway in our patient with retrograde intubation via cricothyroid membrane with sedation.

## CONCLUSION

As in our case, in the absence of fiberoptic bronchoscope, retrograde intubation may be good alternative to invasive airway management such as surgical tracheostomy for difficult intubations because it is safe, simple and effective technique. Death from loss of airway still occurs in patients with difficult airway. We could successfully manage this case of difficult airway with awake nasal retrograde intubation under sedation.

## Ethical Clearance:

1. The contents have not been published elsewhere and the paper is not being submitted elsewhere.
2. The manuscript has been read and approved by all co-authors.
3. Patient consent has been taken for publishing the case and pictures related to it.
4. No financial interests, direct or indirect, exist for individual contributors in connection with the content of this paper.
5. No sources of outside support of the project.

## REFERENCES

1. Macintosh RR. A new laryngoscope. *Lancet* 1943; 1:205.
2. Sansone P, Stumbo R, Arienzo S, Passavanti MB, Pace MC, Aurilio C. Airtraq laryngoscopes in patients with facial trauma. *Eur J Anaesthesiol.* 2012; 29:229.
3. Jones PM, Armstrong KP, Armstrong PM, Cherry RA, Harle CC, Hoogstra J et al. A Comparison of Glides-

- cope videolaryngoscopy to direct laryngoscopy for nasotracheal intubation. *Anaesth Analg*. 2008; 107:144-8.
4. Narang AT, Oldeg PF, Medzon R, Mahmood AR, Spector JA, Robinett DA. Comparison of intubation success of video laryngoscopy versus direct laryngoscopy in the difficult airway using high-fidelity simulation. *Simul Healthc*. 2009; 4:160-5.
  5. MA, Maharaj CH, Harte BH, Laffey JG. Comparison of Macintosh, Truview EVO2(R), Glidescope Malik (R), and Airway scope (R) laryngoscope use in patients with cervical spine immobilization. *Br J Anaesth* 2008;101:723-730.
  6. Leung YY, Hung CT, Tan ST. Evaluation of the new Viewmax laryngoscope in a simulated difficult airway. *Acta Anaesthesiol Scand* 2006; 50: 562-7.
  7. Singh I, Khaund A, Gupta A. Evaluation of Truview Evo2 laryngoscope in anticipated difficult intubation-A comparison to Macintosh laryngoscope. *Indian J Anaesth*. 2009; 53: 164–168.
  8. Borland LM, Swan DM, Leff S. Difficult pediatric endotracheal intubation: A new approach to the retrograde technique. *Anesthesiology* 1981; 55: 577-8.
  9. Arya VK, Dutta A, Chari P, Sharma RK. Difficult retrograde endotracheal intubation: The utility of a pharyngeal loop. *Anesth Analg* 2002; 94:470-3.
  10. Waters DJ. Guided blind endotracheal intubation. *Anaesthesia* 1963; 18: 158-62.
  11. American Society of Anesthesiologists Task Force on Management of the Difficult Airway. Practice guidelines for management of the difficult airway: an updated report by the American Society of Anesthesiologists Task Force on Management of the Difficult Airway. *Anesthesiology*; 2003 May, 98(5):1269-77.
  12. Henderson J. Airway management in the adult. In: Miller RD, Eriksson LI, Fleisher LA, et al., editors. *Miller's anesthesia*. 7th ed. Philadelphia: Elsevier Churchill Livingstone; 2009.p1573–610.
  13. Burbulys D, Kiai K. Retrograde intubation. *Emerg Med Clin North Am*. 2008 Nov;26(4):1029–41.
  14. Tüfek A, Uçan MC, Tokgöz O, Çelik F, Ağaçayak S. Evaluation of retrograde intubation in patients with limited mouth opening. *J Anesth*. 2013 Aug;27(4): 631–2.
  15. Shantha TR. Retrograde intubation using the subcricoid region. *Br J Anaesth*. 1992 Jan;68(1):109–12.
  16. Gill M, Madden MJ, Green SM. Retrograde endotracheal intubation: An investigation of indications, complications, and patient outcomes. *Am J Emerg Med*. 2005 Mar;23(2):123–6.
  17. Orebaugh SL. Retrograde intubation. In: Orebaugh SL, editor. *Atlas of airway management: techniques and tools*. 1st ed. Philadelphia: Lippincott, Williams & Wilkins; 2007.
  18. Harris EA, Arheart KL, Fischler KE. Does the site of anterior tracheal puncture affect the success rate of retrograde intubation? A prospective, manikin-based study. *Anesthesiol Res Pract*. 2013;2013: 354317.