

**CASE REPORT****SOLITARY INTRAMUSCULAR CYSTICERCOSIS: A RARE PSEUDOTUMOUR.
A REPORT OF TWO CASES**
RP Marasini^{1*}, PB Thapa¹, P Gautam¹

¹ Department of Orthopedics and Trauma, Bharatpur Hospital Chitwan, Nepal.

*Correspondence to: *Dr Rudra Prasad Marasini, Department of Orthopedics and Trauma, Bharatpur Hospital, Chitwan, Nepal.*
Email: drmarasinirp@gmail.com

ABSTRACT

Cysticercosis is a disease caused by *cysticercus cellulosae*, a larval form of tapeworm, *Taenia solium*. Solitary muscular involvement is a rare and often presents diagnostic challenges due to unusual clinical presentation. Conventionally these conditions are diagnosed by histopathology or MR imaging and treated by surgical excision followed by antihelminthic medication. We reported 2 cases of solitary intramuscular cysticercosis (biceps brachii and soleus muscle) without any systemic and neurological manifestations, accurately diagnosed by ultrasonography and successfully treated conservatively with antihelminthetics and steroids.

Key words: *Cysticercosis, Intramuscular, Pseudotumor, Ultrasonography*

<https://doi.org/10.3126/jcmc.v5i12.2574>

INTRODUCTION

Cysticercosis occurs mainly in pork eating community due to consumption of undercooked or measily pork. Human are the definitive host carrying the adult tapeworm and excretes cysts and proglottides.¹ Normally pigs are the intermediate host, ingest the faecal cysts, develops embryo, which penetrates mucosa of the gastrointestinal tract and hematogenously disseminate the peripheral tissues and develop the larval form completing the lifecycle.^{1,2} Human cysticercosis occurs when eggs are ingested by human by faecal oral transmission and becomes an accidental intermediate host with development of cysticercosis within the various organs. Clinical manifestations depends on the site of larval encystment (brain, spinal cord, orbit, skeletal muscle, subcutaneous tissue and heart), numbers of cyst and the associated inflammatory response.³ Isolated involvement of skeletal muscle is very rare and can mimic inflammatory, infective and neoplastic lesion. Most of the muscular cysticercosis is associated with multiple muscle

involvement with or without central nervous system involvement but isolated muscle involvement is very unusual. Due to the presence of nonspecific signs and symptoms, it presents the diagnostic dilemmas to the treating physician.^{3,4} Ultrasonography, being non-ionizing and non-invasive, plays an important role in the diagnosis of muscular cysticercosis. If the subcutaneous or muscular lesion with morphological characteristics of cysticercosis is found, no further investigations are required.^{5,6,7} Treatment depends on the site of encystment, number of cyst and symptoms of the patients. Various case series support that treatment with antihelminthetics like albendazole or praziquantel with or without steroids is effective for muscular cysticercosis.^{1,2,8}

CASE REPORTS**Case 1:**

Thirty years female, housewife, vegetarian by

dietary habit from Tharu community, presented with complain of pain and swelling of right arm for three month duration. Swelling was of insidious onset and gradually increasing in size associated with dull aching pain, which worsens by activity only and persisting throughout the day. On examination, there was no obvious visible swelling in the area of interest, however there was a localized tenderness on the anteromedial aspect of the arm. Deep palpation revealed a soft to firm, globular, non pulsatile swelling of 2x3 cm, with indistinct margins and non-adherent to the adjacent skin, and moves with the biceps brachii muscles. Ultrasonographic examination of the right upper arm revealed a well defined cystic lesion of 14x12 mm with small 3 mm eccentrically located echogenic scolex within it with surrounding hypoechoic area in the right biceps brachii muscle suggestive of intramuscular cysticercosis (Figure 1).

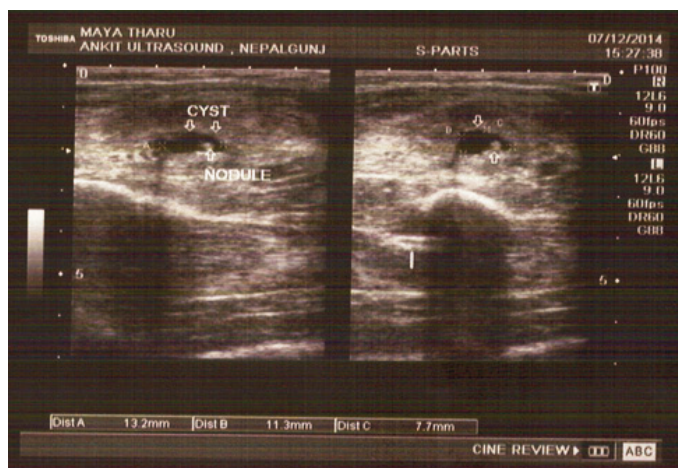


Figure 1. Ultrasonograph of right arm showing intramuscular cysticercosis of biceps brachii.

Patient was managed conservatively with anti-helminthetics (Tab. Albendazole 15mg/kg/day) and steroids (Tab. Prednisolone 1mg/ kg/ per day for 2 weeks tapering dose). She was completely symptom free after 1 month of treatment and doing well up to 6 month of follow-up.

Case 2:

An otherwise healthy, 18 year girl, non- vegetarian by dietary habit, presented with complain of pain and swelling in the left distal calf region for the two week duration. Pain was of dull aching, persistent throughout day and exacerbated by walking. On examination, there was obvious visible swelling

only on careful inspection but the skin over the swelling was normal. Tenderness was localized on the posterolateral aspect of the left distal leg approximately 8 to 10 cm proximal to the ankle joint. Deep palpation revealed a globular, non-pulsatile swelling of 4x5 cm with indistinct margin and swelling was non adherent to the skin and lying deep in the muscle (Figure 2).

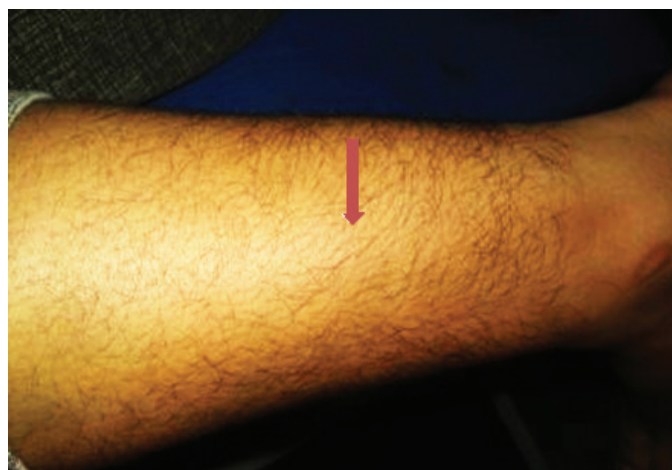

Figure 2. Swelling of the posterolateral aspect of distal third of the left leg.

Ultrasonographic examination showed the presence of hypoechoic cyst of 15x20 mm with perilesional edema and the lesion was surrounded by hypo-echoic muscle of 3x5 cm dimension, which confirms the diagnosis of intramuscular cystic lesion (Figure 3).

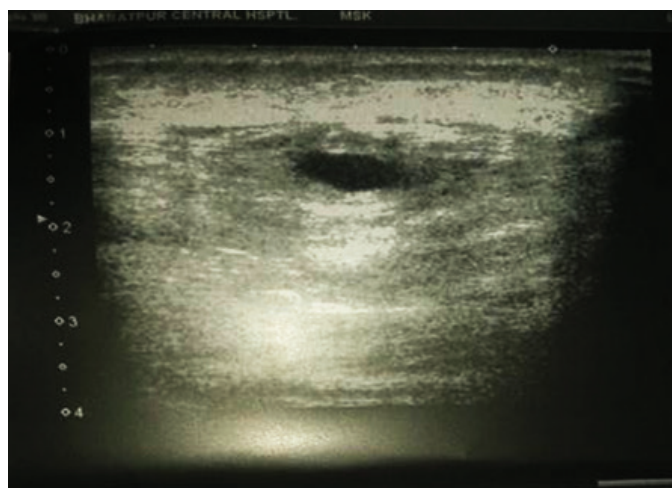


Figure 3. Ultrasonograph of intramuscular cyst of soleus muscle with perilesional edema.

We started treatment with antihelminthetics (Tab. Albendazole 15mg/kg/day) and steroids (Tab. Prednisolone 1mg /kg /day) tapering in next week.

Patients started responding in the 4- 5 th day of treatment and follow up was done weekly. Patient was completely symptom free by fourth week of treatment and up to 6 month of regular follow up.

DISCUSSION

Most of the muscular cysticercosis is asymptomatic and isolated intramuscular involvement with only one cyst is a rare condition. Clinical suspicion of cysticercosis is very important because it can mimic other common pseudotumors like lipomas, neurofibromas, epidermoid cysts, polymyositis and tubercular lymphadenitis etc.^{3,9,10} Three different clinical manifestations of muscular cysticercosis had been described, that includes the myalgic or myopathic type: nodular or mass like type and the pseudohypertrophic type.^{1,4,11} Blood pictures are not helpful in the diagnosis of cysticercosis except raised eosinophils. Plain radiographs rarely show cysticercosis unless the cysticerci are degenerated and get calcified. CT- scan is only useful in the diagnosis of neurocysticercosis but not much beneficial in the musculoskeletal cysticercosis.⁴ MRI visualizes the perilesional edema, degenerative changes of the parasite and exact plane of lodgement of cyst in the soft tissue but findings may differ according to the growth stage of the parasite and host immune response.⁹

Ultrasonography is cheap, easily available, non invasive and highly sensitive, so that this is considered as the best diagnostic tools for muscular cysticercosis.^{6,7,9} There are many reports, in which cysticercosis had been accurately diagnosed by ultrasound and treated well non operatively.⁵⁻⁷ Four different sonographic findings have been described; ^{4, 5} first is cysticercous cyst with an inflammatory mass around it, as a result of death of larvae, similar appearance was found in our second case, second is an irregular cyst with very minimal fluid on oneside indicating leakage of fluid, third is large irregular collection of exudative fluid within the muscle, with the typical cysticercous cyst containing the scolex situated eccentrically within the collection, as found in our first case and the fourth appearance is of calcified cyst appearing as multiple elliptical calcifications in soft tissue similar to the pathognomnic millet seed-shaped elliptical calcifications of plain radiographs.^{4,5}

Treatment of cysticercosis depends on site of infestation, number of cyst and symptoms of patient. Isolated intramuscular cysticercosis requires treatment only when it is painful and recent studies emphasized on non surgical treatment with antihelminthetics (Albendazole or Praziquantel) and steroids.^{8,11,12} Albendazole is the preferred one because praziquantel is known to cause abdominal discomfort, diarrhoea, pruritis and myositis. Steroids are used to control the inflammatory reactions produced by the dying cyst, ^{2,8} our cases were also prescribed albendazole and steroids. They responded well, improved symptomatically and there was a complete resolution of swelling by the end of six month.

REFERENCES

1. Horton J. Biology of tapeworm disease. *Lancet*. 1996 Aug 17;348(9025):481.
2. Kraft R. Cysticercosis: an emerging parasitic disease. *Am Fam Physician*. 2007 Jul 1;76(1):91.
3. Chaudhary S. Cysticercosis of deltoid muscle. *BMJ Case Rep*. 2014;2014.
4. Ogilvie CM, Kasten P, Rovinsky D, Workman KL, Johnston JO. Cysticercosis of the triceps--an unusual pseudotumor: case report and review. *Clin Orthop Relat Res*. 2001 Jan(382):217-21.
5. Vijayaraghavan SB. Sonographic appearances in cysticercosis. *J Ultrasound Med*. 2004 Mar;23(3):423-7.
6. Asrani A, Morani A. Primary sonographic diagnosis of disseminated muscular cysticercosis. *J Ultrasound Med*. 2004 Sep;23(9):1245-8.
7. Mani NB, Kalra N, Jain M, Sidhu R.

- Sonographic diagnosis of a solitary intramuscular cysticercal cyst. *J Clin Ultrasound*. 2001 Oct;29(8):472-5.
8. Evans C, Garcia HH, Gilman RH, Friedland JS. Controversies in the management of cysticercosis. *Emerg Infect Dis*. 1997 Jul-Sep;3(3):403-5.
 9. Jankharia BG, Chavhan GB, Krishnan P, Jankharia B. MRI and ultrasound in solitary muscular and soft tissue cysticercosis. *Skeletal Radiol*. 2005 Nov;34(11):722-6.
 10. Banu A, Veena N. A rare case of disseminated cysticercosis: case report and literature review. *Indian J Med Microbiol*. 2011 Apr-Jun;29(2):180-3.
 11. Mittal A, Gupta S, Mehta V. Subcutaneous and intramuscular cysticercosis: high-resolution sonography. *Indian J Dermatol Venereol Leprol*. 2009 Sep-Oct;75(5):515-6.
 12. Abdelwahab IF, Klein MJ, Hermann G, Abdul-Quader M. Solitary cysticercosis of the biceps brachii in a vegetarian: a rare and unusual pseudotumor. *Skeletal Radiol*. 2003 Jul;32(7):424-8.