



ORIGINAL RESEARCH ARTICLE

ULTRASONOGRAPHICALLY DETECTED RENAL FUSION ANOMALIES IN WESTERN REGION OF NEPAL

OK Shrestha^{1*}, GL Shrestha²

¹ Department of Radiology, Gandaki Medical College, Pokhara, Nepal.

² Department of Radiology, Fishtail Hospital and Research Center Pvt. Ltd., Pokhara, Nepal

*Correspondence to: Om Kumar Shrestha, Department of Radiology, Gandaki Medical College, Pokhara.
Email: shresthaom@gmail.com

ABSTRACT

To establish the incidence and patterns of renal fusion anomalies based on Ultrasonography (USG) in Western region of Nepal. In 2 years period, patients undergoing abdominal USG at Gandaki Medical College between 2010 and 2012 were screened for renal fusion anomalies. After identification, incidence and male:female ratio were stratified for total renal fusion anomalies, horseshoe kidney, crossed fused ectopia and fused pelvic kidney. Out of 31498 patients who underwent abdominal USG, there were 71(1:444) cases of renal fusion anomalies, 61 (1:516) of horseshoe kidneys, 9 (1:3500) of crossed-fused ectopia and 1 (1:31498) of fused pelvic kidney. Male:Female ratio was 1:2 for horseshoe kidney and 1.25:1 for crossed fused ectopia. Renal fusion anomalies are rare congenital malformation. USG is a sensitive and reliable modality for its detection. Horseshoe kidney is the most common renal fusion anomaly followed by crossed fused ectopia. Our ultrasonographic evaluation for incidence of renal fusion anomalies closely matches past autopsy and radiographic data.

Key Words: *Crossed fused ectopia, Fused pelvic kidney, Horseshoe kidney, Renal fusion anomaly.*

INTRODUCTION

Renal fusion anomalies are rare non-fatal congenital malformation of renal development in which both kidneys are fused together in early embryonic life. Knowledge of the presence of renal fusion anomaly is important because the condition is associated with an increased rate of infection, obstruction, stone formation, other congenital anomalies and renal tumors(1 - 5). It may pose problems to surgeons during abdominal surgery. Surgeons should be aware of renal fusion anomalies to minimize perioperative complications because of the uncertain anatomy. Renal fusion anomalies are represented by horseshoe kidneys, crossed fused ectopia and fused pelvic kidney.

Horseshoe Kidney is the most common renal fusion anomaly. In more than 90% of cases, the lower poles of the two kidneys are connected by a parenchymatous or fibrous isthmus that crosses the midline and in rare cases, the isthmus connects the upper poles(3). Horseshoe Kidney accounts for 90% of all renal fusion anomalies and occurs in approximately 0.2% of the population (6,7,14).

Crossed fused ectopia is the second most common renal fusion anomaly in which one kidney crosses over to opposite side and the parenchyma of the two kidneys fuse. Most commonly the upper pole of the inferiorly positioned crossed ectopic kidney is fused to the lower pole of the superior, normally positioned kidney(5).

The synonymous term fused pelvic kidney, lump kidney or cake kidney is defined as an anomaly in which the entire renal substance is fused into one mass, lying in the pelvis and giving rise to two separate ureters which enter the bladder in normal relationship(5,19). Fused pelvic kidney is the most uncommon renal fusion anomaly, even more so if the kidney is drained by a single ureter(20).

To date, diagnosis of renal fusion anomalies has been made by USG, Excretory Urography and Computed Tomography. USG is often the initial procedure performed in the workup of the patient(5). Bent or curved kidneys with tapering of the lower poles or indistinct lower pole margins in conjunction with an anteriorly oriented renal pelvis, low-lying kidneys and the presence of an isthmus are sonographic features of horseshoe kidney(3). Sonographic features of crossed fused ectopia are absence of kidney in contralateral renal fossa or pelvis and fused kidneys on the ipsilateral side with a characteristic anterior or posterior notch between the two fused kidneys and different orientations of collecting systems(8). Sonographic features of fused pelvic kidney include absence of kidneys in respective renal fossae, bilateral pelvic kidneys with extensive parenchymal fusion.

RESEARCH DESIGN AND METHOD

This prospective cross-sectional study was carried out at Radiology Department in Gandaki Medical College Teaching Hospital, Pokhara from January 01, 2010 to March 01, 2012.

Out of all USG examinations performed during this 2 year study period, patients with renal fusion anomalies were identified and the reports were reviewed for horse-shoe kidneys, crossed fused ectopia and fused pelvic kidneys. Incidence and male:female ratios were stratified for total renal fusion anomalies, horseshoe kidney, crossed fused ectopia and fused pelvic kidney. USG was performed using Medison SonoAce 8000 and Kontron Imagic Maestro ultrasound units with 3.5MHz and 11.0MHz transducers. All cases of renal fusion anomalies were initially detected by USG and most of the cases were confirmed either on Excretory Urography or by Computed Tomography.

Table 1: Inclusion criteria for renal fusion anomalies on USG

Horseshoe Kidney	Demonstration of the isthmus
Crossed Fused Ectopia	Absence of kidney in contralateral renal fossa and fused kidneys on the ipsilateral side with a characteristic anterior or posterior notch
Fused Pelvic Kidney	Bilateral pelvic kidneys with parenchymal fusion

Criteria for exclusion were doubtful cases that were not confirmed on Computed Tomography or Excretory Urography.

RESULTS

Total renal fusion anomalies were observed in 71 patients (Table 2). Age of the patients with renal fusion anomalies ranged from 14 to 70 years. Horseshoe kidneys were seen in 61 patients (0.2%). Cases of crossed fused ectopia were found in 9 patients (0.029%) of which 5 cases were right sided crossed fused ectopia and 4 cases were left sided crossed fused ectopia. Single case of fused pelvic kidney (0.003%) was noted in a male. Ratio of horseshoe kidney to crossed fused ectopia was 6.8:1. Male to Female ratio was 1:1.73 for total renal fusion anomalies, 1:2 for horseshoe kidney and 1.25:1 for crossed fused ectopia.

Table 2: USG cases during 2 years study period

Total USG cases	35025
Total abdominal and pelvic USG	31495
Total Renal Fusion Anomalies	71

Table 3 shows the characteristics of cases with renal fusion anomalies. Figure 1 depicts the percentages of horseshoe kidney, crossed fused ectopia and fused pelvic kidney constituting the total cases of renal fusion anomalies.

Table 3: Renal Fusion Anomalies

Renal Fusion Anomaly	Number of cases out of 31498 patients	Incidence	Percentage	Male	Female	Male to female ratio
Total Renal Fusion Anomalies	71	1 in 444	0.23%	26	45	1:1.73
Horseshoe kidneys	61	1 in 516	0.2%	20	41	1:2
Crossed fused ectopia	9	1 in 3500	0.029%	5	4	1.25:1
Fused pelvic kidney	1	1 in 31498	0.003%	1	0	-

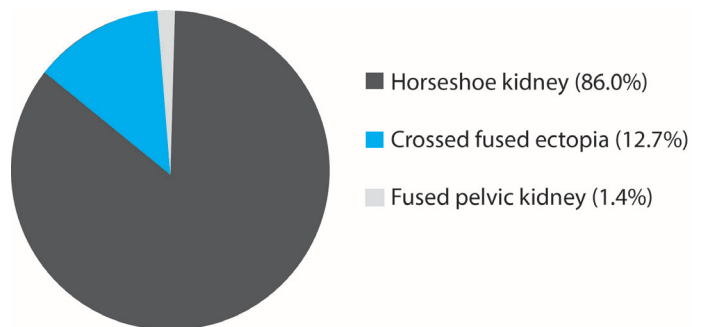


Figure 1: Percentages of Renal Fusion Anomalies

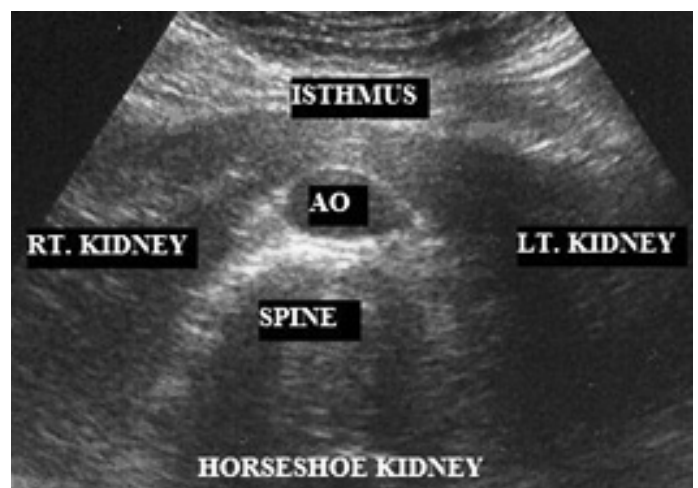


Figure 2: Horseshoe Kidney

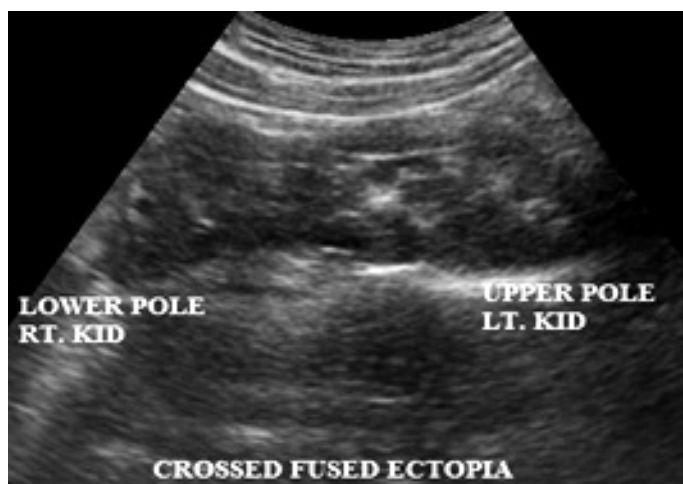

Figure 3: Crossed fused ectopia

DISCUSSION

In our study, all cases of renal fusion anomalies were initially detected by USG and mostly confirmed by Excretory Urography or Computed Tomography. One case of horseshoe kidney was doubtful on USG which was confirmed by Computed Tomography. The isthmus was low at the pelvis at the level of S1 vertebra as detected in Computed Tomography. Most cases were incidental findings on abdominal scan done for other disease state like gynecological problems, obstetric scan, urinary tract infection, lower abdomen pain and during general health check up. It may sometimes be difficult to visualize the isthmus of horseshoe kidney on USG due to bowel gases anterior to it but with proper bowel preparation and technique this can be overcome. Examiners can expect to encounter renal fusion anomalies especially horseshoe kidney not so infrequently. So the area anterior to aorta should be routinely examined as part of sonographic evaluation of the urinary tract and the isthmus should be actively sought.

Table 4: Comparison of incidences of renal fusion anomalies

Study		Total RFA	HSK	CFE	FPK
Glodny ⁽¹⁵⁾	USG	1:601	1:664	1:7891	
Glodny ⁽¹⁵⁾	CT	1:411	1:474	1:3078	
Weizer ⁽¹⁴⁾	USG/ CT/IVU		1:666		
Bell ⁽¹³⁾	Autopsy		1:497		
Kraft ⁽¹¹⁾	Autopsy		1:500		
Devic ⁽¹¹⁾	Autopsy		1:500		
Schell ⁽¹¹⁾	Autopsy		1:511		
Campbell ⁽¹⁶⁾					1:17250
CURRENT STUDY	USG	1:444	1:516	1:3500	1:31498

In the present study, incidence of 1:444 for total renal fusion anomalies, 1:516 for horseshoe kidney, 1:3500 for crossed fused ectopia and 1:31498 for fused pelvic kidney were determined by USG. Incidences of renal fusion anomalies determined in this study correlate well with past radiographic and autopsy data as shown in Table 4. In general, estimated incidence of horseshoe kidney in literature is 1 in 326 to 1033 (9 - 13) and that of crossed fused ectopia is 1 in 1300 to 7500 autopsies (5, 16 - 18).

Out of 31498 patients, single case of fused pelvic kidney was found in this study. Incidence of fused pelvic kidney is not well-established in the literature. By 1957, it was believed that only 9 examples of this condition had been reported (6, 21) while by 2004, fewer than 30 cases were described in the literature (5, 22). Its incidence is not defined in the literature. One study reports 3 cases of fused pelvic kidneys in 51800 autopsies giving an incidence of 1:17250 (6, 16) which is significantly higher compared to incidence of fused pelvic kidney in this study.

This study determined the Male:Female ratio as 1:1.73 for total renal fusion anomalies, 1:2 for horseshoe kidney and 1.25:1 for crossed fused ectopia. Generally, male to female ratio of 2:1 is reported for horseshoe kidneys and crossed fused ectopia (14, 15). In contrary to previous reports, this study demonstrates female predominance among the cases of horseshoe kidney. This could be due to the higher number of female patients undergoing USG in this institution. Male predominance is seen in crossed fused ectopia as reported in the literature.

In this study, horseshoe kidneys accounted for 86.0%, crossed fused ectopia accounted for 12.7% and fused pelvic kidney accounted for 1.4% of total renal fusion anomalies. Thus horseshoe kidney is the most common renal fusion anomaly followed by crossed fused ectopia as described in the literature. Limitation of this study is that this is not a screening of a population sample.

CONCLUSION

Renal fusion anomalies are rare congenital malformation of renal development accounting for approximately 0.23% of the population referred for USG. Our sonographic evaluation of incidence of renal fusion anomalies closely matches past radiographic and autopsy series. USG is a sensitive and reliable modality for its initial detection. This should be taken as incidental findings and has significance in terms of physician and patient awareness.

REFERENCES

- Bauer SB. Anomalies of the kidney and ureteropelvic junction. In Walsh, PC, et al (Eds): Campbell's Urology. Philadelphia, WB Saunders 1998; p 1725.
- Dunnick NR, Sandler CM, Amis ES Jr, et al. Textbook of Uroradiology. Baltimore, Williams and Wilkins, 1997; p 19
- Strauss S, Dushnitsky T, Peer A, Manor H, Libson E, Lebensart PD. Sonographic features of horseshoe kidney: review of 34 patients. J Ultrasound Med 2000 Jan;19(1):27-31.
- Castro JE, Green NA. Complications of horseshoe kidney. Urology 1975; 6:344-347.

5. Türkvtan A, Olçer T, Cumhuri T. Multidetector CT urography of renal fusion anomalies. *DiagnIntervRadiol* 2009 Jun;15(2):127-34.
6. Kaufman MH, Findlater GS. An unusual case of complete renal fusion giving rise to a 'cake' or 'lump' kidney. *J Anat* 2001; 198: 501-504.
7. Decter RM. Renal duplication and fusion anomalies. *Pediatr Clin North Am* 1997; 44: 1323-1341.
8. Goodman JD, Norton KI, Carr L, Yeh HC. Crossed fused renal ectopia: sonographic diagnosis. *Urol Radiol* 1986;8(1):13-16.
9. Tan PH, Chiang GS, Tay AH. Pathology of urinary tract malformations in a paediatric autopsy series. *Ann Acad Med Singapore* 1994; 23(6): 838-43.
10. Culp OS. Treatment of Horseshoe Kidneys. *Ann Surg* 1944; 119(5): 777-787.
11. Lipshutz B, Hoffman C. A contribution to the knowledge of fused kidneys. *Ann Surg* 1918; 68(1): 39-52.
12. David RS. Horseshoe Kidney: A Report of One Family. *British Medical Journal* 1974; 4: 571-572.
13. Robertson PW. Horseshoe Kidney, renal arterial anomalies and hypertension: A study of one family. *Brit med J*, 1968; 2: 793-797.
14. Weizer AZ, Silverstein AD, Auge BK, et al. Determining the incidence of horseshoe kidney from radiographic data at a single institution. *J Urol* 2003 Nov; 170(5): 1722-1726.
15. Glodny B, Petersen J, Hofmann KJ, et al. Kidney fusion anomalies revisited: clinical and radiological analysis of 209 cases of crossed fused ectopia and horseshoe kidney. *BJU Int* 2008 Aug;103(2):224-235.
16. Campbell MF, Harrison JH. *Urology* 3rd edition. WB Saunders: Philadelphia; 1970:1447-1458.
17. Rinat C, Farkas A, Frishberg Y. Familial inheritance of crossed fused renal ectopia. *Pediatr Nephrol* 2001; 16:269-270.
18. Edelman RR, Hesselink J, Zlatkin M. *Clinical Magnetic Resonance Imaging* 3rd edition. Philadelphia, Saunders; 2006: 2792-2793.
19. Glenn JF. Fused pelvic kidney. *J Urol* 1958 Jul; 80 (1): 7-9.
20. Goren E, Eidelman A. Pelvic cake kidney drained by single ureter. *Urology* 1987;30:492-493.
21. Shiller WR, Wiswell OB. A fused pelvic (cake) kidney. *Journal of Urology* 1957;78, 9-16.
22. Calado AA, Macedo A Jr, Srougi M. Cake kidney drained by single ureter. *IntBraz J Urol* 2004; 30:321-322.