

Research Article

Diagnostic Role of Ultrasonography in Right Iliac Fossa Pathologies

Mishal Javaid^{1*}, Ayesha Tariq¹, Hiba Noreen Javaid²

¹University Institute of Radiological Sciences and Medical Imaging Technologies, Faculty of Allied Health Sciences, University of Lahore, Lahore, Pakistan

²Quaid-i-Azam University Islamabad, Pakistan

Article Information

Received: 18 July 2019

Revised version received: 06 September 2019

Accepted: 10 September 2019

Published: 24 September 2019

Cite this article as:

M. Javaid et al. (2019) Int. J. Appl. Sci. Biotechnol. Vol 7(3): 382-386. DOI: [10.3126/ijasbt.v7i3.24908](https://doi.org/10.3126/ijasbt.v7i3.24908)

*Corresponding author

Mishal Javaid,

University Institute of Radiological Sciences and Medical Imaging Technologies, Faculty of Allied Health Sciences, University of Lahore, Lahore, Pakistan

Email: mjhwaii400@gmail.com

Peer reviewed under authority of IJASBT

© 2019 International Journal of Applied Sciences and Biotechnology



This is an open access article & it is licensed under a Creative Commons Attribution Non-Commercial 4.0 International (<https://creativecommons.org/licenses/by-nc/4.0/>)

Keywords: Right iliac fossa pain; Outcome; pre-operative radiological imaging; Ultrasonography

Abstract

Ultrasound is often the imaging modality of choice in patients with acute right iliac fossa pain. Right iliac fossa pain remains the commonest clinical dilemma encountered by general surgeons. The management of acute right iliac fossa pain is audited, examining the relationship between symptom duration, use of pre-operative radiological imaging and patient outcome. **Objective:** To determine the diagnostic role of ultrasonography in Right Iliac Fossa pathologies. **Methods:** A cross sectional descriptive study was carried out at the Department of Radiology in Sir Ganga Ram Hospital Lahore, Pakistan. Duration of study was from March 2018 to November 2018. 85 patients with Right Iliac Fossa pain selected through convenient sampling technique. Statistical software for social sciences (SPSS version 22.0) is used for the analysis of data. **Conclusion:** The results in the study reflect findings from high volume emergency surgical departments and patients of pain in right iliac fossa demonstrating that unfocussed abdominal and pelvic ultrasounds are not an appropriate use of resources in patients with Right iliac fossa pain.

Introduction

By physician's diagnosis and anatomists, Human abdomen is divided into four regions. In the four-region scheme, four quadrants allow localization of pain and tenderness, scars, lumps, and other items of interest. Left lower quadrant, left upper quadrant, right upper quadrant and right lower quadrant are the four quadrants of human abdomen. The right lower quadrant extends from the median plane to the right and from the umbilical plane to the right inguinal

ligament of the patient (Gupta and Michelsen-Jost, 2012). The painful right lower quadrant is a challenge for interdisciplinary sonography. In clinical cases, sonography is used to establish the diagnosis of acute appendicitis. The main differential diagnosis regarding the intestinal tract will be assessed (infectious diseases, Crohn's disease or right sided diverticulitis and urolithiasis). For the assessment of the painful right lower quadrant, sonography is proved to be

a valuable modality (Gritzmann, 2009). The main goal of ultrasound for the diagnosis of patients with right iliac fossa pain is to detect appendicitis. Appendix is a thin walled structure. It is compressible blind ended tubular structure. It is 4mm in diameter and 8cm in length. Obstruction of appendiceal lumen causes inflammation of appendix. Dilation of appendix is caused by continuous mucous secretion. It also causes increased intraluminal pressure, compromising venous return and causing eventual necrosis (Brant and Helms, 2012). Acute appendicitis is the most common abdominal emergency (Gwynn, 2001). Clinical features of appendicitis include right lower quadrant pain, pain migration, nausea or vomiting, anorexia, rebound tenderness, pyrexia and elevated white cell count (Thirumoorthi et al., 2012). It should have a thin wall, should be empty and compressible. There should be no evidence of hyper vascularization (Ozel et al., 2011). Patient having umbilical pain that moves to right iliac fossa is the clinical history of appendicitis. If graded compression technique is used, Ultrasound is proved very specific. Graded compression technique involves applying of high pressure from the transducer over the region of maximal tenderness (Rumack et al., 2010). Most of the women of child bearing age who are suspected with appendicitis have benefits from pre-operative ultrasound. They have a statistically significant lower negative appendectomy rate than those women who did not undergo imaging (McGory et al., 2005).

Diverticular disease is a common condition with a prevalence that rises with age. The severity of diverticulitis can range from a mild, self-limiting disease, to a life-threatening condition complicated by abscess formation or perforation requiring emergency surgery. The signs and symptoms of diverticulitis can be non-specific (Andeweg et al., 2011). Ultrasonographic findings of right-sided diverticulitis include direct visualization of the diverticulum in the right wall of the colon, focal thickening of the colonic wall at the diverticulum site and inflammation of the adjacent fat (Agramunt et al., 2004). In acute right-sided diverticulitis, the clinical presentation is usually indistinguishable from acute appendicitis. On ultrasound, the inflamed diverticulum is seen as an out-pouching arising from the right colon, containing either fluid or a faecolith, surrounded by echogenic inflamed fat (Fenoglio-Preiser et al., 1999).

Ovarian torsion is the most frequent alternative diagnosis to acute appendicitis in girls with Right iliac fossa pain (Peletti and Baldisserotto, 2006). Sonographic features include a unilateral, uniformly enlarged ovary containing multiple small peripheral ovarian follicles measuring 8–12 mm in diameter (Donnelly, 2005). The presence of fluid-blood level has been described as a pathognomonic sign of ovarian torsion. Other findings include thickened fallopian tube, fluid in the pouch of Douglas, ipsilateral deviation of the

uterus and thickening of the coexisting mass wall. The most common finding is a decreased or absent venous flow (Chang et al., 2008). Pregnancy is associated with, and may be responsible for, torsion in approximately 20% of adnexal torsion cases (Asfour et al., 2015). Ovarian tumors, both benign and malignant, are implicated in 50-60% of cases of torsion. Approximately 17% of cases have been found to occur in premenarchal or postmenopausal women (Rotoli, 2017). Crohn's disease is an inflammatory condition, with a wide spectrum of intestinal manifestations ranging from superficial bowel wall ulceration to deep penetrating disease, characterized by fistulae and abscesses (Burisch et al., 2013). Inflammatory bowel disease is a group of inflammatory conditions of the colon and small intestine. Crohn's disease and ulcerative colitis are the principal types of inflammatory bowel disease. Crohn's disease affects the small intestine and large intestine, it can also affect the mouth, esophagus and stomach whereas ulcerative colitis primarily affects the colon and the rectum. Bowel disease arises as a result of the interaction of environmental and genetic factors leading to immunological responses and inflammation in the intestine (Baumgart and Carding, 2007). The incidence of kidney stones appears to have increased over the last few decades due to changes in diet and rising levels of obesity (Scales et al., 2012). The use of ultrasound for the evaluation of renal pathology is well established. With regard to nephrolithiasis, ultrasound is very effective in the detection of hydronephrosis, which may be related to ureteric stone. Ultrasound can detect larger renal stones exhibiting posterior acoustic shadowing with relative ease (Ganesan et al., 2017).

Methods

A cross sectional descriptive study was carried out at the Department of Radiology in Sir Ganga Ram Hospital Lahore, Pakistan. Duration of study was from March 2018 to November 2018. 85 patients with Right Iliac Fossa pain were chosen subsequent to fulfilling consideration (inclusion) and rejection (exclusion) criteria. A complete study and investigation was finished. All necessary examination was done. Right iliac fossa pathologies were confirmed by estimating right iliac fossa pain in patients. Statistical software for social sciences (SPSS version 22.0) is used for the analysis of data.

Results and Discussion

A total of 85 patients were diagnosed. The Mean age was 30.10 ± 12.32 . The Minimum age of patient was 11 and Maximum age was 77 in Table 1.

Out of 85 patients, 71 (83.5) were females and 14 (16.5) were males (Fig. 1).

Fig. 2 shows that 41 (48.2%) patients, had fever and 44 (51.8%) patients out of 85 had no fever.

Table 1: Age

	N	Range	Minimum	Maximum	Mean	Std. Deviation
Age	85	66.00	11.00	77.00	30.1059	12.32982
Valid N	85					

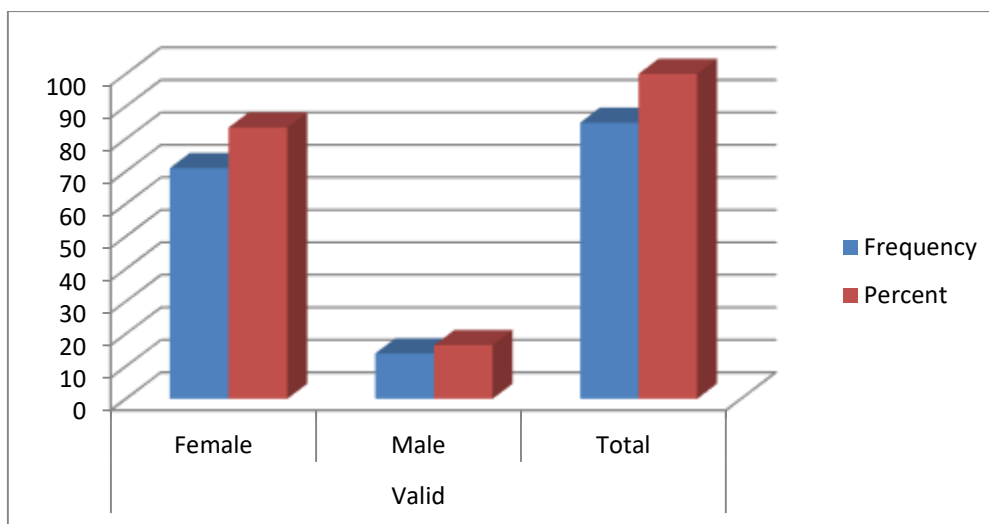


Fig. 1: Gender of patients

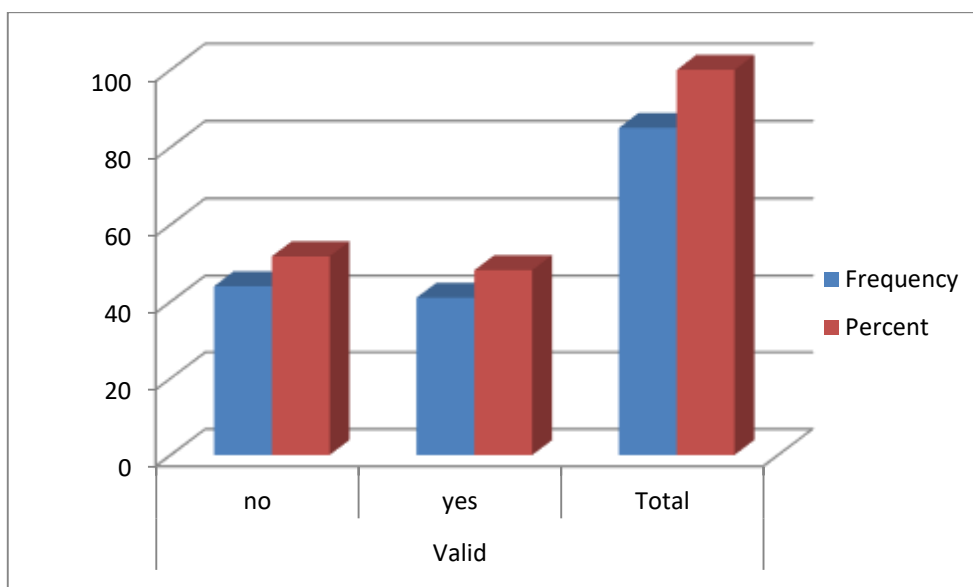


Fig. 2: Fever

According to Table 2, 27 (31.8%) patients had vomiting and 58 (68.2%) patients out of 85 had no vomiting.

According to Fig. 3, total 85 (100%) patients diagnosed were presented with pain in right iliac fossa.

Out of 85 patients, 14 (16.5%) patients had inflamed appendix, 11 (12.9%) had renal calculi, 5 (5.9%) had renal calculus while 55 (64.7%) had no pathology in Table 3.

The current research was designed to determine the Diagnostic role of ultrasonography in right iliac fossa

pathologies. In 2009 a group of scientist worked on The Management of Right Iliac Fossa Pain–Is timing everything conducted at Department of Surgery, Mid-Western Regional Hospital University of Limerick, Ireland. 302 patients, median age 18 years, 59% female, were admitted with Right Iliac Fossa pain for a period of six months. 26 % of patients had Non-specific abdominal pain, 22% had gynaecological and 14% miscellaneous causes and 119 patients (39%) had appendicitis. The majority of patients presenting to hospital with RIF pain did not have

appendicitis. Results of this study showed that majority patients with right iliac fossa pain had appendicitis and minority had other pathologies related to right iliac fossa. O. Ahmed in 2017 studied Clinical utility of abdominal and pelvic ultrasound in the evaluation of right iliac fossa pain in females, conducted at Department of General Surgery, University Hospital Kerry, Ire land. A total of 501 women between the ages of 12 and 50 years were included in the study for three periods from three institutions, presenting acutely with RIF pain and investigated with US abdomen and pelvis. 5.9% of cases confirmed appendicitis sonographically. Over 10% had gynaecological pathology.

Ultrasound is the only imaging modality of choice in women with acute right iliac fossa pain, identifying the appendix in up to 99% of patients.

Informed Consent: Written information was obtained from the participants of this study.

Financial Disclosure: The authors declared that this study received no financial support.

Inclusion Criteria: All male and female patients having right iliac fossa pain.

Table 2: Vomiting

		Frequency	Percent
Valid	no	58	68.2
	yes	27	31.8
	Total	85	100

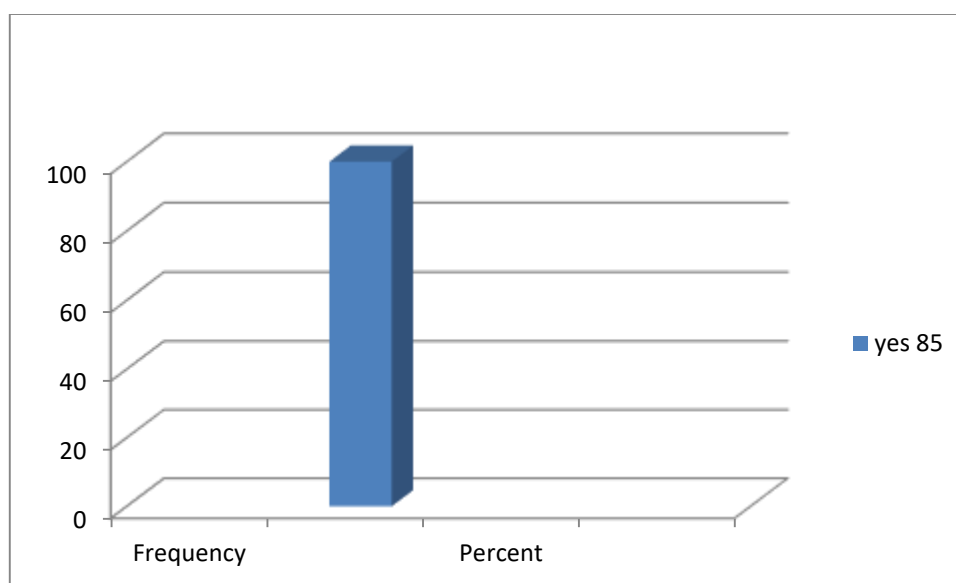


Fig. 3: Pain in RIF

Table 3: Ultrasonographic findings

Pathologies	Frequency	Percent
Inflamed appendix	14	16.5
Nil	55	64.7
Renal calculi	11	12.9
Renal calculus	5	5.9
Total	85	100.0

Author's Contribution

Mishal Javaid & Hiba Noreen Javaid designed the research plan; Mishal Javaid & Ayesha Tariq performed experimental works & collected the required data. Mishal Javaid analysed the data; all authors jointly prepared the manuscript, critically revised and finalized the manuscript.

Conflict of Interest

The authors declare that there is no conflict of interest with present publication.

References

- Agramunt M, Ripollés T, Blanc E, Martínez MJ and Gómez-Abril S (2004) Diverticulitis del colon derecho. Hallazgos en ecografía y tomografía computarizada. *Radiología*. **46**(3):151-158. DOI: [10.1016/S0033-8338\(04\)77953-9](https://doi.org/10.1016/S0033-8338(04)77953-9)
- Andeweg CS, Knobben L, Hendriks JC, Bleichrodt RP and van Goor H (2011) How to diagnose acute left-sided colonic diverticulitis: proposal for a clinical scoring system. *Annals of surgery* **253**(5): 940-946. DOI: [10.1097/SLA.0b013e3182113614](https://doi.org/10.1097/SLA.0b013e3182113614)
- Asfour V, Varma R and Menon P (2015) Clinical risk factors for ovarian torsion. *Journal of Obstetrics and Gynaecology* **35**(7): 721-725.
- Baumgart DC and Carding SR. (2007) Inflammatory bowel disease: cause and immunobiology. *The Lancet* **369**(9573): 1627-1640. [10.1016/S0140-6736\(07\)60750-8](https://doi.org/10.1016/S0140-6736(07)60750-8)
- Brant WE and Helms CA (2012). Fundamentals of diagnostic radiology, Lippincott Williams & Wilkins.
- Burisch J, Jess T, Martinato M, Lakatos PL and ECCO-EpiCom. (2013) The burden of inflammatory bowel disease in Europe. *Journal of Crohn's and Colitis* **7**(4): 322-337. [10.1016/j.crohns.2013.01.010](https://doi.org/10.1016/j.crohns.2013.01.010)
- Chang HC, Bhatt S and Dogra VS (2008) Pearls and pitfalls in diagnosis of ovarian torsion. *Radiographics* **28**(5): 1355-1368. DOI: [10.1148/rg.285075130](https://doi.org/10.1148/rg.285075130)
- Donnelly LF (2005) Diagnostic imaging: pediatrics, Amirsys Incorporated.
- Fenoglio-Preiser CM, Noffsinger AE, Stemmermann GN, Lantz PE and Isaacson PG (1999) Gastrointestinal pathology: an atlas and text, Lippincott-Raven Philadelphia, PA
- Ganesan V, De S, Greene D, Torricelli FC, Monga M. () Accuracy of ultrasonography for renal stone detection and size determination: is it good enough for management decisions? *Bju International* **119**(3): 464-469. [10.1111/bju.13605](https://doi.org/10.1111/bju.13605)
- Gritzmann N (2009) 0693: Ultrasound for Right Iliac Fossa Pain. *Ultrasound in Medicine & Biology* **35**(8): S97. DOI: [10.1016/j.ultrasmedbio.2009.06.1081](https://doi.org/10.1016/j.ultrasmedbio.2009.06.1081)
- Gupta S and Michelsen-Jost H (2012) Anatomy and function of the thenar muscles. *Hand clinics* **28**(1): 1-7. [10.1016/j.hcl.2011.09.006](https://doi.org/10.1016/j.hcl.2011.09.006)
- Gwynn LK (2001) The diagnosis of acute appendicitis: clinical assessment versus computed tomography evaluation1. *Journal of Emergency Medicine* **21**(2): 119-123. [10.1016/S0736-4679\(01\)00353-5](https://doi.org/10.1016/S0736-4679(01)00353-5)
- McGory ML, Zingmond DS, Nanayakkara D, Maggard MA and Ko CY (2005) Negative appendectomy rate: influence of CT scans. *The American surgeon* **71**(10): 803-808.
- Ozel A, Orhan UP, Akdana B, Disli C, Erturk SM, Basak M and Karpat Z (2011) Sonographic appearance of the normal appendix in children. *Journal of Clinical Ultrasound* **39**(4): 183-186. [10.1002/jcu.20807](https://doi.org/10.1002/jcu.20807)
- Peletti AB and Baldisserotto M (2006) Optimizing US examination to detect the normal and abnormal appendix in children. *Pediatric radiology* **36**(11): 1171-1176.
- Rotoli JM (2017) Abdominal Pain in the Post-menopausal Female: Is Ovarian Torsion in the Differential? *The Journal of emergency medicine* **52**(5): 749-752. [10.1016/j.jemermed.2016.08.045](https://doi.org/10.1016/j.jemermed.2016.08.045)
- Rumack CM, Wilson S, Charboneau JW and Levine D (2010) Diagnostic Ultrasound: 2-Volume Set. Missouri: Elsevier Mosby.
- Scales Jr CD, Smith AC, Hanley JM and Saigal CS (2012) Urologic Diseases in America Project. Prevalence of kidney stones in the United States. *European urology* **62**(1): 160-165. [10.1016/j.eururo.2012.03.052](https://doi.org/10.1016/j.eururo.2012.03.052)
- Thirumoorthi AS, Fefferman NR, Ginsburg HB, Kuenzler KA and Tomita SS. (2012) Managing radiation exposure in children—reexamining the role of ultrasound in the diagnosis of appendicitis. *Journal of pediatric surgery*. **47**(12): 2268-2272. DOI: [10.1016/j.jpedsurg.2012.09.018](https://doi.org/10.1016/j.jpedsurg.2012.09.018)