

## ■ Case Report

### Chronic osteomyelitis of clavicle in a 25 year-old male

P Chaudhary, NK Karn, BP Shrestha, GP Khanal, R Maharjan  
Department of Orthopaedics, B.P.Koirala Institute of Health Sciences, Dharan, Nepal

#### Abstract

Osteomyelitis of clavicle is very uncommon. The most common locations include metaphysis of long bones.<sup>1</sup> Here, we present a case of 25 year old male who had presented to the Orthopaedic department of B.P.Koirala Institute of Health Sciences, Dharan, Nepal with complain of pain and Chronic discharging sinus from left clavicle for last 1 year. There was history of abscess over the clavicle and incision and drainage was performed 1 year back by the general surgeon. With all these characteristics and literature reviewed, we report this case for its rarity and unique characteristics. In this part of world (Nepal) patients commonly present late to the hospital

#### Introduction

Most lesions of the clavicle are traumatic and pose few diagnostic difficulties.<sup>1</sup> Nontraumatic clavicular lesions, on the other hand, are rare and frequently present problems in diagnosis. The differential diagnosis of clavicular osteomyelitis is also discussed. The clinical duration of the infectious process in these patients ranged from 2 weeks to 1.5 years.<sup>2</sup> Patient presented with pain, fever, localized swelling or a mass, soft tissue abscesses. The radiographic findings also varied: the lesion may be sclerotic, lytic and mixed. Periosteal reaction was detected<sup>3</sup> *Staphylococcus aureus* was the causal organism. Although clavicular osteomyelitis is rare, particularly in adults, it should be considered in the differential diagnosis of a clavicular lesion.<sup>4</sup> The final diagnosis often depends on the results of biopsy and cultures.<sup>5</sup>

Osteomyelitis of clavicle is rare, with an incidence ranging from 0% in mixed-aged population to 7% in children. any portion of clavicle can be affected but mid-portion or medial half of clavicle is preferred site. An adjacent joint ie. sternoclavicular joint has been involved in 95% of all septic arthritis. The rarity of clavicle osteomyelitis has prompted us to report this case.<sup>6-9</sup>

#### Case report

A 25 year old gentleman from remote hilly areas reported to department of Orthopaedics, B.P.Koirala Institute of Health Sciences, Dharan with pain and chronic discharging sinus from left clavicle for one year. Incision and drainage was done by general surgeon. Secondary suture was applied 3 times but every time there were wound dehiscence. On examination, there were serosanguinous discharge from left clavicle and middle portion of clavicle was exposed (Fig. 1). Culture and sensitivity test of discharge material was done which came to be *Staph. aureus*. X-ray of left clavicular region was done to see bony changes. on X-ray examination, whole middle portion of clavicle was sequestered (Fig. 2) A routine blood investigation. After doing pre anaesthetic check-up, Sequestrectomy and wound debridement was performed (Fig. 3). At 3 weeks follow up wound healed.

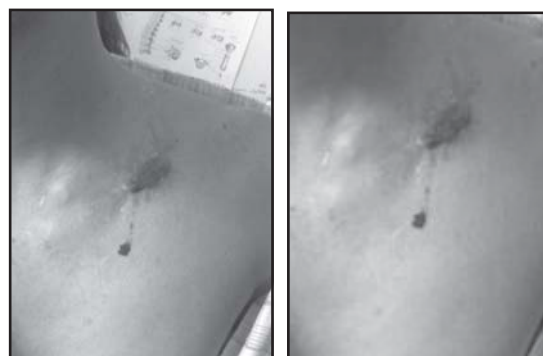


Fig. 1: Discharging sinus over left Clavicle

---

Address for correspondence:  
Dr. Pashupati Chaudhary  
Associate Professor, Department of Orthopaedics  
B.P.Koirala Institute of Health Sciences, Dharan, Nepal  
Email: chaudharypashupati@yahoo.com

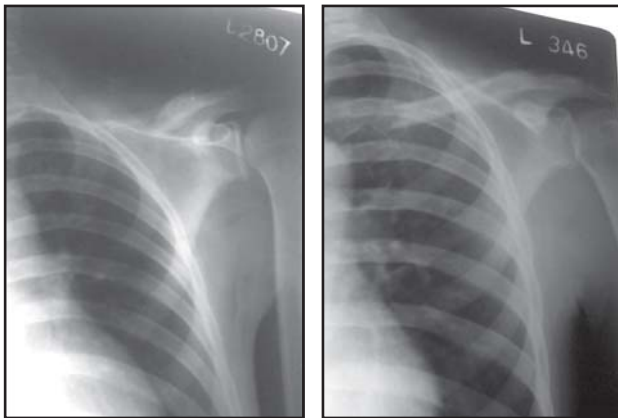


Fig. 2: Pre-Operative X-rays

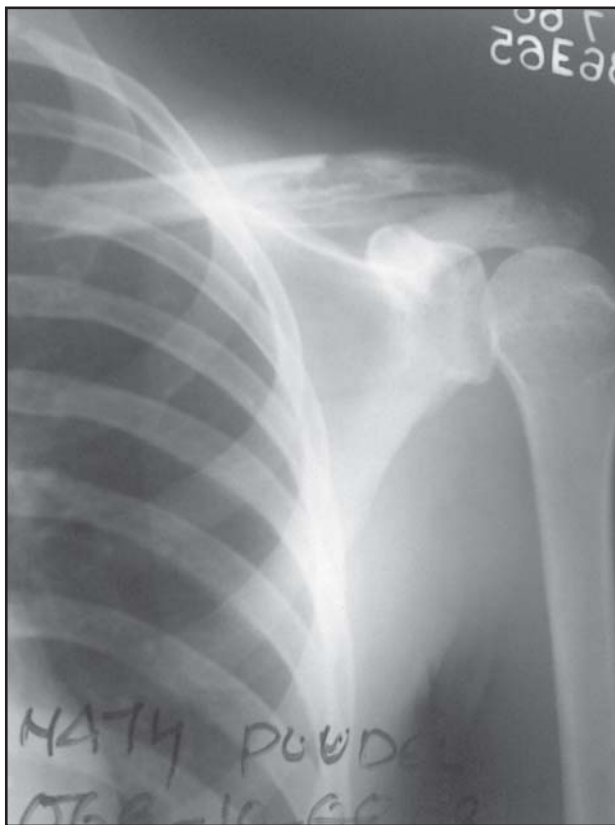

Fig. 3: Post-operative X-ray

## Discussion

Osteomyelitis of the clavicle is a rare entity and can occur as a complication of head and neck surgery.<sup>1,2</sup> Ten consecutive cases of the clavicular osteomyelitis were reviewed at the University of California Medical Center, Los Angeles, over the past seven years. Six

cases were associated with prior surgical procedures, and five cases presented as chronic wound drainage.<sup>3-5</sup> One case was related to a pharyngocutaneous fistula following a supraglottic laryngectomy. Four patients presented with acute symptoms resulting from hematogenous spread, and two of the four patients had *Staphylococcus aureus* on blood cultures. Long-term intravenous antibiotic therapy (six to eight weeks) was used to successfully treat cases of hematogenously spread osteomyelitis. Wide surgical débridement was the mainstay of treatment in the chronic conditions, with antibiotic therapy having a secondary role.<sup>6,7</sup> Myocutaneous flaps were required in two patients who had had surgery and antecedent radiotherapy. To conclude, the surgeon should be aware that osteomyelitis of the clavicle can occur as a complication of head and neck procedures. In addition, the treatment of the chronic form of clavicular osteomyelitis is surgical débridement and possible flap reconstruction.<sup>8,9</sup>

Osteomyelitis of the clavicle is an uncommon disease, but it should be considered in patients who present with pain, cellulitis, or drainage in the sternoclavicular area following head and neck surgery, irradiation, subclavian vein catheterization, or immunosuppression. An idiopathic presentation is possible.<sup>1,3</sup>

In contrast to primary osteomyelitis of the clavicle, which is occasionally seen in children, secondary osteomyelitis is quite rare. It is often mistaken for a fracture or a possible neoplasm on plain x-rays. Tomograms and CT scanning are confirmatory, and in early cases, tech-netium-99m bone scanning can be helpful. Treatment must include early, aggressive surgical débridement of all affected tissues, followed by wound coverage with a well-vascularized flap and perioperative antibiotics.<sup>4,5</sup> Diagnosis of chronic osteomyelitis of the clavicle should be made by history and physical examination and be confirmed by standard X-ray, bone scan and open biopsy. In contrast MRI and CT can provide data on the involvement of adjacent joints, soft tissue and muscles especially in the early process of disease, but do not add information relevant to the patient's management. Treatment with non-steroidal anti-inflammatory drugs is rapidly beneficial in most patients.<sup>6</sup>

Resection of the clavicular head and clavicular-manubrial junction is required in cases of chronic

osteomyelitis or tumor. This article describes a technique for soft tissue coverage in an infected or irradiated area after resection using a split pectoralis major rotational muscle flap.<sup>3,5,8</sup>

Resection of the clavicular head and clavicular-manubrial junction is indicated for chronic osteomyelitis or in rare cases of involvement with malignant tumor. In the case of osteomyelitis, risk factors include previous operation, prior irradiation, intravenous drug use, or an immunocompromised state<sup>1,3</sup> These conditions predispose the wound to poor healing post operation. Removal of the medial aspect of the clavicle and the lateral manubrium leaves a significant deformity and exposed vascular structures, split pectoralis major rotational muscle flap for reconstruction.<sup>9</sup>

### Conclusion

Osteomyelitis of the clavicle is an uncommon disease<sup>1</sup>, but it should be considered in patients who present with pain, cellulitis, or drainage in the sternoclavicular area following head and neck surgery, irradiation, subclavian vein catheterization, or immunosuppression. An idiopathic presentation is possible. Proper history and clinical examination is key to diagnosis.<sup>2,3</sup>

### References

1. Allessi D.M., Sercarz J.A., Calcaterra T.C. Osteomyelitis of the clavicle. Arch Otolaryngol Head Neck Surg 1988; 114:1000-1002.
2. Krespi Y.P., Monsell E.M., Sisson G.A. Osteomyelitis of the clavicle. Ann Otol Rhinol Laryngol 1983; 92:525-527.
3. Granick M.S., Ramasastry S.S., Goodman M.A., Hardesty R. Chronic osteomyelitis of the clavicle. Plast Reconstr Surg 1989; 84:80-84.
4. Nahai F., Morales L., Jr, Bone D.K., Bostwick J., III Pectoralis major muscle turnover flaps for closure of the infected sternotomy wound with preservation of form and function. Plast Reconstr Surg 1982; 70:471-474.
5. Majure J.A., Albin R.E., O'Donnell R.S., Arganese T.J. Reconstruction of the infected median sternotomy wound. Ann Thorac Surg 1986; 42:9-12.
6. Backer C.L., Pensler J.M., Tobin G.R., Mavroudis C. Vascularized muscle flaps for life-threatening mediastinal wounds in children. Ann Thorac Surg 1994; 57:801-802.
7. Guedon C., Gandjbackch I., Piwnica A., Romano M., Andreassian B. Use of myoplasty after acute mediastinitis occurring after heart surgery. Apropos of 167 cases. Ann Chir Plast Esthet 1994; 39:191-197.
8. Gonzalez Munoz J.I., Cordoba Pelaez M., Tebar Boti E., Tellez Cantero J.C., Castedo Mejuto E., Varela de Ugarte A. Surgical treatment of sternoclavicular osteomyelitis. Arch Brononeumol 1996; 32:541-543.