

■ *Original Article*

## Randomized controlled trial comparing dynamic compression plate versus intramedullary interlocking nail for management of humeral shaft fractures

P Chaudhary, NK Karn, BP Shrestha, GP Khanal, R Rijal, R Maharjan, R Kalawar  
Department of Orthopaedics, B.P.Koirala Institute of Health Sciences, Dharan

### Abstract

**Background:** The optimal method of humeral shaft fracture fixation remains debatable. With the dramatic success of intramedullary fixation for fractures of the femur and tibia, there was speculation that IM-ILN might be more appropriate for humeral shaft fractures than DCP. **Objectives:** To compare the fixation of fracture shaft of humerus with interlocking nail and dynamic compression plate in terms of duration of operating time, amount of blood loss, rate of infection, pain at the fracture site, time to achieve union, functional outcome (DASH score) and complications of surgery. **Methods:** This was randomised control trial study. All patients with fractures of shaft of humerus that met the criteria for operative interventions presenting to the Department of Orthopaedics, BPKIHS in the study period and giving informed consent were included in the study. Sample size was taken 30 in each group. **Results:** The usual mode of injury in both the groups were road traffic accident followed by fall from height, work place injury. The operating time for nailing was 100 mins with standard deviation of 11.24 while that of humerus plating was 90.25 with standard deviation 15.6. The mean blood loss in nail group was 148.75 with standard deviation of 36.70 while that in plate group was 205.00 with standard deviation of 45.60. Post operative hospital stay was similar in both groups with mean stay of 4.5 days. DASH was significantly higher in plating group at 6,12,18 and 24 weeks follow up. This showed better functional outcome in nailing group. **Conclusion:** Dynamic compression plating is better than interlocking nail for fracture shaft of humerus.

**Keywords:** shaft of humerus, interlocking nail, plate fixation

### Introduction

Fractures of the humeral diaphysis comprise approximately 3% of all fractures.<sup>1</sup> The proportion of these fractures being treated conservatively reportedly varies from 33%<sup>2</sup> to 95%.<sup>3</sup> Intramedullary fixation of humeral diaphyseal fractures<sup>4-7</sup> as well as compression plating<sup>8,2,9</sup> or external fixation in open fractures<sup>10</sup> are described. Lin reported a near 100% union rate in 73 fractures treated with either locked intramedullary nails or compression plates and screws.<sup>11</sup> He noted a significantly shorter operative time, less blood loss, and a lower complication rate with locked intramedullary nails. Chapman et al. found no difference in outcome

or complication rate in an 84-patient, prospective, randomized study comparing Russell-Taylor locked intramedullary nails with 4.5-mm compression plates and screws.<sup>11</sup> Chapman et al found no difference in outcome or complication rate in an 84-patient, prospective, randomized study comparing Russell-Taylor locked intramedullary nails with 4.5-mm compression plates and screws.<sup>11</sup> The optimal method of humeral shaft fracture fixation remains in debate. With the dramatic success of intramedullary fixation for fractures of the femur and tibia, there was speculation that IM-ILN might be more appropriate for humeral shaft fractures than DCP. In this study, it is believed that the theoretical advantages of IM-ILN (which include less invasive surgery, an undisturbed fracture hematoma, and use of a load-sharing device) support its use in the humerus.<sup>12</sup>

---

Address for correspondence:  
Dr. Pashupati Chaudhary  
Associate Professor  
Department of Orthopaedics  
B.P.Koirala Institute of Health Sciences, Dharan  
Email: chaudharypashupati@yahoo.com

Humerus nailing has advantage in comminuted fracture and segmental fracture of shaft of humerus over humerus plating. Dynamic compression plating is gold standard for transverse stable fracture of shaft of humerus. Biomechanically intramedullary nailing can also be used in transeverse fracture of shaft of

humerus<sup>1-3</sup> There are very few studies comparing intramedullary interlocking nail and dynamic compression plating in fracture shaft of humerus and virtually no study in this part of world.

### Methods

All patients with fractures of shaft of humerus that met the criteria for operative interventions (intramedullary interlocking nailing and dynamic compression plating) presenting to the department of Orthopaedics BPKIHS in the study period and giving informed consent were included in the study.

Sample size: 30 in each group

Exclusion criteria:

Gustilo grade II and III open fractures shaft of humerus

Periarticular fractures of humerus

Fractures with associated neurovascular injury

Bone and joint disease interfering with rehabilitation

Primary nerve palsy

Patients with active infection

Candidates not giving informed consent

Age less than with immature skeletal

Pathological fractures

The patients were randomized using Excel random number generation technique into two groups:

N Group: Cases treated with intramedullary interlocking nail

P Group: Cases treated with dynamic compression plate

The material used in N group was commercially available intramedullary interlocking nail and in P group as commercially Dynamic compression plate (4.5 mm, Broad DCP)

Post operatively both groups were immobilised in U-slab for 2 weeks. The average follow-up was 6 months. Each group was studied for demographics and fracture type. Patients were followed up on 2nd week, 6th week, 12th week, and 24th week and assessed

for evidence, pain at the fracture site using visual analogue score (VAS score), evidence of union, functional outcome using DASH score.

Random collection of the patient was done on the basis of computer based random number, proportion, measure tendency and dispersion of the variables like age, sex, involved limb, dominant limb, duration of injury, type of fracture, duration of operating time, amount of blood loss, rate of infection, pain at the fracture site, time to achieve union, functional outcome of shoulder and elbow, complications of surgery were tested by appropriate parametric and non parametric statistical technique (e.g. T-test, Chisquare test) depending upon the nature of variables in both the groups. Outcomes at various followup intervals was compared between two groups and both the magnitude and significance of difference was measured using appropriate tests. The results were compared with other relevant studies in the literature.

### Operative procedure

#### Intramedullary interlocking nail

Patients was placed in the beach chair, semisitting position, with affected arm draped free. The image intensifier is brought in directly laterally on the injured side and the patient is brought on the edge of the table [Fig.1]. It is important to check and ensure a good X-ray of the entire humerus is possible. The surgeon stands at the top of the bed looking down on the shoulder and the assistant stands below on the other side of the image holding arm. A small incision was made at the anterolateral corner of the acromion, the



Fig.1 Image intensifier

deltoïd was split and any visible subdeltoïd bursa was excised [Fig.2]. The supraspinatus tendon was identified, and split for 1-2 cm in line with its fibres. The entry point was in greater tuberosity, just lateral to the articular margin. The canal was broached with either an awl or a starter reamer placed over guide wire. A long guide wire was then passed to the fracture site, only nail greater than 6 mm in diameter was cannulated. Reamming was done till chattering sound of cortex was heard, and then inserted nail 1 mm smaller in diameter than last reamer used. The length of nail was carefully chosen and checked twice, put in the medullary cavity. The nail was then locked with screws using zig proximally and free hand technique distally [Fig. 3a,b,c,d]. Any split in rotator cuff was repaired, incision was closed in layers. standard dressing was applied, no external splint was applied.

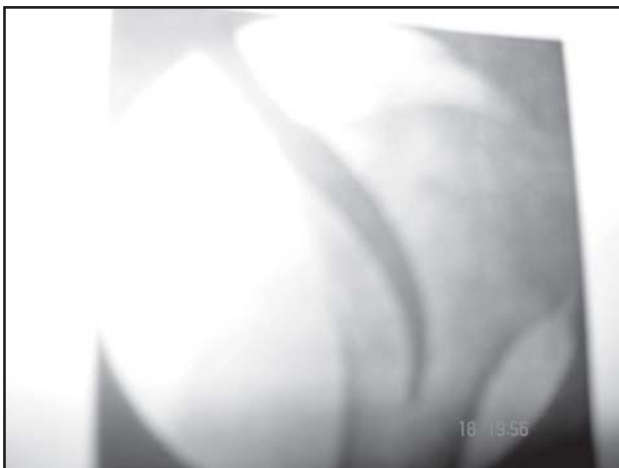

Fig.2 Anterolateral approach

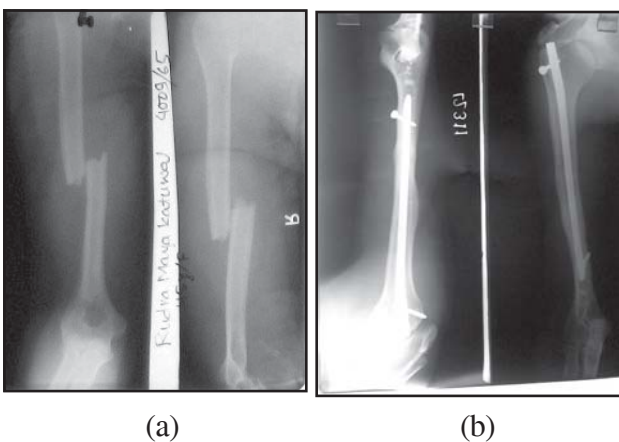


Fig.3 Pre operative and Post operative X-rays

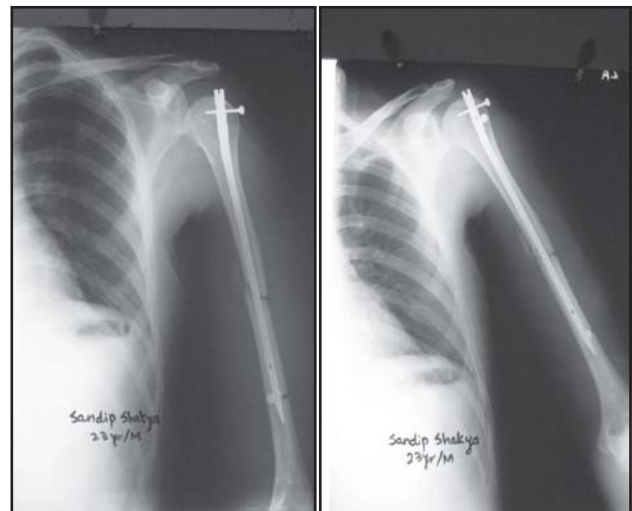


Fig.3 Pre operative and Post operative X-rays

**Open reduction and internal fixation with dynamic compression plate**

Fractures in proximal and middle third are best approached through an anterolateral incision. Fractures that extend into distal third of the bone are approached through posteriorly. A broad 4.5mm dynamic compression plate or LCP plates were used. In physically small individuals with thin humerus, a narrow 4.5mm DCP were used.

**Results**

The nailing and plating groups were similar with respect to age, sex, dominant limb, injured limb, mode of injury, immediate treatment, injury surgery interval. 75% were male and 25% female in both nailing and plating group. The mean age was 34.5 years for nail group and 36.4 in plate group

The usual mode of injury in both the groups were road traffic accident followed by fall from height, work place injury. Most of the patients were right handed. The immediate immobilization technique used was U-slab application in both the groups. Mean surgery interval in both the groups was similar (23.1 days in nailing group, 20.05 days for plating group). Open reduction and plating for fracture shaft of femur took less time as compared to closed/open reduction and internal fixation with nailing in our study

The operating time for nailing was 100 mins with standard deviation of 11.24 while that of humerus plating was 90.25 with standard deviation 15.6. Per

operative blood loss was significantly more in open reduction and internal fixation with plating. The mean blood loss in nail group was 148.75 with standard deviation of 36.70 while that in plate group was 205.00 with standard deviation of 45.60. Post operative hospital stay was similar in both groups with mean stay of 4.5 days. There was no significant difference in the post operative complication rate in both the groups. The peroperative radial nerve palsy was 4% in nailing group as compared to 2% in plating group. There were no significant difference in post operative infection at second week in both the groups and no evidence of infection on subsequent follow up.

There were no significant difference in pain in both the groups. Nailing and plating groups had no significant difference in tenderness at fracture site on attempted angulation till 12 weeks follow up but the tenderness was significantly less in plating group at 18 and 24 weeks follow up which showed faster union in plating group. Dash score gradually improved in both nail and plate group but Dash score was significantly higher in plating group at 6,12,18 and 24 weeks follow up. Five patients had stiffness of shoulder in nailing group [Fig. 5]. This shows better functional outcome in nailing group



Fig.5 Functional outcome

There was no significant difference between radiological evidence of union at 6, 12 and 18 weeks follow up in the two groups but plating group showed better (p value-0.023) radiological evidence of union at 24 weeks follow up. There was implant failure in 1 patient [Fig. 4]

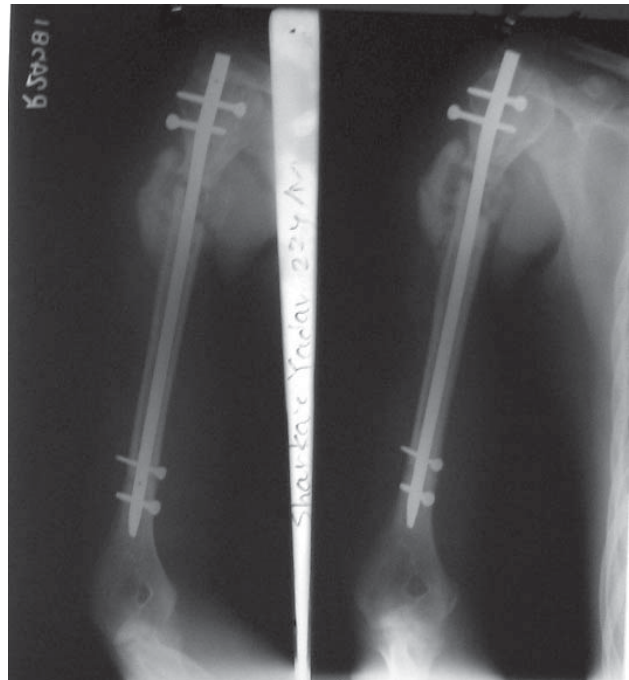

Fig.4 Post operative X-rays with implant failure

Radiologically four cortices union was only 50% in nailing group while it was 80% in plating group in 24 weeks post operative time.

### Discussion

The nailing and plating groups were similar with respect to age, sex, dominant limb, injured limb, mode of injury, immediate treatment, injury surgery interval which indicated that the randomization had been effective. 75% were male and 25% female in both nailing and plating group. In the study by Changulani et al<sup>13</sup> 86.9% were males and 13% females in nailing group, while in plating group 79.2% were males and 20.8% were females. The mean age of the patients with nailing was 39 years and 35 years for plating group in the study by Changulani et al<sup>13</sup> which comparable with our study of mean age was 34.5 yrs for nail group and 36.4 yrs for plate group. The mean age of patients was 45.3 years in the study conducted by S Raghavendra, Haresh P Bhalodiya.<sup>14</sup> The



operating time is more in nailing group in our study which is in contrary to the study done by Lin who had found shorter operating time. This may be due to poor expertise of surgeon, unavailability of trained person to operate image intensifier. The intraoperative blood loss is less in nailing group most probably due to less invasive technique used in nailing group which is comparable with study done by Lin.<sup>15</sup> Post operative hospital stay and post operative infection are comparable with done by S Raghvendra, Haresh Bhalodiya. Raghvendra et al<sup>14</sup> had found better outcome in nailing group but in this study functional outcome is better in nailing group. Plating group showed better radiological evidence of union at 24 weeks follow up. Usually distraction at the fracture during insertion lead to delayed union of fracture in nailing group. Raghvendra S et al study also had concluded delayed union in nailing group.

Vander Griend et al (1986)<sup>16</sup> reported union in 35 of 36 plated humeral shaft fractures with no shoulder or elbow morbidity and one radial nerve palsy.

Brumback, Bosse, Poka et al (1986)<sup>17</sup> reported a 94% union rate with rush pins and Enders although there was a significant rate of insertion site morbidity and backing out of the nails such that the excellent clinical success rate was much lower (62%)

Henley (1992)<sup>18</sup> reported a series of 49 patients with humeral shaft fractures treated with Ender nailing and had only one nonunion

Imgman, Waters (1994)<sup>19</sup> concluded that closed locked intramedullary nailing for humeral shaft fractures can reliably provide secure fixation with acceptable risks.

### Conclusion

Intramedullary interlocking nailing is less invasive procedure with advantages of less blood loss as compared to plating for fracture shaft of humerus. There may be delay in union in nailing group due to distraction at the fracture site which usually occurs during nail insertion. The functional outcome is better in plating group. The poor outcome in intramedullary interlocking nailing group is attributable to rotator cuff tear and shoulder impingement.

The dynamic compression plating is better than interlocking nail for fracture shaft of humerus.

### References

1. Canale ST. Campbell's Operative Orthopaedics, 10th ed, volume III (54); 3002-3016. Philadelphia: MOSBY; 2003
2. Canale ST, Beaty Jh. Campbell's Operative Orthopaedics, 11th ed, volume II (54); 3389-3398. Philadelphia: Mosby Elsevier; 2008
3. Bucholz RW, Heckman JD, Court- Brown CM. Rockwood & Green's fractures in adults, 6th ed, volume I (30); 117-1159. Lippincott Williams & Wilkins; 2006
4. Schemitsch EH, Bhandari M. Fractures of the diaphyseal humerus. In: Browner BD, Jupiter JB, Levine AM, Trafton PG, eds. Skeletal trauma, 3rd ed. Toronto: WB Saunders; 2001:1481-1511
5. Praemer A, Furner S, Rice DP. Musculoskeletal conditions in the United States. Rosemont, IL: American Academy of Orthopaedic Surgeons; 1999
6. Brinker MR, O'Connor DP. The incidence of fractures and dislocations referred for Orthopaedic services in a capitulated population. J Bone Joint Surg Am 2004; 86:290-297
7. Gregory PR. Fractures of the humeral shaft. In : Bucholz RW, Heckman JD, eds. Rockwood and Green's fractures in adults, 5th ed. Philadelphia: Lippincott Williams & Wilkins; 2001: 973-996
8. Fears RL, Gleis GE, Selingson D. Diagnosis and treatment of complications: Fractures of the diaphyseal humerus. In: Browner BD, Jupiter JB, Levine AM, Trafton PG, eds. Skeletal trauma, 2nd ed. Toronto: WB Saunders; 1998: 567-578
9. Samiento A, Zagorski JB, Zych G et al. Functional bracing for the treatment of fractures of the humeral diaphysis. J Bone Joint Surg Am 2008; 82: 478-486
10. Standard JP, Harris HW, McGwin G Jr, et al. Intramedullary nailing of humeral shaft fractures with a locking, flexible. J Bone Joint Surg Am 2003; 85: 2103-2110
11. Tytherleigh- Strong G, Walls N, McQueen NM. The epidemiology of humeral shaft fractures. J Bone Joint Surg Am 1998; 80: 249-253

12. Sommer C, Gautier E, Muller M, et al. First clinical results of the locking compression Plate(LCP). *Injury* 2003; 34( suppl 2): B43-54
13. Changulani M, Jain UK and Keswani T. Comparison of use of the humerus intramedullary nail and dynamic compression plate for the management of diaphyseal fractures of humerus, A randomised controlled study, *International Orthopaedics*, Springer- Verlag 2006; 10.1007/s00264-006-0200-1
14. Radhavendra S, Bhalodiya HP. Internal fixation of fractures of the shaft of the humerus by dynamic compression plate or intramedullary nail: A prospective study. *Indian J Orthop( serial online)* 2007( cited 2009 Jul 1)41:214-8
15. Lin J Treatment of humeral shaft fractures with humeral locked nail and comparasion with plate fixation *J Trauma* 1998; 44: 859
16. Vander Griend RA, Tomasin J, et al. Open reduction and internal fixation of humeral shaft fractures. *J Bone Joint Surg Am* 1986; 68: 430-433.
17. Brumback RJ, Bosse MJ, Poka A, et al. Intramedullary stabilization of humeral shaft fractures in patients with multiple trauma. *J Bone Joint Surg Am* 1986; 68: 960-969.
18. Henley MB, Champmn JR, Claudi BF. Closed retrograde Hackethal nail stabilization of humeral shaft fractures. *J Orthop Trauma* 1992; 6:18-24
19. Imgman AM, Waters DA. Locked intramedullary nailing of humeral shaft fractures implant design, surgical technique and clinical results, *J Bone Joint Surg( Br)* 1995;77-B:84-89