

■ *Original Article*

Nonsurgical Method of Treatment of Childhood Phimosis with the use of Topical Betamethasone

B K Rai

Department of General Practice & Emergency Medicine

Abstract

Background: Topical steroid application is an effective alternative to circumcision for the treatment of infant and childhood phimosis. **Materials & method:** prospective study in 42 boys under 13 years of age, with non retractable foreskin with asymptomatic and past history of disease in grade 4 to 6 weeks treatment. the success was defined as full and free retraction, or easy retraction limited only by congenital adhesions to the glans. **Results:** Forty-two patients completed the treatment. Successful retraction was achieved in 14 (33.33%) at 4 weeks and 32(76.19%) after 6 weeks of application. No adverse systemic side effects were noted. Two patients had failed treatment and were enrolled for circumcision. Two patients refused further treatment. Six patients were lost in subsequent to follow-up. **Conclusion:** Betamethasone 0.10% ointment is an effective alternative, non surgical method of the treatment for the childhood phimosis.

Keywords: Childhood phimosis, betamethasone

Introduction

Phimosis is a physiological condition in neonates due to adhesion between the foreskin and the glans. Chronic infection due to poor hygiene is responsible for most cases of childhood phimosis.⁸

Physiological adhesion between the foreskin and the glands may persist until 6 years of age or more, giving the false impression that the prepuce will not retract. Rolling back the prepuce cause its inner lining to pout and the meatus comes into view.

In the true phimosis, the prepuce will not retract without fissuring. In these cases, the aperture in the prepuce may be so tight as to cause urinary obstruction.⁹

In Nepal, the exact incident of Phimosis, has not yet been reported. In U.K. the incident of pathological phimosis is 0.4 cases/1000 boys per year.¹⁷

Phimosis is the leading cause of UTI, balanities and balanoposthitis. Phimosis give rise to impaired sexual sensation. It is a predisposing factor for stone formation and carcinoma of penis in later life.⁹

So once the phimosis is identified, it should be treated, without delay. The options of treatment are either surgery or medical treatment.

Circumcision is the traditional treatment of choice for phimosis or unretractable foreskin, although it is not always desired by parents or surgeons.¹⁰

Apart from religious, social or cultural reasons, medical approach is the first line of treatment. Medical method of treating Phimosis is popular all over the world. To date there has been no study in Nepal to evaluate medical treatment. Moderately potent topical steroid has been chosen to conduct a prospective study to evaluate its efficacy.

The Hypothesis of the research study

Betamethasone 0.10% is the first line of treatment in infant & childhood phimosis as an alternative to circumcision.

The main aim of research study

To evaluate the efficacy of the Betamethasone 0.10% cream in infancy & childhood phimosis.

Methodology

This observational prospective study was conducted in SRC Patan hospital. All Phimosis cases referred

Address for correspondence:
Dr Bijendra Kumar Rai, Associate Professor
Department of GP & EM, BPKIHS
Email: dr_bijendra@hotmail.com

from under – 14 clinic and PRC, were reviewed and carefully assessed for suitability for treatment. The suitable patients with Phimosis were enrolled. The study was conducted from 1st Jan 2002 to 3rd Oct 2002. (B.S. 058-10-17 to 059-6-17). An education package was conducted with patients and/or parents. Within the 9 month period 49 patients were registered.

Inclusion Criteria

- Children up to 13 years of age.
- Grade 4 and grade 5 Phimosis. (Grading of the Phimosis according to prepuce retractability)

Exclusion Criteria

- Features of UTI and/or local infection.
- Patients with buried penis.
- Congenital abnormalities like hypospadiasis.

Ethical Consideration

- Institutional consent was obtained from Patan Hospital Director and head of SRC Department.
- The consent of parents or patients was obtained
- Information confidentiality was maintained.

Education package

tube of Betamethasone 010% ointment to be used in case of recurrence of phimosis.

Topical steroid for phimosis in children

Date: Hosp No. Completed by:
 Name: Age: Contact No:
 H/O UTI Y/N Balanoposthisis Y/N Other:

Degree of phimosis	5	4	3	2	1	
Result At 2 wk date	5	4	3	2	1	0
At 4 wk date	5	4	3	2	1	0
At 6 wk date	5	4	3	2	1	0
F/U 12 wk date	5	4	3	2	1	0
Dropout date	Cause					
Circumcision date	Cause					

Note:

1. Betamethasone ointment 0.10% is used, twice daily for 6 wk

2. Degree of Phimosis:

5. Absolutely no retraction.
4. Slight retraction leaving a gap between the tip of the prepuce and the glans.
3. Retraction just sufficient to see the glandular meatus.
2. Retraction exposing but tight.
1. Full retraction but tight.

1. To instruct to thoroughly clean the prepuceal part.
2. To apply the thin layer of Betamethasone ointment on the lightest part of prepuce, twice a day.
3. To instruct to retract foreskin as possible without causing discomfort after 14 days onwards.
4. To come for regular follow up every 2 weeks till 6 weeks and the last follow up in 12 weeks.
5. To review the patients at each follow up and chart the variation in the grading of phimosis.

The treatment was deemed successful if the prepuce was easily and fully retractable. If the 4 weeks period treatment was successful, application of the assessment of the grading was done at completion of the 6 weeks course. All patients were planned to follow-up at 12 weeks after completion of treatment. Every parent and patient were followed to keep a

0. Full and free retraction or easy retraction limited only by congenital adhesions to the glans.

3. Inclusion-children up to 13 yrs. Exclusion-features of UTI. local infection.

Results

From 1st Jan 2002 to 3rd Oct 2002 (B.S. 058.9.7 to 059.6.17.) 49 patients were registered. Only 42 patients were available for analysis. Seven patients out of 49 were fit for treatment.

Out of 42 patient, 25 (59.52%) had previous history of disease i.e. balanitis (n=9), balanoposthesis (n=7), ballooning of prepuce (n=5) and UTI (n=4). These are classed as symptomatic patients. Their mean age was 5.5 years.

At initial presentation 24 patients had grade 5 phimosis, 18 had grade 4 phimosis.

The overall, successful retraction of the foreskin was achieved in 14/42 (33.33%) at 4 weeks. After a further 2 weeks of treatment the success rate increased to 33/42 (76.19%). In subgroup analysis the success rate was 68% (17/25) for symptomatic patients and 88.23% (15/17) for asymptomatic patients. The difference in success rate between these two subgroups was not statistically significant, where (p=>0.05).

The Grade 5 patients had lower success rate than grade 4 patients. Similarly the symptomatic patients i.e. past history of balanitis, balanoposthesis and other had poor success rate than asymptomatic patients.

The patients under 5 years of age, the success rate is 96%(22/23) and above 5 years of age the success rate is 58%(11/19). However there were no systemic side-effects were observed in any of the patients.

In this study two patients had failed treatment and subsequently underwent circumcision. Two patients refused further treatment and six patients were lost to follow-up. Only fifteen patients were available for follow-up at 12 weeks and recurrence was unremarkable.

Data Analysis

Table 1

Age	No. of Patient
4-6	3
7-9	3
10-12	2
1-3	7
4-6	11
7-9	7
10-12	7
13	2

Out of 42 patients most patients belong to 4 to 6 years of age.

Table 2

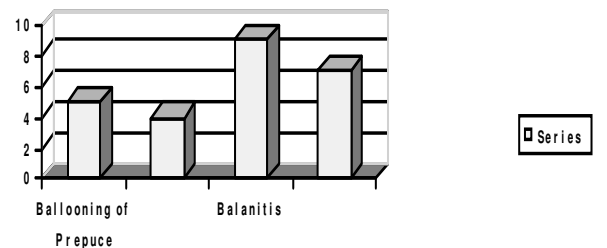
Patients	Age	%
Asymptomatic	17	40.47%
H/O of Symptomatic	25	59.53
Total	42	100%

Out of 42 patients, 17 patients were Asymptomatic & 25 patients had P/H of Symptomatic (57% and 43 % respectively).

Table 3

Symptomatic	No.	%
Ballooning of Prepuce	5	20%
H/O of Symptomatic	4	16%
Balanitis	9	36%
Balanoposthitis	7	28%
Total	25	100%

Patients analyzed according to P/h of Symptomatic



Out of among the P/h of Symptomatic patients, 9- patients had balanitis 7- patients had balanoposthitis.

Table 4

Grade	No.	%
4	18	44%
5	24	56%
Total	25	100%

Out of 42 patients 18 patients were Grade 4 and 24 patients belong to Grade 5.

Table 5

Grade	Asymptomatic	P/H Symptomatic	Total
4	7	10	17
5	10	15	25

Grade 4 & Grade 5 patient analyzed according to Asymptomatic & P/h of symptoms.

1)

Patients	Success	%	Non-success	%	Total
Symptomatic	17	68	8	32	25
Asymptomatic	15	88	2	11.76	17
Total	32	76.19	10	23.80	42

“Over all success rate at the end of 6 weeks treatment, in asymptomatic and symptomatic patient.”
 There was no statistically significant different between Asymptomatic + symptomatic patients ($x^2= 2.27$, $p=>.05$) but clinically showed significant because the overall success rate is 76%.

2)

Grade	Success	%	Non-success	%	Total
Grade 4	4	22.22	14	77.77	18
Grade 5	10	41.66	14	58.33	24
Total	14		28		42

“The success rate of Betamethasone 0.10% ointment at 4 weeks for Grade 4 & Grade 5 phimosis.”

3)

Grade	Success	%	Non-success	%	Total
Grade 4	12	58.71	2	14.28	14
Grade 5	6	33.33%	8	66.66	14
Total	18		10		28

“The success rate of Betamethasone 0.10% ointment at 6 week Grade 4 & Grade 5 phimosis.”

Discussion

In this prospective study the use of topical steroid Bethamethasone 0.10% in phimosis is very effective. It has no systemic side-effect & is easy to apply. Betamethasone 0.10% ointment is the treatment of choice for phimosis when treatment is necessary. Previous prospective studies concerned with the conservative treatment of phimosis with topical

steroid strongly suggest that the Betamethasone 0.10% ointment is the choice of treatment alternative to surgery. In those prospective studies initial treatment was limited to 4 weeks while in the remainder a 2 weeks course was prescribed. The overall response rate of these six series after the initial course and completion of treatment was 86% and 90% respectively. (Table-1)

Table 1. A collective review of response rates following T.S treatment with half strength Betnovate in reported prospective study.

Authors	Wright	Golubovic et al	Monsour et al	Chu et al	Orsola	Elmore JM	Overall 1
Years	1994	1996	1999	1999	2000	2002	
Responders/total pt	84/111	19/20	16/24	263/276	112/137	20/27	514/595
(Response rate at 2-4 Wks	(76%)	(95%)	(67%)	(95%)	(82%)	(74%)	(86%)
(Response/total pt.		89/111	19/20	16/24	263/76	124/137	25/27
(Response rate at completion)	(80%)	(95%)	(67%)	(95%)	(90%)	(92%)	(90%)

The latest study which was done by Elmore JM, Baker 2002 October reported that the success rate of Betamethasone 0.12% ointment, was 74% effective in 20/27 in 4 to 6 weeks duration Lee KS. KOIJUMI J, et al 2001 September, reported that

85.5% success rate with 0.12% Betamethasone ointment.

In my study the overall rate is 76% at the end of six weeks. Although the sample size is small, this study suggests a clinically significant outcome with the

topical use of potent Betamethasone 0.10% ointment in infant & childhood phimosis. This is consistent with the overseas literature.

The age of patient, presence or absence of UTI, Balanoposthitis and other problem in the past, grade of phimosis, and proper education package all play a crucial role of childhood phimosis. Gentle retraction and good penile hygiene is an integral part of treatment as well.

The topical use of Bethamethasone 0.10% avoids the disadvantages, trauma and potential complications of penile surgery, including anaesthesia-related risk. Bethamethasone 0.10% ointment is the most cost effective management for treating phimosis.

In U.S.A the T.S therapy costing between \$758 & \$800 and the circumcision costs between \$ 3009 & \$3241 per case.

In Nepal, it costs NC Rs. 35 to Rs. 45 case for T.S therapy and in circumcision it costs N.C Rs. 5000 to Rs. 7000 per case in private sectors, and N.C Rs. 1500 to Rs. 3000 in government hospital.

Limitations

1. The children up to the age of 13.
2. The children having grade 4 & grade 5 phimosis.
3. Small sample size limits the statistical analysis of difference between different groups of patients.

Conclusions

The present study shows that topical use of Betamethasone 0.10% ointment applied twice daily for 4 to 6 weeks is a cost effective non surgical method of treatment in infant and childhood phimosis.

Recommendations

The potent T.S Betamethasone 0.10% ointment has been recommended in the treatment of infant in childhood phimosis. It is easy to apply and has no systemic side effects.

The treatment can be conducted at H.P., H.C as well so this should be encouraged and made available at these facilities.

References

1. Stehr M, Schuster T, Dietz HG, Joppich I Klin paediatr 2001 Mar-Apr; 213(2) 50-5
Circumcision Criticism of the routine.

2. Klyer H; Mortensen SO, Klarskov OP, Christiansen.P. "Treatment of Phimosis with a steroid cream in boys" Ugeskr Laeger 2001 Feb 12, 163 (7): 922-4.
3. Berdeu D, SauzeL, Ha-Vinh P, Blum-Boisgard C. "Cost effectiveness analysis of treatment for phimosis" BUJ Int-2001 Feb; 87(3): 239-94.
4. Orsola A, Caffaratti J, Garat JM. "Conservative treatment of phimosis in children using a topical steroid". Urology 2000 Aug 1, 56(2); 307-10
5. Monsour MA, Rabinovitch HH, Dean Ge. Medical management of phimosis in children: Our experience with topical steroid. J. Urol. 1999; 162:1162-4.
6. Pless TK, spjeldnae N, Jorgensen TM. "Topical steroid in the treatment of Phimosis in children. "Ugeskr Laeger 1999 Nov 22, 161(47): 6493-5.
7. McEvoy GK. Cortcosteroid, general statement. Bethesda; American Society of Health System Pharmacists Inc, 1999; Ch68.
8. Chu CC, Chen KC, Diao GY. Topical steroid treatment of phimosis in boys. J. Urol. 1999;162861-3
9. Baley and love's. 23rd edition. The urethra and penis.
10. Van Howe RS "Cost effective treatment in Phimosis" Paediatric 1998 oct; 102(4):E 43
11. Simpson ET Barraclough P. "The management of the paediatric foreskin" 1998 May, 27(5):381-3
12. Elmore JM, Baker LA, Snodgrass WT. "Topical steroid therapy as an Alternative to circumcision for Phimosis in boys younger than 3 years. "J. Urol. 2002 Oct., 168(4):1746-5.
13. Webster TM, Leonard MP "Topical steroid therapy for Phimosis. "J. Urol. 2002 Apr, 9(2):1492-5.
14. Lee KS, Koizumi T, Nakatsuji H; et. al. "Treatment of Phimosis with Betamethasone ointment 0.10% in children" 2001 Sep;92(6):619-23.
15. Ter Meulen PH, Delaere KP. "A conservative treatment of Phimosis in boys" Urol. 2001 Aug;40(2):196-9.
16. Ng WT, Fan N et al "Treatment of childhood Phimosis with a moderately potent topical steroid." ANZ J. Surg 2001 Sep.; 71(9):541-3.