

■ *Original Article*

Fracture of Lateral end of Clavicle with Coracoclavicular Ligament Rupture Treated with Coracoclavicular Screw and Stainless Steel Wire-A Series of Eleven Cases

Pashupati Chaudhary, N Karn, BP Shrestha, GP Khanal, R Rijal, SR Paneru
Department of Orthopaedics, B.P.Koirala Institute of Health Sciences, Dharan, Nepal

Abstract

Background: Various treatment options have been described in the literature for treatment of lateral end of clavicle with no single method is superior to another. **Objectives:** To assess fracture stability, pain at fracture site and functional outcome. **Methods:** This is retrospective interventional (case series) study done in the department of Orthopaedics at B.P.Koirala Institute of Health Sciences, Dharan from January 2007 to December 2009 over a period of 2 years. The study enrolled 11 patients aged 18-35 years who had presented with fracture lateral end of clavicle. All patients underwent open reduction and internal fixation of fractures with coracoclavicular screw and stainless steel wire. **Results:** The study was comprised of 8 men and 3 women. Average patient's age was mean+_{SD} 27.2 years (range: 18-35 years). The common mechanism of injury was a fall on outstretched hand with the shoulder in extension and abduction (6 patients) followed by direct violence (5 patients). Most of the patients were right handed. All patients were returned to the pre-injury work level with no pain or dysfunction. There was no pseudoarthrosis, infection, neurovascular damage, or skin necrosis or implant failure. **Conclusion:** Coracoclavicular screw/ SS wire fixation is a relatively simple, reliable, and safe technique of indirect open reduction and internal fixation of the type II distal clavicle fracture with a low complication rate.

Key words: clavicle, coracoclavicular screw, stainless steel wire

Introduction

Clavicle fractures are common bony injuries in all age groups, accounting for 4%-15% of all fractures. Lateral 1/3rd clavicular fractures account for 1/4 of all clavicle fractures. Non union occurs in roughly 1/3rd of cases, however only 1/3rd of these cases have a symptomatic non union requiring operative intervention^{1,2}.

Treatment is controversial, various methods both non-operative and operative have been described in the literature. The majority of clavicular fractures can be treated conservatively with excellent results, and

open reduction and internal fixation is rarely indicated. However, operative treatment is indicated for clavicle pseudarthrosis, open fractures, acromioclavicular joint dislocations, neurovascular injury, severe displacement and inability to tolerate closed reduction and immobilization and associated coracoclavicular ligament rupture, floating shoulder with displaced clavicular fracture and an unstable scapular fracture, and unstable Neer type II distal third clavicle fractures^{3,4,5,6,7}

Operative treatment has advantages in fracture lateral end of clavicle with coracoclavicular ligament rupture over conservative treatment in terms of stability, fracture site morbidity, pain, stiffness and early functional recovery. There are few studies in the literature treating fracture lateral end of clavicle with coracoclavicular ligament rupture with

Address for correspondence:
Dr. Pashupati Chaudhary, Assistant Professor
Department of Orthopaedics, B.P.Koirala Institute Of Health Sciences, Dharan
Phone: 00977-25-525555-3164
E-mail: chaudharypashupati@yahoo.com

coracoclavicular screw and stainless steel wire and virtually no study in Nepal

Aims and Objective

The aim of the study was to treat fracture lateral end of clavicle with coracoclavicular ligament rupture with coracoclavicular screw and stainless steel wire and assess in term of

- Fracture stability
- fracture site morbidity
- Pain at fracture site
- Bony union
- functional recovery
- Complications of surgery

Materials and methods

Study site: All patients with fracture lateral end of clavicle that met the criteria for operative interventions(CC screw and stainless steel wire) presenting to department of Orthopaedics, B.P.Koirala Institute of Health Sciences, Dharan and giving informed consent were included in the study.

Study design: retrospective interventional case series

Exclusion Criteria

The patients with undisplaced fractures, multiple injuries, polytrauma, associated neurovascular injury, active infection, not giving informed written consent, pathological fracture, age less than 18 years with immature skeletal were excluded from the study.

Post-operatively all patients were immobilized in arm pouch sling for 2 weeks. Wounds were inspected on 3rd post operative day and sutures were removed on 14th day. The average follow-up was 6th months. Patients were followed-up on 2nd week, 6th week, 12th week and 24th week and was assessed for fracture stability, evidence of infection, pain at fracture site by visual analogue scores(VAS Score)and , American Shoulder and Elbow Surgeons shoulder index, functional outcome using DASH score.

Operative technique

The surgery was performed under general anaesthesia with the patient in a “beach-chair” position using a vertical incision over the coracoid process. If not already torn, the fascia joining the deltoid to the trapezius was divided at right angles to the skin incision. The clavicle was exposed subperiosteally at the level of the coracoid and the base of the coracoid was exposed between two small

retractors. Coracoclavicular screw was done in 5 cases and stainless steel wire fixation was done in 6 cases. The screw was placed vertically through the proximal fragment of the clavicle, attempting penetration of both cortices of the base of the coracoid (Figure 1,2A,B). Depth gauze determined the length of the 6.5-mm cancellous screw to be used. Perioperative radiographs were performed to ensure that the screw was introduced properly in the coracoid. The screw was tightened until the fracture, which was not exposed, was felt by palpation to be reduced. The torn ends of the coracoclavicular ligaments are freed up and tagged with three No.1 vicryl sutures. The sutures are tied and then another half turn is applied to the screw, which takes any tension off the sutures. Reduction of the acromioclavicular joint dislocation was accomplished and fixed with K-wires. Then, the fascia between deltoid and trapezius was meticulously repaired. Finally, the wound was closed over drain suction. In 6 cases in which SS wire fixation was done, drill holes were made both in clavicle and coracoid process. SS wires were passed through holes and tightened till reduction is achieved(Fig 3,a,b) Following the operation, the arm is placed in a arm pouch sling for two weeks. After two weeks, the sling is discontinued and the patient is permitted to use the arm for daily activities except for lifting, pulling, and pushing for 6 weeks. The coracoclavicular screw is removed under local anaesthesia at 3 months postoperatively, and the patient is instructed not to perform any heavy lifting, pushing, pulling or participate in contact sports for 12 weeks.

Results

The study was done in the department of Orthopaedics at B.P.Koirala Institute of Health Sciences, Dharan from January 2007 to December 2009 over a period of 2 years. Eleven(11) patients were treated operatively for unstable type II distal clavicular fracture(fracture lateral end of clavicle with coracoclavicular ligament rupture)[Fig: 1A] from January 2007 to December 2009. The study was comprised of 8 men and 3 women. Average patient's age was mean+_{SD} 27.2 years (range: 18-35 years). The common mechanism of injury was a fall on outstretched hand with the shoulder in extension and abduction (6 patients) followed by direct violence

(5 patients). All fractures were displaced and attempted closed reduction had failed. Most of the patients were right handed. Coracoclavicular screw was done in 5 cases[Fig:1,2 A,B] and stainless steel wire fixation was done in 6 cases[Fig:3 a,b] All the patients were reviewed clinically and radiologically after an average of 6 months At the latest follow-up examination, the American Shoulder and Elbow Surgeons shoulder index was improved (mean, 97 points; range: 90-100 points). DASH score were also improved. All patients were returned to the pre-injury work level with no pain or dysfunction. Bone union occurred at a mean of 7 weeks postoperatively (range: 6-9 weeks) [Figure 3 ,B]. Two patients showed radiologically ossification of the acromioclavicular joint with no clinical symptoms. There was no pseudarthrosis, infection, neurovascular damage, or skin necrosis or implant failure

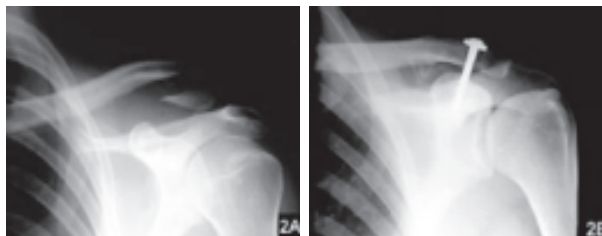


Figure 1: AP radiograph of the left shoulder shows a displaced fracture of the left distal clavicle (A). Excellent clinical and radiographic result 3 months after open reduction and internal fixation with a coracoclavicular 6.5-mm cancellous screw (B). The patient had no pain and normal range of shoulder motion

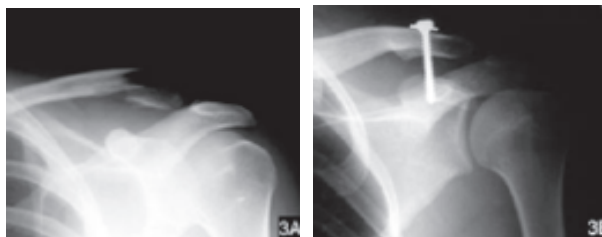


Figure 2: AP radiograph of the left shoulder shows a displaced fracture of the left distal clavicle (A). Satisfactory postoperative radiograph shows union of the fracture 12 weeks after open reduction and internal fixation with a coracoclavicular 6.5-mm cancellous screw (B).

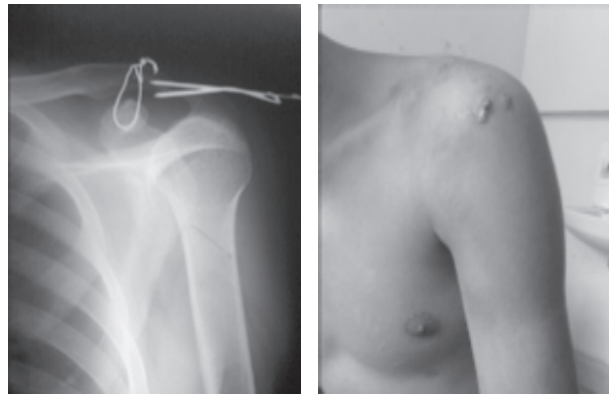

Figure:3 SS/K-wire wires fixation

Discussion

In the present series, fixation with a 6.5-mm cancellous coracoclavicular screw gave satisfactory clinical and radiological results. The coracoclavicular screw has been used initially for the treatment of acromioclavicular dislocations.^{23,24} Also temporary screw fixation for the treatment of type II lateral fracture of the clavicle has been previously reported in small series.^{25,26} Ballmer and Gerber²⁵ treated 5 consecutive Neer's type II fractures of the distal third of the clavicle treated using a temporary Bosworth-type screw. There were no surgical complications and bone union occurred uneventfully within 9 weeks in all cases. Shoulder function was restored to the pre-injury level. Using the same technique, Yamaguchi et al²⁶ treated 11 consecutive Neer's type II unstable distal third clavicle fractures. In all cases, fracture healing occurred within 10 weeks and the shoulder function was restored to the pre-injury level.

Operative methods using K-wires frequently are impaired by wire-migration and therefore require a longer period of external immobilization. Independent of the type of surgery, objective and subjective results were equally good. Complications have been reported using either an intramedullary pin or a dynamic fixation method to bring the proximal clavicular segment to the distal segment. Pinning with K-wires has been associated with migration resulting in serious complications including death or quadriplegia after intraspinal migration.^{15,16} Extra-articular tension band fixation using K-wires and cerclage wire does not fully protect from pin migration.¹ The method is technically demanding and

general anaesthesia usually is required for implant removal.

Internal fixation using plates requires wide exposure and may devascularize the clavicle, and often is impractical because of the small distal fragment.⁶ Plating is associated with stress-shielding and the potential for refracture after implant removal, which requires general anaesthesia. The Balsler plate, which was originally designed for the treatment of acromioclavicular dislocations, has the disadvantages of plate fixation with additional complications such as implant failure and subacromial pain.⁵

The use of a transarticular implant for acromioclavicular dislocations appears to lead to a 10% incidence of osteoarthritis of the acromioclavicular joint.^{4,7,23} This complication cannot be anticipated to be much lower in the treatment of fractures if large implants are used.⁴

The deforming forces and the high incidence of non-union have led many authors to recommend primary open reduction and internal fixation for type II distal clavicular fractures.^{2,3} Various techniques have been recommended.^{1,2,4-7} However, most of these reports are based on a series of patients treated by different techniques. The rarity of the fracture and the lack of documentation of the results of a particular technique account for the fact that no single operative method has become generally accepted.^{1,2,4-7}

This study analyzed the treatment of type II unstable distal clavicle fractures (lateral end of clavicle with coracoclavicular ligament rupture) with special attention to the stability and rigidity of the fixation and final functional outcome.^{3,4}

Conclusion

Coracoclavicular screw/ SS wire fixation is a relatively simple, reliable, and safe technique of indirect open reduction and internal fixation of the type II distal clavicle fracture with a low complication rate.

References

1. Albrecht HU, Bamert P. The clavicular fracture: therapy and complications [in German]. *Helvetica Chirurgica Acta*. 1982; 48:571-583.
2. Ring D, Jupiter JB, Miller ME, Ada JR. Fractures of the clavicle. In: Browner BD, Jupiter JB, Levine AM, Trafton PG, eds.

- Skeletal Trauma*. Vol 2. 2nd ed. Philadelphia, Pa: WB Saunders; 1998:1670-1694.
3. Neer CS II. Fractures of the distal third of the clavicle. *Clin Orthop*. 1968; 58:43-50.
4. Muller ME, Allgower M, Schneider R, Willenegger H. *Manual of Internal Fixation*. 3rd ed. Berlin: Springer-Verlag; 1991.
5. Dittmer H, Jauch KW, Wening V. Management of acromioclavicular dislocations with the Balsler plate [in German]. *Unfallheilkunde*. 1984; 87:216-222.
6. Eskola A, Vainionpaa S, Patiala H, Rokkanen P. Outcome of operative treatment in fresh lateral clavicular fracture. *Ann Chir Gynaecol*. 1987; 76:167-169.
7. Neviasser RJ. Injuries to the clavicle and acromioclavicular joint. *Orthop Clin North Am*. 1987; 18:433-438.
8. Tossy JD, Mead NC, Sigmund HM. Acromioclavicular separations: useful and practical classification for treatment. *Clin Orthop*. 1963; 26:111-119.
9. Rockwood CA Jr, Young DC. Disorders of the acromioclavicular joint. In: Rockwood CA Jr, Matsen FA, eds. *The Shoulder*. Philadelphia, Pa: WB Saunders Co; 1990:413-476.
10. Richards RR, An K-N, Bigliani LU, et al. A standardized method for the assessment of shoulder function. *J Shoulder Elbow Surg*. 1994; 3:347-352.
11. Graig EV. Fractures of the clavicle. In: Rockwood CA, Matsen FA, eds. *The Shoulder*. Vol 1. Philadelphia, Pa: WB Saunders Co; 1990:367-412.
12. Edwards DJ, Kavanagh TG, Flannery MC. Fractures of the distal clavicle: a case of fixation. *Injury*. 1992; 23:44-46.
13. Brunner U, Habermeyer P, Schweiberer L. Special status of lateral clavicular fracture [in German]. *Orthopade*. 1992; 21:163-171.
14. Poigenfurst J, Baumgarten-Hofmann U, Hofmann J. Unstable fractures of the lateral end of the clavicle and principles of their treatment [in German]. *Unfallchirurgie*. 1991;17:131-139.
15. Fueter-Tondury M. Migration of the wire after osteosynthesis [in German]. *Schweiz med Wochenschr*. 1976; 106:1890-1896.
16. Regel JP, Pospiech J, Aalders TA, Ruchholtz S. Intraspinal migration of a Kirschner wire 3

- months after clavicular fracture fixation. *Neurosurg Rev.* 2002; 25:110-112.
17. .Kao FC, Chao EK, Chen CH, Yu SW, Chen CY, Yen CY. Treatment of the distal fracture using Kirschner wires and tension-band wires. *J Trauma.* 2001; 51:522-525.
 18. .Moneim MS, Balduini FC. Coracoid fracture as a complication of surgical treatment by coracoclavicular tape fixation. A case report. *Clin Orthop.* 1982; 168:133-135.
 19. .Papagelopoulos PJ, Giannarakos DG, Lyritis GP. Suitability of biodegradable polydioxanone materials for the internal fixation of fractures. *Orthop Rev.* 1993; 22:585-593.
 20. .Mall JW, Jacobi CA, Philipp AW, Peter FJ. Surgical treatment of fractures of the distal clavicle with polydioxanone suture tension band wiring: an alternative osteosynthesis. *J Orthop Sci.* 2002; 7:535-537.
 21. .Chen CH, Chen WJ, Shih CH. Surgical treatment for distal clavicle fracture with coracoclavicular ligament disruption. *J Trauma.* 2002; 52:72-78.
 22. .Flinkkila T, Ristiniemi J, Hyvonen P, Hamalainen M. Surgical treatment of unstable fractures of the distal clavicle: a comparative study of Kirschner wire and clavicular hook plate fixation. *Acta Orthop Scand.* 2002; 73:50-53.
 23. .Hellmich A, Sievers U. Surgical management of acromioclavicular joint separation with transcutaneous Kirschner wire fixation. Results of follow-up in 45 patients [in German]. *Aktuelle Traumatologie.* 1988; 18:9-13.
 24. .Bosworth BM. Acromioclavicular separation: new method of repair. *Surg Gynecol Obstet.* 1941; 73:866-871.
 25. .Ballmer FT, Gerber C. Coracoclavicular screw fixation for unstable fractures of the distal clavicle. A report of five cases. *J Bone Joint Surg Br.* 1991; 73:291-294.
 26. .Yamaguchi H, Arakawa H, Kobayashi M. Results of the Bosworth method for unstable fractures of the distal clavicle. *Int Orthop.* 1998; 22:366-368.