



A CASE OF NODULAR CHEST SHADOWS

CASE REPORT, Vol-5 No.2

Asian Journal of Medical Science, Volume-5(2014)

<http://nepjol.info/index.php/AJMS>

¹Pijush Kanti Mandal, ²Arpan Kumar Dey, ²Subhraprakash Pramanik, ³Somnath Dasgupta, ⁴Tanmoy W. Momin. ¹Senior Resident, Department of General Medicine, ESI Post-Graduate Medical Education and Research, Maniktala, Kolkata, West Bengal, India ²Senior Resident ³Professor ⁴ Post-graduate Trainee, Department of General Medicine, Burdwan Medical College & Hospital, Burdwan, West Bengal, India.

ABSTRACT

CORRESPONDENCE :

Dr. Pijush Kanti Mandal
Vill: Haripur,
Ekborna,
Malda,
West Bengal, India,
Pin-732204
Mob-+919433116968
Email:pkmbmoh@gmail.com.

Pulmonary Tuberculosis is still very common in India as well as in other developing countries. The lesions are usually woolly, ill-defined opacities and may be associated with cavities. Multiple nodular discrete bilateral opacities affecting the lungs from base to apex, more in the lower zones is unusual in Pulmonary Tuberculosis. We report a case of a 55 year old male with bilateral multiple nodular opacities of varying sizes as evident on chest radiography presented with dry cough and one episode of haemoptysis, which initially raised a possibility of lung metastasis. CT guided FNAB from left lung lesion showed chronic granulomatous lesion likely to be of Tubercular aetiology. Sputum for Acid Fast Bacilli (AFB) was negative but the culture for AFB was positive and the patient responded to treatment with Anti-tubercular drugs (ATDs).

Key words: Pulmonary Tuberculosis, Nodular Chest Shadows, Haemoptysis, FNAB.

*“Multiple nodular shadows
in lung as pulmonary
tuberculosis”*

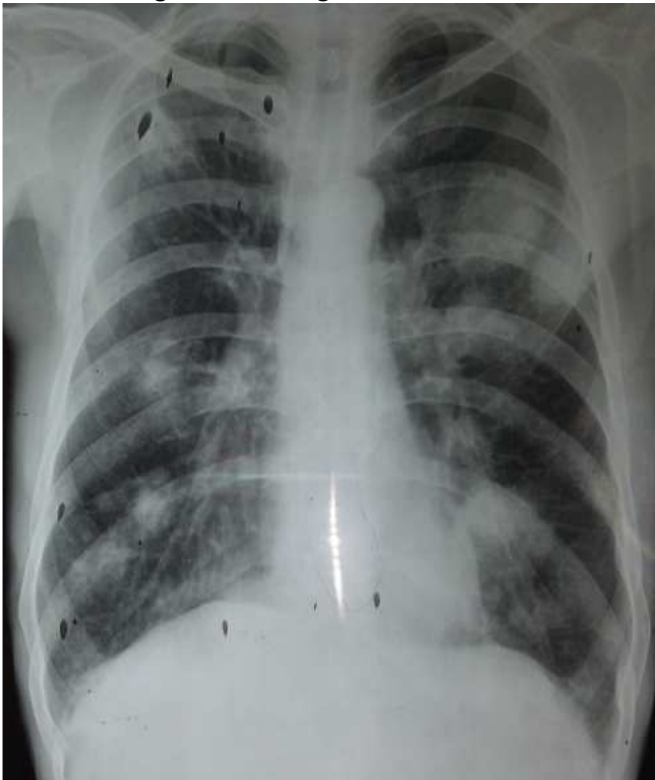INTRODUCTION

A 55 years non-diabetic, normotensive, non-alcoholic, chronic smoker (35 pack-years), businessman of Burdwan district, West Bengal, India presented with cough with scanty, mucoid, non-foetid expectoration along with irregular bouts of low grade intermittent fever without any chill & rigor for last 2 years along with anorexia & gradual loss of body weight with single episode of haemoptysis 2 months ago. There was no H/O breathlessness, chest pain, palpitation, hoarseness of voice, difficulty in deglutition etc.

On examination, BP was 130/80 mm of Hg, Pulse rate-84/min, regular, Respiration rate- 18/min, regular with mild pallor & normal vesicular breath sound with few scattered crepitation without any other significant findings.

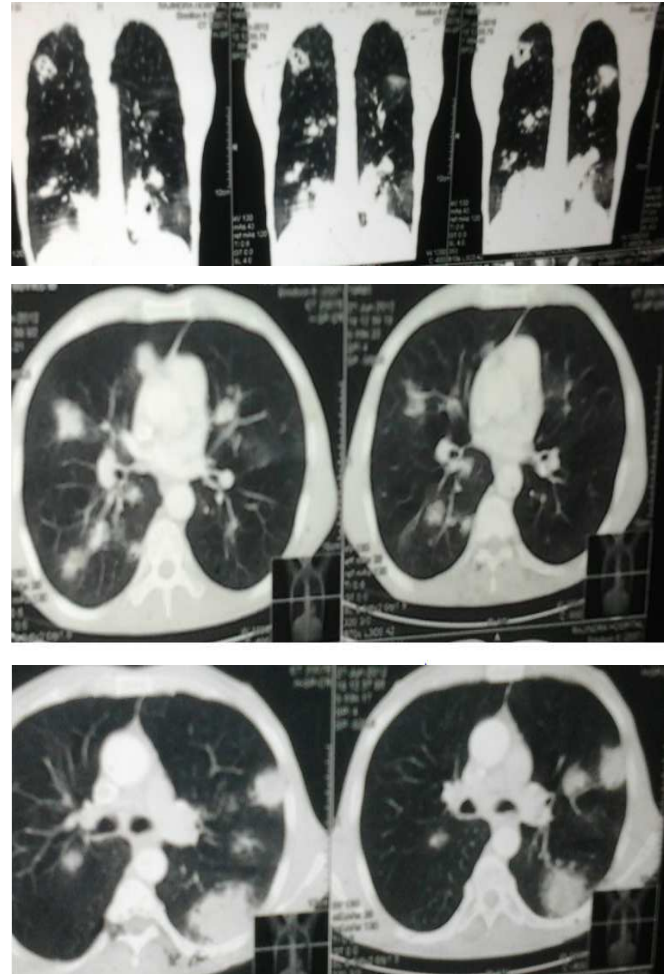
Investigation showed Hb 9.2 gm%, TLC 10,600/cu. mm, DLC = N70E5L25, ESR 40mm/hour, FBS 96mg%, urea 30mg%, creatinine 0.9 mg%, LFT & PSA was within normal limits.

Chest X-ray revealed multiple nodular opacity of varying sizes involving both the lung fields.



Pic 1. Chest X-Ray PA view

A provisional diagnosis of secondaries in the lung was made and further investigations advised. CT thorax shows multiple enhancing heterogenous masses of variable sizes scattered throughout both lung parenchyma more in bilateral lower lobes.



Pic 2. Computed tomography scan thorax

A provisional diagnosis of secondary deposits in the lung was made and Fine Needle Aspiration Biopsy (FNAB) advised. CT guided FNAB from left lung lesion showed chronic granulomatous lesion likely to be of Tubercular aetiology. Sputum for AFB was negative but the culture for Acid Fast Bacilli (AFB) was positive and the patient responded to treatment with Anti-tuberculous drugs (ATD).

DISCUSSION

Pulmonary tuberculosis is very common in India¹. It is classically described as affecting the apices of the lungs. The lesions are usually woolly, ill-defined opacities and may be associated with cavities. It is often unilateral.

Multiple nodular discrete bilateral opacities affecting the lungs from base to apex, more in the lower zones is unusual in Pulmonary Tuberculosis (PTB)². It is much more common with secondary deposits from primary carcinoma somewhere else.

There are some case reports of atypical presentation of pulmonary tuberculosis in India³. This report will also make the clinicians to rethink about the diagnosis of lung masses instead of atypical presentation of pulmonary tuberculosis as the later is still very common in this part of world with its various presentation.

REFERENCES

1. Sharma P R, Jain S, Bamezai R, Tiwari P K. Increased prevalence of pulmonary tuberculosis in male adults of sahariya tribe of India: A revised survey. *Indian J Community Med* 2010; 35:267-271.
2. Lawn, SD; Zumla, AI (2 July 2011). "Tuberculosis". *Lancet* 378 (9785): 57–72. doi:10.1016/S0140-6736(10)62173-3.
3. Patel A, Choudhury S. Pleural tuberculosis presented as multiple pleural masses: An atypical presentation. *Lung India* 2013; 30:54-56

Authors Contributions:

All authors contributed equally towards publication.

Conflict of Interest: None

Date of Submission: 7.10.2013

Date of Peer review: 28.10.2013

Date of submission of revised version: 8.11.2013

Date of peer review: 19.11.2013

Date of Acceptance: 20.11.2013

Date of Publication: 10.1.2014