



MADELUNG'S DISEASE : A CLINICAL CASE AND REVIEW OF LITERATURE

CASE REPORT AND REVIEW OF LITERATURE, Vol-4 No.4

Asian Journal of Medical Science, Volume-4(2013)

<http://nepjol.info/index.php/AJMS>

Naing Chaw Su. Department of Internal Medicine, Singapore General Hospital, Singapore

ABSTRACT

CORRESPONDENCE :

Dr Chaw Su NAING
Associate Consultant
Department of Internal
Medicine
Singapore General Hospital
Outram Road
Singapore 169608
email: naing.chaw.su@sgh.com.sg
m.sg
Phone: (65) 63265889

Madelung's disease is a rare disease of unknown aetiology. This disease usually affects middle-aged males from Mediterranean area with history of alcohol abuse. We describe an Asian male presented with typical features of Madelung's disease.

Key words: Madelung's disease, symmetric lipomatosis

*"Madelung's Disease:
uncommon disorder of
undetermined cause?"*

INTRODUCTION

Madelung's disease or Benign symmetric lipomatosis (BSL) is a rare disease characterised by symmetric prominent masses of adipose tissue on the neck, shoulders, arms and upper part of the trunk. Although it is benign in nature, fat can penetrate deeply in the surrounding tissues, involving vessels, nerves, and muscles and compressing trachea and oesophagus. The incidence is highest in the Mediterranean area, and this disease has a strong correlation with alcohol abuse. The only effective treatment option is surgical removal, with liposuction reserved for smaller lesion.

CASE REPORT

A 54 year old Indian man presented with 7-year history of bilateral, symmetrical, soft and slow growing swellings at the posterior of neck, upper back and hips (Figure 1). The patient became to have pain which disturbing his sleep for about two months due to gradual growth of the masses. The patient had a history of pulmonary tuberculosis with bronchiectasis and mycetoma in 2001 and heavy alcohol consumption for 30 years and was a smoker. Clinical examination revealed bilateral swelling at the posterior of neck, shoulders and hips regions. The masses were freely mobile and non-tender. There sizes were varied and maximum circumference of about 10 cm. There were no palpable lymph nodes. The blood investigations showed Aspartate Aminotransferase 46 U per litre, Alanine Aminotransferase 16 U per litre, albumin 26 g per litre, Triglycerides 2.23 mmol per litre. The magnetic resonance imaging of neck revealed multiple bilateral symmetrical intermuscular lipomatosis in the neck (Figure 2). A clinical diagnosis of Madelung's disease was made. Abstinence from alcohol was recommended for our patient. General surgeon opinion was sought in view of pain which gave him psychological stress.

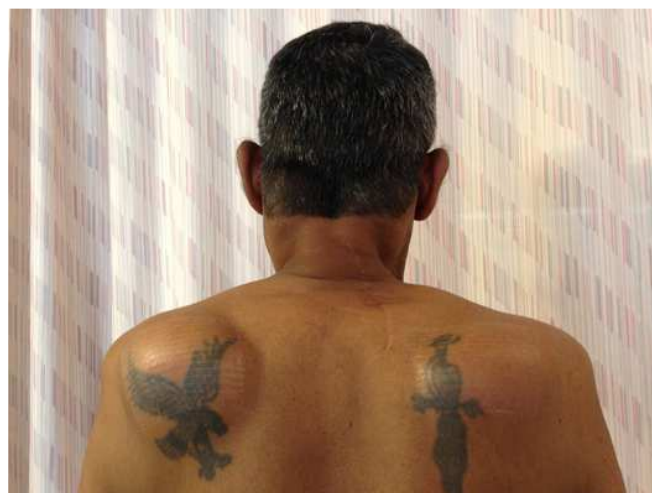

Fig 1. Bilateral symmetrical swellings at posterior of neck and scapular regions.

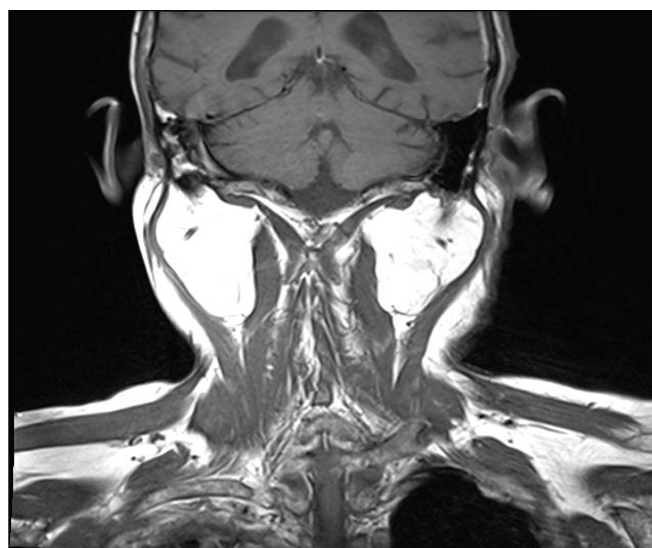


Fig 2. Magnetic resonance imaging revealed bilateral symmetrical lipomas.

DISCUSSION

Benign symmetric lipomatosis (BSL) was first described by Benjamin Brodie¹ in 1846, but Otto Madelung² reported the first case series of 33 patients with lipomas associated with alcoholism in 1888. The following year, Launois and Bensaude³ presented a new series of 65 patients with similar features. It is an extremely rare disorder characterized by massive symmetric deposition of

non-encapsulated adipose tissue in the head, neck and upper trunk. In reported case series, Madelung's disease usually affects middle age males from Mediterranean area with a history of alcohol abuse.

Our patient is from Asian country; however, he has strong history of alcohol usage. His phenotype was close to Type II phenotype descriptions which presence in both sexes and characterised by a massive female fat distribution in the upper back, shoulder, upper arms and hips and upper thigh region compared to the type I or diffuse lipomatosis of neck (horsecollarlipomata) and type III or a rare type with preponderance of lipomatosis in the thigh girth (gynecoid type).⁴

Madelung's disease deforms cosmetically in patients and in severe cases the advancement of fat deposition can cause compression syndrome such as dysphagia or dyspnoea or dysphonia or major vessels. Histological features includes typical, non-encapsulated adipose tissue, with extension to the surrounding structure characterised by adipocytes with spindle cell proliferation, suggestive of active, localised recruitment and proliferation of preadipocytes.⁵ Although the pathology is unknown, Kodish et al. have postulated that the fatty masses are due to hypertrophy of the brown adipose tissue.⁶ Several reports have shown that in BSL there are point mutations at the nucleotide position 8344 in the mitochondrial DNA or multiple or single mitochondrial DNA deletions, leading to an impaired function of the oxidative phosphorylation complex IV (cytochrome c oxidase).^{5,7,8}

Although the disorder is benign in nature, there are few cases reported on Madelung's disease associated with head and neck malignancy.^{9,10}

The treatment options are liposuction in patients with smaller masses and debulking surgery for patients with severe cosmetic deformity causing psychological stress or patients having aro

digestive tract or great vessels compression symptoms. Medical treatment is not effective.^{11,12}

REFERENCES

1. Brodie BC. Lectures Illustrative Of Various Subjects In Pathology And Surgery. London; Longman, Brown, Green and Longmans: 1846. Lecture XIV: On fatty or Adipose Tumors; pp. 275–282.
2. Madelung OW, Ueber Den Fetthals. Arch KlinChir 1888; 37:106-130.
3. Launois PE, Bensaude R. L' adenolipomatosesymetrique. Bull MemSoc Med Hosp Paris 1898; 1:298.
4. Busetto L, Strater D, Enzi G, Coin A, Sergi G, Inelmen EM, Pigozzo S: Differential clinical expression of multiple symmetric lipomatosis in men and women. Int J ObesRelatMetabDisord 2003; 27:1419–1422.
5. Klopstock T, Naumann M, Scchalke B, et al. Multiple symmetric lipomatosis: abnormalities in complex IV and multiple deletions in mitochondrial DNA. Neurology 1994; 44: 862-866.
6. Kodish ME, Alsever RN, Block MB. Benign symmetric lipomatosis: functional sympathetic denervation of adipose tissue and possible hypertrophy of brown fat. Metabolism 1974;23:937.
7. Campos Y, Martín MA, Navarro C, Gordo P, Arenas J. Single largescale mitochondrial DNA deletion in a patient with mitochondrial myopathy associated with multiple symmetric lipomatosis. Neurology 1996; 47: 1012-1014.
8. Becker-Wegerich P, Steuber M, Olbrisch R, Ruzicka T, Auburger G, Hofhaus G. Defects of mitochondrial respiratory chain in multiple symmetric lipomatosis. Arch Dermatol Res 1998; 290:652-655.
9. Eric S. Y. Chan, Anil T. Ahuja, Ann D. King, W. Y. Lau. Head and Neck Cancers Associated With Madelung's Disease, Annals of Surgical Oncology 1999;6(4): 395-397.
10. Tizian C, Berger A, Vykoupil KF. Malignant degeneration in Madelung's disease (benign lipomatosis of the neck): case report. Br J Plast Surg. 1983 Apr;36(2):187-189.
11. Mevio E, Sbrocca M, Mullace M, Viglione S, Mevio N. Multiple symmetric lipomatosis: a review of 3 cases. Case Reports in Otolaryngology 2012 ;2012:910526. Epub 2012 Jul 16. Available from <http://www.ncbi.nlm.nih.gov/pmc/articles/PMC3420511/>
12. N. A. C. Verhelle, J. L. Nizet, B. Van Den Hof, P. Guelinckx, O. Heymans, "Liposuction in benign symmetric lipomatosis: sense or senseless?" Aesthetic Plastic Surgery 2003; 27(4):319–321.