

# Torsion of paraovarian cyst: An enigma

Latika<sup>1</sup>, Pushpa Dahiya<sup>2</sup>

<sup>1</sup>Associate Professor, <sup>2</sup>Senior Professor and Head, Department of Obstetrics and Gynaecology, Pandit Bhagwat Dayal Sharma Post Graduate Institute of Medical Sciences, Rohtak, Haryana, India



Submission: 28-02-2024

Revision: 02-05-2024

Publication: 01-06-2024

## ABSTRACT

Paraovarian cysts are extremely rare and represent approximately 10% of adnexal masses. They are found commonly in women of reproductive age group and arise from the mesothelium. Paraovarian cyst is an entity which is rarely diagnosed preoperatively and often remains undiagnosed and missed out even by radiologists. Most often they remain asymptomatic but when large in size may present with complications such as torsion, hemorrhage, and infection. Isolated torsion of paraovarian cyst is extremely rare. Its diagnosis is often missed out leading to complications.

**Key words:** Parovarian cyst, Torsion, Emergency laparotomy, Necrosis, Surgical management, Adnexal mass

### Access this article online

**Website:**

<http://nepjol.info/index.php/AJMS>

**DOI:** 10.3126/ajms.v15i6.63239

**E-ISSN:** 2091-0576

**P-ISSN:** 2467-9100

Copyright (c) 2024 Asian Journal of Medical Sciences



This work is licensed under a Creative Commons Attribution-NonCommercial 4.0 International License.

## INTRODUCTION

Paraovarian cysts are extremely rare and represent approximately 10% of adnexal masses.<sup>1</sup> They are found commonly in women of reproductive age group<sup>2</sup> and arise from the mesothelium and their torsion is an important cause of acute abdomen.<sup>3</sup> In the absence of definitive diagnostic criteria, identification is often delayed resulting in irreversible damage to fallopian tubes. Common complications include torsion, hemorrhage, and rupture.<sup>1,4</sup>

## CASE PRESENTATION

A 24-year-old female, P1L1, reported in casualty with complaints of severe pain abdomen for 2 days, and it was non-radiating, not relieved by antispasmodics. There was no history of nausea, vomiting, fever, diarrhea, constipation, and fainting attacks. Her menstrual cycles were regular and there was no significant past, personal, and medical history. On general examination, her pulse rate was 110/min and blood

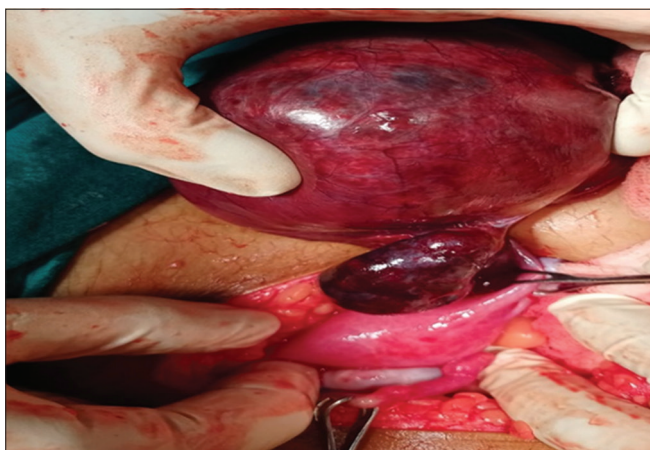
pressure was 100/70 mmHg. Per abdomen examination revealed marked tenderness. Bimanual examination showed uterus to be anteverted, normal size. There was a cystic and tender mass of 10×6 cm approximately in right fornix. On ultrasound, there was a 10 cm×7.8 cm×6.6 cm hyperechoic cystic structure with no internal vascularity. Probe tenderness was present. She was taken up for emergency laparotomy on suspicion of torsion ovarian cyst. Peroperatively, there was right paraovarian cyst of size 10×8 cm approximately which had torsion at its pedicle (Figure 1). Cyst and distal end of fallopian tube were necrosed and edematous. Paraovarian cystectomy and right-sided salpingectomy were performed (Figure 2). Post-operative period was uneventful and the patient was discharged on the 5<sup>th</sup> postoperative day.

## DISCUSSION

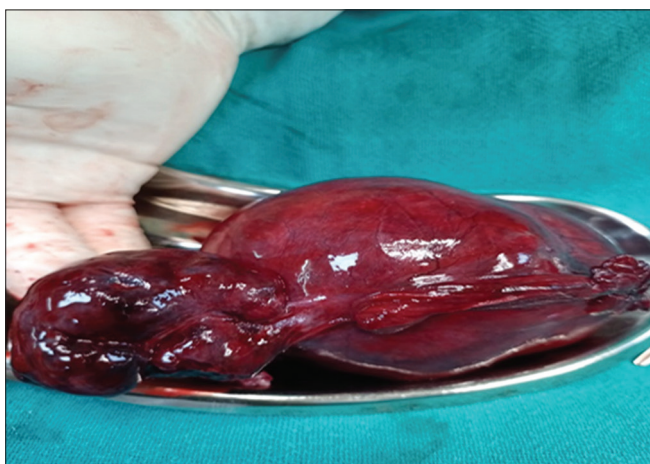
Paraovarian cyst is an entity which is rarely diagnosed preoperatively and often remains undiagnosed and missed out even by radiologists. Most often they remain

### Address for Correspondence:

Dr. Latika, Associate Professor, Department of Obstetrics and Gynaecology, Pandit Bhagwat Dayal Sharma Post Graduate Institute of Medical Sciences, Rohtak, Haryana, India. **Mobile:** +91-9467642578. **E-mail:** latika.duhan@gmail.com



**Figure 1:** Peroperative picture of right paraovarian cyst with torsion and dilated and necrosed fallopian tube



**Figure 2:** Gross specimen of paraovarian cyst with dilated and necrosed fallopian tube

asymptomatic but when large in size may present with complications such as torsion, hemorrhage, and

infection. They arise from broad ligament tissues, mostly as mesothelial cysts/paramesonephric cysts and rarely as mesonephric cysts. When surgery is performed on a female and paraovarian cysts are incidental findings, they are removed because of fear of their propensity to grow to large sizes and land patient up in complications and rare chance of malignancy.

## CONCLUSION

Isolated torsion of paraovarian cyst is extremely rare. Its diagnosis is often missed out leading to complications. Hence, one should be aware of this surgical emergency, thereby preventing significant patient morbidity.

## ACKNOWLEDGMENT

Nil.

## REFERENCES

1. Kiseli M, Caglar GS, Cengiz SD, Karadag D and Yilmaz MB. Clinical diagnosis and complications of paratubal cysts: Review of the literature and report of uncommon presentations. *Arch Gynecol Obstetr.* 2012;285(6):1563-1569. <https://doi.org/10.1007/s00404-012-2304-8>
2. Bilges K and Arab QR. Twisted right fimbrial cyst (Paraovarian cyst). *J Surg Pak.* 2009;14(4):182-183.
3. Thakore SS, Chun MJ and Fitzpatrick K. Recurrent ovarian torsion due to paratubal cysts in an adolescent female. *J Pediatr Adolesc Gynecol.* 2012;25(4):e85-e87. <https://doi.org/10.1016/j.jpag.2011.10.012>
4. Gupta A, Gupta P, Manaktala U and Khurana N. Clinical, radiological, and histopathological analysis of paraovarian cysts. *J Midlife Health.* 2016;7(2):78-82. <https://doi.org/10.4103/0976-7800.185337>

### Authors Contribution:

**L-** Concept, design, literature survey, prepared first draft of manuscript, implementation of study protocol, data collection, data analysis, manuscript preparation, and submission of case report; **PD-** Design of study, review case report, literature survey, data analysis, coordination, and case report revision.

### Work attributed to:

Pt. B. D. Sharma, Post Graduate Institute of Medical Sciences, Rohtak, India.

### Orcid ID:

Latika - <https://orcid.org/0009-0008-5348-7584>

Pushpa Dahiya - <https://orcid.org/0000-0003-4523-3310>

**Source of Funding:** Nil, **Conflicts of Interest:** None declared.