

# A comparative study of 0.4% ripasudil, 0.02% netarsudil, and 0.5% timolol in combination with 0.005% latanoprost in the medical management of primary open-angle glaucoma or ocular hypertension



Tirupati Nath<sup>1</sup>, Snigdha Sen<sup>2</sup>, Himanshu Kumar Yadav<sup>3</sup>, Dinesh Kumar Yadav<sup>4</sup>

<sup>1,3</sup>Professor, <sup>2</sup>Professor and Head, <sup>4</sup>Junior Resident, Department of Ophthalmology, Sarojini Naidu Medical College, Agra, Uttar Pradesh, India

Submission: 14-02-2023

Revision: 27-03-2024

Publication: 01-05-2024

## ABSTRACT

**Background:** Globally, it is expected that 111 million people will have glaucoma by 2040. Intraocular pressure (IOP) is the most crucial clinical risk factor for glaucoma onset and/or progression. **Aims and Objectives:** The aim of the study is to compare 0.4% ripasudil, 0.02% netarsudil, and 0.5% timolol in combination with 0.005% latanoprost in the medical management of primary open-angle glaucoma (POAG) or ocular hypertension (OHT). **Materials and Methods:** The prospective randomized clinical study was conducted on patients with mild-to-moderate POAG or OHT on a single prostaglandin analog (e.g., latanoprost) not achieving target IOP. Patients with narrow-angle glaucoma, any ocular surgery, and advanced glaucoma were excluded from the study. Patients were followed up at 15 days, 1 month, 2 months, and 3 months for a complete ophthalmic examination. **Results:** The maximum number of patients showed 41–60 years of age group. The male–female ratio was 1.8:1. A mild-to-moderate adverse event in the form of conjunctival hyperemia was seen in all groups. The mean reduction in IOP (mmHg) from baseline to 3 months in Groups A, B, and C is  $5.7 \pm 0.923$ ,  $7.11 \pm 0.832$ , and  $6.83 \pm 0.707$  mmHg, respectively. **Conclusion:** When given in combination with 0.005% latanoprost and comparing IOP reduction in terms of efficacy, 0.4% ripasudil and 0.02% netarsudil are almost similar, but ripasudil was well tolerated and showed minimal ocular adverse effects; hence, ripasudil is better in comparison to netarsudil.

**Key words:** Glaucoma; Hyperemia; Intraocular pressure

## INTRODUCTION

A chronic optic nerve illness known as glaucoma, which frequently results in raised intraocular pressure (IOP), can result in an irreversible loss of vision. It is the second-leading cause of blindness worldwide.<sup>1</sup> Around 13% of cases of glaucoma are estimated to be bilaterally blind; out of those half are unaware of their disease. About 90% of glaucoma remains undetected in developing countries resulting in unilateral or bilateral blindness in nearly one-fifth of the patients.<sup>2</sup>

Elevated IOP is clinically most important and the only modifiable risk factor for glaucoma. Hence reducing the IOP is the ultimate aim of management. The major classes of drugs available for the management of glaucoma are beta blockers, alpha agonists, prostaglandin analogs (PGA), sympathomimetic drugs, and carbonic anhydrase inhibitors.

Ripasudil hydrochloride hydrate eye drop was approved in September 2014 which decreases IOP by increasing conventional aqueous humor outflow through the trabecular meshwork and Schlemm's canal.<sup>3</sup> The 0.4%

### Access this article online

#### Website:

<http://nepjol.info/index.php/AJMS>

DOI: 10.3126/ajms.v15i5.62756

E-ISSN: 2091-0576

P-ISSN: 2467-9100

Copyright (c) 2024 Asian Journal of Medical Sciences



This work is licensed under a Creative Commons Attribution-NonCommercial 4.0 International License.

### Address for Correspondence:

Dr. Dinesh Kumar Yadav, Junior Resident, Department of Ophthalmology, Sarojini Naidu Medical College, Agra, Uttar Pradesh, India.

Mobile: +91-8299322235. E-mail: dkdps88@gmail.com

ophthalmic solution of ripasudil lowered IOP on an average by 2–4.4 mmHg, 2 h after installation in patients with glaucoma or ocular hypertension (OHT) in comparison with placebo continued significant reduction in pressure for at least 7 h.

Netarsudil (rhopressa) is a potent rho kinase (ROCK) inhibitor which promotes the formation of actin stress fibers and focal adhesions in the trabecular meshwork. Netarsudil lowers IOP directly through the relaxation of the trabecular meshwork, leading to an increase in aqueous outflow through the trabecular meshwork pathway.<sup>4</sup>

Timolol maleate is a  $\beta_1$  and  $\beta_2$  (Non-selective) adrenoceptor antagonist which decreases IOP by 20–33%, on average in normotensive as well as in patients with chronic open-angle glaucoma.<sup>5</sup> Trials show its effectiveness in lowering IOP, compared to that of epinephrine and pilocarpine.

## Aims and Objectives

### Aim

- The aim of the study was to compare 0.4% ripasudil, 0.02% netarsudil, and 0.5% timolol in combination with 0.005% latanoprost in the medical management of primary open-angle glaucoma (POAG) or OHT.

### Objectives

The objectives of the study are as follows:

- To determine the clinical efficacy of 0.4% ripasudil, 0.02% netarsudil, 0.5% timolol, and 0.005% latanoprost ophthalmic solutions in lowering IOP in POAG or OHT.
- To determine the safety of 0.4% ripasudil and 0.02% netarsudil ophthalmic solutions in lowering IOP in POAG or OHT.
- To compare the therapeutic effects of 0.4% ripasudil+0.005% latanoprost, 0.02% netarsudil+0.005% latanoprost, and 0.5% timolol+0.005% latanoprost.

## MATERIALS AND METHODS

### Source of data

The prospective randomized clinical study was conducted after the approval from the Ethical Committee. Informed consent was obtained before enrollment from all the participants. The duration of the study was over 18 months from December 2020 to June 2022 at the Department of Ophthalmology, Sarojini Naidu Medical College, Agra.

The study was conducted on 44 patients (18 patients used drugs in both eyes and 26 patients used drugs in

one eye, either right or left) having 62 eyes (in which 35 were right eye and 27 were left eye) which were randomly divided into three groups according to the drugs with a combination of 0.4% ripasudil, 0.02% netarsudil, and 0.5% timolol with 0.005% latanoprost. Six patients lost to follow-up (two patients using drugs in both eyes and four patients using drugs in one eye, either right or left), so they were excluded from the study so final allocation of patients was in Group A (latanoprost and timolol) 20 eyes, Group B (latanoprost and ripasudil) 18 eyes, and in Group C (latanoprost and netarsudil) 18 eyes.

No significant difference was seen in the reduction of IOP. IOP reduction does not depend on gender.

### Inclusion criteria

Patients with mild-to-moderate POAG or OHT on single PGA (e.g., latanoprost) did not achieve the target IOP.

### Exclusion criteria

Patients with narrow-angle glaucoma, pseudoexfoliation, pigment dispersion glaucoma, undergone any ocular surgery, ocular trauma, advanced glaucoma, and hypersensitivity.

### Methodology

A detailed history was taken for each patient regarding name, age, sex, occupation, present, past, and family history. Personal history and medical history regarding the sensitivity of the study drugs were also recorded.

All patients underwent a thorough, comprehensive ocular examination that included visual acuity, best corrected visual acuity, slit-lamp examination, fundus examination, automated perimetry using a Humphrey field analyzer, and Goldmann applanation tonometry to measure IOP. In high IOP (>21 mmHg), POAG was characterized as a visual field defect and glaucomatous changes to the optic nerve head (neuroretinal rim loss, optic disc asymmetry, and peripapillary atrophy).

After following the patients for 7 days, 15 days, and then monthly for 3 months, a thorough eye examination was performed. On the follow-up visit, these symptoms were noted: Conjunctival hyperemia, grittiness, blurring of vision, symptoms of dry eye, change in eyelashes, pigmentation of the iris, superficial keratitis, headache, and herpetic reactivation.

### Statistical analysis

Data collection was done and entered into an Excel spreadsheet. The statistical evaluation was done with SPSS version 25. The comparison of categorical and continuous

data among the three study groups was done using the analysis of variance test. A  $P < 0.05$  is determined to be statistically significant in the study.

## RESULTS

The study was conducted on 44 patients with 62 eyes, which were randomly divided into three groups according to the drugs: 0.4% ripasudil, 0.02% netarsudil, and 0.5% timolol with 0.005% latanoprost. Four patients (6 eyes) were lost to follow-up, so they were excluded from the study, so the final allocation of patients was in Group A (latanoprost and timolol) (20 eyes), Group B (latanoprost and ripasudil) (18 eyes), and Group C (latanoprost and netarsudil) (18 eyes).

The maximum number of patients was 41–60 years of age, with 12 patients from Group A, eight patients from Group B, and eight patients from Group C. The average age of patients in Groups A, B, and C was  $50.95 \pm 12.31$  years,  $47.22 \pm 11.38$  years, and  $50.33 \pm 13.96$  years, respectively (Table 1). There were 36 (64.28%) males and 20 (35.72%) females (Table 2).

The baseline ocular surface disease index (OSDI) were  $10.55 \pm 3.068$ ,  $10.38 \pm 2.615$ , and  $11.61 \pm 3.256$  in Groups A, B, and C, respectively. A mean OSDI score after 3 months

of treatment slightly increased from the baseline OSDI score of  $14.1 \pm 3.275$ ,  $12.88 \pm 3.939$ , and  $14.72 \pm 3.304$  were noted in all three groups after 3 months of treatment (Table 3).

## DISCUSSION

In this study, we enrolled 62 eyes of 44 patients with POAG or OHT who were using topical latanoprost 0.05% eye drops and were not able to achieve the target IOP.

In this study, the male–female ratio is 1.8:1, showing male dominance. The results indicate that glaucoma is more prevalent among the elderly population as compared to the younger population.

In this study, the effect of drugs on IOP reduction is not based on gender or the right or left eyes of patients.

Mild-to-moderate adverse events in the form of conjunctival hyperemia were seen in almost all the groups (5, 6, and 7 cases, respectively). Other adverse events in the form of blurred vision, increased lacrimation, and instillation site pain were observed in almost 50% of cases in all the groups, which subsided after some time. No patient experienced any ocular side effects resulting in the withdrawal of drugs and/or requiring management

**Table 1: Age distribution of cases among study groups**

Age group (in years)	Group A (latanoprost and timolol)	Group B (latanoprost and ripasudil)	Group C (latanoprost and netarsudil)
<40	4	7	4
41–50	6	3	4
51–60	6	5	7
>60	4	3	3
Total	20	18	18
Mean±SD	$50.95 \pm 12.31$	$47.22 \pm 11.38$	$50.33 \pm 13.96$

SD: Standard deviation

**Table 2: Gender-wise distribution of cases among study groups**

Gender	Group A (latanoprost and timolol)	Group B (latanoprost and ripasudil)	Group C (latanoprost and netarsudil)	Total (%)
Male	13	10	13	36 (64.28)
Female	7	8	5	20 (35.72)
Total	20	18	18	56

**Table 3: Comparison of OSDI score of cases among study groups**

Age group (in years)	Group A (latanoprost and timolol)	Group B (latanoprost and ripasudil)	Group C (latanoprost and netarsudil)
Baseline (Mean±SD)	$10.55 \pm 3.068$	$10.38 \pm 2.615$	$11.61 \pm 3.256$
At 1 month (Mean±SD)	$13.55 \pm 4.223$	$12.55 \pm 2.661$	$13.11 \pm 4.199$
At 3 months (Mean±SD)	$14.1 \pm 3.275$	$12.88 \pm 3.939$	$14.72 \pm 3.304$

SD: Standard deviation, OSDI: Ocular surface disease index

of adverse events. The most common ocular adverse effects seen in patients receiving netarsudil/latanoprost in a fixed-dose combination were cornea verticillata (13.1%), conjunctival hyperemia (54.5%), and conjunctival hemorrhage (8.6%).<sup>6</sup> The most commonly seen ocular adverse effects of ripasudil were conjunctival hyperemia, allergic conjunctivitis, and blepharitis.<sup>7</sup>

The difference in IOP found in all three groups after 7 days and after 15 days of treatment was clinically significant but not statistically significant. However, after 1 month of treatment, a significant difference was found in all three groups in IOP reduction. The mean IOP (mmHg) reduction from baseline at 3 months in Groups A, B, and C is 5.7±0.923, 7.11±0.832, and 6.83±0.707 mmHg, respectively. Group B was superior in IOP-lowering efficacy, followed by Group C and Group A (Table 4, Figure 1).

Sato et al.,<sup>8</sup> found that the mean IOP lowered from 18.9 mmHg at baseline to 15.8 mmHg at 6 months in an evaluation of 92 patients who took ripasudil. According to Kawara et al.,<sup>9</sup> the median IOP was reduced from 19.0 (17.0–22.5) mmHg at baseline to 16.0 (15.0–20.0) mmHg at 6 months in a study of 116 ripasudil-treated patients.

Tang et al.,<sup>10</sup> found that IOP was significantly lower after administration of netarsudil 0.2% once daily on 275 eyes

of 197 patients (mean IOP reduction of 2.3 mmHg from a baseline of 18.0 mmHg).

Naik et al.,<sup>11</sup> stated that after initiating ripasudil, the mean IOP decreased on average by 17.4% and 31.6% from baseline, respectively, and that all 30 patients reached the predetermined target IOP. Similar results were noted in this study, in which a reduction in mean IOP from baseline of 10.54%, 15.80%, and 33.72% in 1 week, 2 weeks, and 3 months, respectively, of starting ripasudil in combination with latanoprost (Group B) and target IOP was achieved in all 18 patients. Thus, ripasudil was effective as an adjunctive therapy, and each patient reached the established target IOP levels.

In this study, the mean reduction of IOP in percentage at 1 week, 2 weeks, 4 weeks, 8 weeks, and 12 weeks was 10.41%, 14.91%, 19.55%, 23.79%, 26.89% for Group A, 10.54%, 15.80%, 23.20%, 27.93%, 33.72% for Group B, and 9.94%, 15.38%, 24.06%, 27.4%, and 32.27%, respectively, for Group C (Table 5, Figure 2). In a study by Polagani et al.,<sup>12</sup> the mean IOP reduction at 2, 6, 12, and 24 weeks was 6.60 (23.21%), 9.6 (33.76%), 10.00 (38.68%), and 11.20 mmHg (39.39%) for bimatoprost and 4.20 (15.07%), 6.24% (23.39%), 7.36 (25.91%), and 7.64 mmHg (26.56%) for the timolol group, respectively, but in this study, the duration of treatment is 6 months.

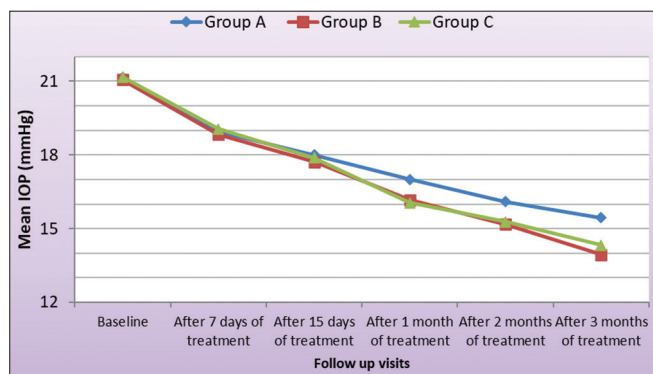
**Table 4: Mean IOP in study groups at different visits**

Visit	Group A (latanoprost and timolol)	Group B (latanoprost and ripasudil)	Group C (latanoprost and netarsudil)	Analysis of variance
Mean IOP mmHg (Baseline)	21.15±0.745	21.06±0.725	21.17±0.857	F=0.10814; P=0.897704 (NS)
Mean IOP (mmHg) (After 7 days of treatment)	18.95±0.999	18.83±0.857	19.06±0.873	F=0.26554; P=0.767809 (NS)
Mean IOP (mmHg) (After 15 days of treatment)	18.0±1.076	17.72±0.575	17.89±0.583	F=0.58424; P=0.561082 (NS)
Mean IOP (mmHg) (After 1 month of treatment)	17±0.076	16.17±0.985	16.06±0.938	F=6.26434; P=0.003613 (S)
Mean IOP (mmHg) (After 2 months of treatment)	16.1±0.788	15.17±0.618	15.28±0.826	F=8.87505; P=0.000474 (S)
Mean IOP (mmHg)(After 3 months of treatment)	15.45±0.759	13.94±0.639	14.33±0.840	F=20.79856; P<0.0001 (S)
Mean of IOP (mmHg) (decrease from baseline to 3 months of treatment)	5.7±0.923	7.11±0.832	6.83±0.707	F=15.62227; P<0.0001(S)

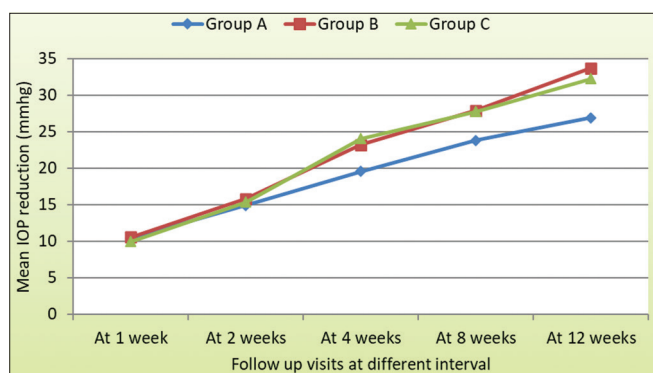
IOP: Intraocular pressure

**Table 5: Mean percentage reduction of IOP at various visits**

Visits (in weeks)	Group A (latanoprost and timolol)	Group B (latanoprost and ripasudil)	Group C (latanoprost and netarsudil)	Analysis of variance
At 1 week	10.41±3.325	10.54±2.96	9.94±3.158	F=0.18114; P=0.834837 (NS)
At 2 weeks	14.91±3.621	15.80±1.98	15.38±3.79	F=0.35316; P=0.704103 (NS)
At 4 weeks	19.55±4.095	23.20±4.066	24.06±4.831	F=5.58232; P=0.005053 (S)
At 8 weeks	23.79±4.51	27.93±2.73	27.74±4.337	F=6.69575; P=0.002555 (S)
At 12 weeks	26.89±3.90	33.72±3.269	32.27±3.03	F=21.04974; P<0.0001 (S)



**Figure 1:** Mean IOP in study groups at different visits



**Figure 2:** Mean percentage reduction of IOP at various visits

### Limitations of the study

The study had a small sample size, a short study duration, and difficult logistics.

### CONCLUSION

- In contrast with many studies done so far on conservative management of POAG or OHT, this study emphasizes comparison between the different drug combinations. This can help us better understand the efficacy, side effects, and outcomes when these drugs are used in combination.
- When given in combination with 0.005% latanoprost, the efficacy in terms of IOP reduction of 0.4% ripasudil and 0.02% netarsudil was almost similar but better than 0.5% timolol. Ripasudil was better tolerated, and netarsudil had maximum ocular side effects. The most common ocular adverse effect was conjunctival hyperemia.
- In our study, patients were selected on an OPD basis, fulfilling the inclusion and exclusion criteria. These patients were easy to follow up with, so our study was carried out in the required manner.
- The purpose of this study is to determine whether the drugs (ripasudil and netarsudil) used in our study have

fewer side effects as compared to the drugs that were previously used.

- The conservative approach for the treatment of POAG and OHT is an advantage over surgical procedures or using multiple drugs.
- We can avoid surgical intervention using this combination of drugs.
- This study differs from previous studies on the basis of the comparison of groups of drugs; we compared three groups of drugs in our study, while two groups compared previous studies.
- Previous studies were not conducted to compare these combinations of drugs.

### ACKNOWLEDGMENT

The authors would like to thank the Department of Ophthalmology, Sarojini Naidu Medical College, Agra, Uttar Pradesh, India.

### REFERENCES

1. Kingman S. Glaucoma is second leading cause of blindness globally. *Bull World Health Organ.* 2004;82(11):887-888.
2. George R, Ve RS and Vijaya L. Glaucoma in India: Estimated burden of disease. *J Glaucoma.* 2010;19(6):391-397. <https://doi.org/10.1097/ijg.0b013e3181c4ac5b>
3. Honjo M and Tanihara H. Impact of the clinical use of ROCK inhibitor on the pathogenesis and treatment of glaucoma. *Jpn J Ophthalmol.* 2018;62(2):109-126. <https://doi.org/10.1007/s10384-018-0566-9>
4. Kazemi A, McLaren JW, Kopczynski CC, Heah TG, Novack GD and Sit AJ. The effects of netarsudil ophthalmic solution on aqueous humor dynamics in a randomized study in humans. *J Ocul Pharmacol Ther.* 2018;34(5):380-386. <https://doi.org/10.1089/jop.2017.0138>
5. Allingham RR, Damji KF and Freedman SF. *Shields Textbook of Glaucoma.* 5<sup>th</sup> ed. Philadelphia, PA: Lippincott Williams and Wilkins; 2004. p. 457-471. Available from: <https://books.google.co.in/books?id=J3AmrUxtT04C> [Last accessed on 2023 Dec 08].
6. Jethva J, Bhagat P, Prajapati K and Tank G. Safety, efficacy, and patient selection of ripasudil in patients with uncontrolled glaucoma with maximum conventional medical therapy. *Indian J Ophthalmol.* 2022;70(6):2020-2023. [https://doi.org/10.4103/ijo.ijo\\_3145\\_21](https://doi.org/10.4103/ijo.ijo_3145_21)
7. Tanihara H, Inoue T, Yamamoto T, Kuwayama Y, Abe H, Araie M, et al. Phase 2 randomized clinical study of a Rho kinase inhibitor, K-115, in primary open-angle glaucoma and ocular hypertension. *Am J Ophthalmol.* 2013;156(4):731-736. <https://doi.org/10.1016/j.ajo.2013.05.016>
8. Sato S, Hirooka K, Nitta E, Ukegawa K and Tsujikawa A. Additive intraocular pressure lowering effects of the rho kinase inhibitor, ripasudil in glaucoma patients not able to obtain adequate control after other maximal tolerated medical therapy. *Adv Ther.* 2016;33(9):1628-1634. <https://doi.org/10.1007/s12325-016-0389-3>

9. Kawara K, Kanamori A, Mori S, Inoue Y, Kurimoto T, Kusahara S, et al. Intraocular pressure-lowering effect of ripasudil hydrochloride hydrate and reasons for discontinuation of use in clinical practice. *Int J Ophthalmol Clin Res.* 2018;5:83. <https://doi.org/10.23937/2378-346X/1410083>
10. Tang M, Prager A, Pleet A and Tanna AP. Retrospective analysis of the efficacy and safety of netarsudil in clinical practice. *Invest Ophthalmol Vis Sci.* 2020;61(7):1241.
11. Naik M, Kapur M, Gupta V, Sethi H and Srivastava K. Ripasudil Endgame: Role of rho-kinase inhibitor as a last-ditch-stand towards maximally tolerated medical therapy to a patient of advanced glaucoma. *Clin Ophthalmol.* 2021;15:2683-2692. <https://doi.org/10.2147/OPTH.S318897>
12. Polagani P, Maddikunta SV, Balakrishna N, Kondaveti S. A comparative study on the safety and efficacy of topical bimatoprost with timolol maleate in glaucoma patients. *J Evol Med Dent Sci.* 2016;5(46):2874. Available from: <https://go.gale.com/ps/i.do?id=GALE%7CA469755748&sid=googleScholar&v=2.1&it=r&linkaccess=abs&issn=22784748&p=AONE&sw=w&userGroupName=anon%7E8f3b61eb&aty=open-web-entry>

**Authors Contribution:**

**TN, SS, HKY, DKY-** Concept and design of the study, prepared the first draft of the manuscript; interpreted the results; reviewed the literature and manuscript preparation; concept, coordination, preparation of manuscript, and revision of the manuscript.

**Work attributed to:**

Sarojini Naidu Medical College, Agra - 282 003, Uttar Pradesh, India.

**Orcid ID:**

Dr. Tirupati Nath - <https://orcid.org/0000-0003-3465-2667>

Dr. Snigdha Sen - <https://orcid.org/0000-0003-1437-5869>

Dr. Himanshu Kumar Yadav - <https://orcid.org/0009-0007-8554-3854>

Dr. Dinesh Kumar Yadav - <https://orcid.org/0009-0000-6868-8313>

**Source of Support:** Nil, **Conflicts of Interest:** None declared.