

Jejunogastric intussusception: A case report of unusual cause of upper gastrointestinal bleeding after gastrojejunostomy



Swaminathan Rajan¹, Sivasankar Amarapathy², Somasekar Durairajan³

¹Senior Resident, ²Professor and Head, ³Senior Assistant Professor, Department of Surgical Gastroenterology and Gastrointestinal Oncology, Government Mohan Kumaramangalam Medical College Hospital, Salem, Tamil Nadu, India

Submission: 13-02-2024

Revision: 03-05-2024

Publication: 01-06-2024

ABSTRACT

Upper gastrointestinal bleeding is following gastrojejunostomy due to stromal ulceration, marginal ulcer bleeding from anastomotic site, remnant cancer. Gastrojejunostomy done for benign gastric outlet obstruction has many complications. Jejunogastric intussusceptions (JGI) is a rare complication of gastrojejunostomy surgery (<0.1% of cases), yet requires an urgent diagnosis. Mortality rates range from 10% to 50% based on delay in diagnosis and surgical intervention. Vomiting, abdominal pain, and hematemesis are the most common symptoms. We report a 53-year-old man admitted to the emergency department, complaining of epigastric pain and recurrent hematemesis for 3 days. Abdominopelvic computed tomography scan also showed a target sign in favor of jejunal intussusception. Midline emergency laparotomy was done and the gangrenous jejunum was resected with reconstruction Roux en Y loop was done. The patient was discharged without any further complications. In patients presented with hematemesis and abdominal pain and a history of gastrojejunostomy, JGI must consider a possible cause because early diagnosis and treatment are necessary to prevent further complications.

Key words: Intussusceptions, UGI bleed, gastric, Gastrojejunostomy, Post operative

Access this article online

Website:

<http://nepjol.info/index.php/AJMS>

DOI: 10.3126/ajms.v15i6.62731

E-ISSN: 2091-0576

P-ISSN: 2467-9100

Copyright (c) 2024 Asian Journal of Medical Sciences



This work is licensed under a Creative Commons Attribution-NonCommercial 4.0 International License.

INTRODUCTION

Jejunogastric intussusception (JGI) is a rare complication of gastrojejunostomy (incidence of 0.15%) and has fatal outcomes if not treated. It is rare but associated with high mortality rates, up to 50% if the diagnosis and treatment are delayed. It can be presented with various clinical presentations including acute and chronic obstruction symptoms,¹ hematemesis, intermittent epigastric pain, and palpable epigastric mass.² The diagnosis can be made based on the clinical presentations, endoscopic findings, and imaging. The definitive treatment of JGI is surgical intervention but endoscopic and laparoscopic intervention also can be used. We report a male patient with a history of gastrojejunostomy 4 years ago admitted with hematemesis,

vomiting, and epigastric pain. Emergency laparotomy with resection of a gangrenous segment with Roux en Y reconstruction resulted in successful management of the patient.

CASE PRESENTATION

A 50-year-old male presented to the emergency department complaining of epigastric pain, recurrent hematemesis, and coffee-ground vomiting for 3 days. He did not have any history of melena and weight loss. Four years earlier, he had undergone gastrojejunostomy with truncal vagotomy due to benign gastric outlet obstruction due to acid peptic sequelae. In physical examination, he was pale and ill. The blood pressure was 80/60 mm Hg, the pulse rate

Address for Correspondence:

Dr. Sivasankar Amarapathy, Senior Consultant and Head, Department of Surgical Gastroenterology and Gastrointestinal Oncology, Government Mohan Kumaramangalam Medical College Hospital, Salem, Tamil Nadu, India. **Mobile:** +91-9790018137. **E-mail:** drsivasankar2004@yahoo.com

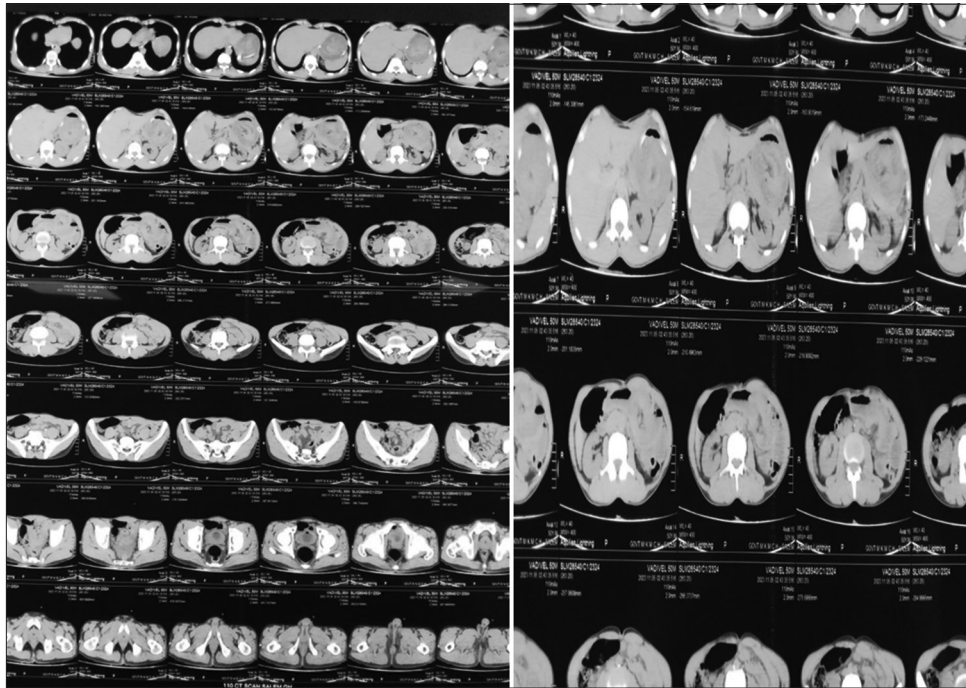


Figure 1: CT abdomen showing intussusception

at 116 bpm, the respiratory rate of 27/min and he had a temperature of 37°C. In the abdominal examination, a midline abdominal scar from a previous laparotomy was noted. He had moderate-to-severe tenderness of the epigastric region with guarding and mild generalized tenderness without rebound tenderness with the masslike lesion. Bowel sounds and rectal examination were normal. According to our findings, we suspected a possibility of stomal perforation or stomal ulceration with bleed. He underwent an upright and supine abdominal X-ray has been taken. We requested an abdominopelvic computed tomography (CT) scan (Figures 1 and 2) which also showed a target sign in favor of intussusception of the jejunum. After initial resuscitation, emergency laparotomy was undertaken and in exploration, a distal jejunum loop about 40 cm long, invaginated to the gastric cavity with signs of gangrene was found. The jejunal loop was resected and Roux en Y reconstruction was done. The abdominal cavity was explored entirely, and there were no free abdominal fluid or any pathologic findings. Post-operative follow-up was uneventful. The patient was discharged 6 days later.

DISCUSSION

JGI is a rare condition in which one or two segments of jejunum invaginate into the stomach from the stoma site of gastrojejunostomy. According to Shackman's classification, it has three types based on the invaginated segment of the jejunum: Afferent loop, efferent loop, or both. The efferent loop invagination is most prevalent.³ In most

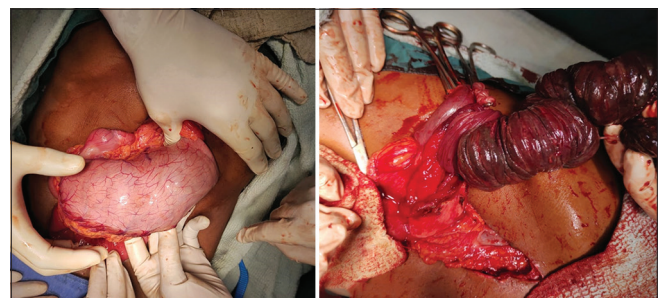


Figure 2: (a) External appearance of stomach, (b) after gastrotomy gangrenous jejunum delivered out

reports, it occurred at the gastrojejunal anastomosis site, Braun anastomosis site of Billroth II reconstruction, and Y anastomosis site of the Roux-en-Y reconstruction. JGI occurrence after gastric surgery varies from a few days to 25-year postoperatively.⁴

The JGI can be categorized based on the acute or chronic phase of onset. In the acute phase, it presents with colicky pain that can be associated with vomiting, however, in some cases, other symptoms such as epigastric mass and hematemesis are also seen. In the chronic type, it can be presented with obstruction symptoms, namely, chronic intermittent epigastric pain for years.⁵ In some articles, epigastric mass with hematemesis and colicky epigastric pain was defined as the pathognomonic triad for JGI. Therefore, it is crucial to differentiate JGI from bleeding ulcers, tumoral lesions, and mechanical obstruction due to anastomotic stenosis, bezoar impaction, afferent loop syndrome, and other causes. Based on the time of diagnosis

and without immediate intervention, the mortality rate could be 10–50%.⁶

The predisposing factors for JGI are excessive lifting of the jejunal stump, excessive peristalsis, the diameter of anastomosis orifice, length of the jejunal stump, hyper acidic state, length of the afferent loop, jejunal spasm associated with abnormal bowel motility, intra-abdominal hypertension, and retrograde peristalsis.⁷ There are also contradictory data about the initial choice of diagnostic measures; some articles advise endoscopy and others recommend abdominal CT scan or ultrasonography. Although in most of cases, both of them were performed. Endoscopy is the first step to evaluate upper gastrointestinal (GI) bleeding, but there are cases in which intussusception was confounded by a clot, tumor, or bezoar, exemplified in our case. The typical CT finding of intussusception is a soft-tissue mass with a “sausage” or “target” appearance.⁸ Treatment is nearly always surgical.

In some cases, the reduction of the involved segment and in others resection of concerning sites for recurrence were the choice of management. However, due to a lack of follow-ups, the recurrence rate of JGI remains unknown. Both laparoscopic and laparotomy reduction approaches have been performed successfully. There are also reports of endoscopic reduction for JGI.⁹ This is obvious that a definitive treatment of JGI is the surgical intervention, which includes reduction with correction, resection of the involved bowel, and revision of the anastomosis.¹⁰

CONCLUSION

This case and other cases with similar clinical presentation with a history of gastric surgery, especially after Billroth II, highlight that hematemesis associated with abdominal pain (showing ischemic mucosa) needs an emergent surgical consultation. The surgical intervention must not be delayed for endoscopic or other investigations, although they may be helpful for diagnosis or treatment planning.

REFERENCES

1. Alhaj Saleh A, Slate R, Habrawi Z and Aryaie AH. Jejuno-gastric intussusception: A case report of unusual cause of food intolerance after roux-En-Y gastric bypass. *Int J Surg Case Rep.* 2018;45:126-129. <https://doi.org/10.1016/j.ijscr.2018.03.029>
2. Loi CM, Huang SY, Chen YD, Chen SD, Wu JM and Chen KH. Retrograde jejuno-gastric intussusception: A case report and review of the literature. *Asian J Surg.* 2014;40(4):309-312. <https://doi.org/10.1016/j.asjsur.2014.04.001>
3. Ravirajendran S, Munnamgi S and Abdul A. Antegrade jejunojejunal intussusception inside a retrograde jejuno-gastric intussusception (double intussusception)-a rare case report. *Int J Surg Case Rep.* 2017;39:264-266. <https://doi.org/10.1016/j.ijscr.2017.08.036>
4. Kawano F, Tashiro K, Nakao H, Fujii Y, Ikeda T, Takeno S, et al. Jejuno-gastric intussusception after distal gastrectomy with roux-en-Y reconstruction: A case report. *Int J Surg Case Rep.* 2018;44:105-109. <https://doi.org/10.1016/j.ijscr.2017.12.042>
5. Tokue H, Tsushima Y, Arai Y and Endo K. Jejuno-gastric intussusception: Life-threatening complication occurring 55 years after gastrojejunostomy. *Intern Med.* 2009;48(18):1657-1660. <https://doi.org/10.2169/internalmedicine.48.2115>
6. Ho CY, Chang CW, Lee F, Tsai CH, Lin WC, Chen MJ, et al. Jejuno-gastric intussusception presented with hematemesis: A case presentation and review of the literature. *Adv Dig Med.* 2017;4:35-358.
7. Kitasato Y, Midorikawa R, Uchino Y, Saku S, Minami T, Shirahama T, et al. A case of retrograde intussusception at Roux-en-Y anastomosis 10 years after total gastrectomy: Review of the literature. *Surg Case Rep.* 2016;2:123. <https://doi.org/10.1186/s40792-016-0250-6>
8. Hammond N, Miller FH and Dynes M. Intussusception into the enteroanastomosis after Billroth II gastrectomy and roux-en-Y jejunostomy: Sonographic and CT findings. *AJR Am J Roentgenol.* 2001;177(3):624-626. <https://doi.org/10.2214/ajr.177.3.1770624>
9. Toth E, Arvidsson S and Thorlacius H. Endoscopic reduction of a jejuno-gastric intussusception. *Endoscopy.* 2011;43 Suppl 1:E63. <https://doi.org/10.1055/s-0030-1256103>
10. Lee SH, Kwon IG, Ryu SW and Sohn SS. Jejuno-gastric intussusception: A rare complication of gastric cancer surgery. *Int J Clin Exp Med.* 2014;7(11):4498-4502.

Authors' Contributions:

SR- Preparation of manuscript; **SA-** Concept of subject, manuscript correction, and surgical implementation; and **SD-** Manuscript correction and manuscript edition.

Work attributed to:

Department of Surgical Gastroenterology and Gastrointestinal Oncology, Government Mohan Kumaramangalam Medical College Hospital, Salem, Tamil Nadu, India.

Orcid ID:

Swaminathan Rajan - <https://orcid.org/0009-0009-2117-5719>
Sivasankar Amarapathy - <https://orcid.org/0009-0009-3871-3245>
Somasekar Durairajan - <https://orcid.org/0009-0009-8366-4075>

Source of Support: Nil, **Conflicts of Interest:** None declared.