

An overview of the clinical profile of infertile patients who underwent hysterosalpingography



Imran Nazir Salroo¹, Zahoor Ahmad Raina², Mohd Farooq Mir³, Muzamil Rasool⁴

¹Assistant Professor, ²Senior Resident, ³Associate Professor, Department of Radiodiagnosis and Imaging, ⁴Senior Resident, Department of Obstetrics and Gynaecology, SKIMS Medical College, Srinagar, Jammu and Kashmir, India

Submission: 23-01-2024

Revision: 27-02-2024

Publication: 01-04-2024

ABSTRACT

Background: Infertility is a prevalent medical issue that can arise from challenges in male or female or both partners. Pivotal contributing factors to female infertility include dysfunction, tubal issues, and peritoneal factors. Hysterosalpingography (HSG) holds significant importance in assessing abnormalities associated with the uterus and fallopian tubes. **Aims and Objectives:** This study aimed to assess the clinical profile and hysterosalpingographic findings of women with infertility who visited the department of radiodiagnosis for HSG. **Materials and Methods:** This is a cross-sectional study, where consecutive convenience-based sampling was used, with ethical clearance in place. Sixty-three infertile women of reproductive age were recruited for the study and were referred for HSG by the Department of Obstetrics and Gynecology. **Results:** The majority of the participants had primary infertility (71.88%) and was in the 31–35-year age group with the majority having 3–6 years of infertility and endometriosis. On HSG uterine pathology was found in 9.37% of participants and unilateral and bilateral tubal blocks were seen in 18.75% and 14.06% of cases approximately. **Conclusion:** HSG is a minimally invasive procedure, secure, and plays a crucial role in diagnosing uterine and tubal factors contributing to infertility.

Key words: Infertility; Hysterosalpingography; Clinical profile

Access this article online

Website:

<http://nepjol.info/index.php/AJMS>

DOI: 10.3126/ajms.v15i4.62106

E-ISSN: 2091-0576

P-ISSN: 2467-9100

Copyright (c) 2024 Asian Journal of Medical Sciences



This work is licensed under a Creative Commons Attribution-NonCommercial 4.0 International License.

INTRODUCTION

Infertility is a disease of the male or female reproductive system defined by the failure to achieve pregnancy within 12 months or more of regular unprotected sexual intercourse.¹ Infertility may be primary or secondary. Primary infertility has never conceived and secondary infertility indicates previous pregnancy irrespective of the outcome (abortion or live birth) but failure to conceive subsequently.² Infertility is a global problem with frequency ranging from 5% to 15% in different communities. The United States sees a prevalence of 7.4–15.5% depending on the methodological approach used.³ India has a frequency of infertility of more than 10% approximately 20 million population as infertile as per data reproduced by (INITO - A Bangalore-based medical technology

corporation). The causes of infertility with relative prevalence are as follows: Male factor (17–28%), both male and female factors (8–39%), female factor (33–40%), and unexplained (8–28%). The common male factors are defects of spermatogenesis (50%) and efferent duct obstruction (30%), epididymal obstruction (congenital or infective), ductal dysfunction or retrograde ejaculation, sperm motility disorder, sexual dysfunction, Erectile dysfunction, ejaculatory failure, drug-related, genitourinary surgery,³ and unexplained.⁴ Female factors are responsible for approximately 40% of cases of infertility.⁵ The common causes of female factor infertility are ovarian causes, tubal disease, peritoneal causes, uterine, cervical factors, and hormonal causes.⁶ In the present era, a laparoscopy is an important tool in the infertility workup, which serves as both a diagnostic and therapeutic modality. It is reserved

Address for Correspondence:

Dr. Muzamil Rasool, Senior Resident, Department of Obstetrics and Gynaecology, SKIMS Medical College, Srinagar, Jammu and Kashmir, India. **Mobile:** +91-8491892661. **E-mail:** muzamilrasool336@gmail.com

for selected cases to recognize endometriosis, pelvic adhesions, hydrosalpinx, and other peritoneal factors. As part of the infertility evaluation, adhering to guidelines the hysterosalpingography (HSG) becomes inevitable. Dyes are more appropriate in women with a history of pelvic inflammatory disease, previous ectopic pregnancy, or endometriosis. This allows assessment of both tubal and other pelvic pathology.⁷ Limited research on this subject has been done in our tertiary care hospital so far. Hence, it becomes imperative to conduct such a study in our hospital which caters to the most population of the rural strata.

Aims and Objectives

The aim and objective is to study the clinical profile of patients referred for HSG as a diagnostic tool in unexplained infertility.

MATERIALS AND METHODS

The present study was done in the Department of Radiology in collaboration with the Department of Obstetrics and Gynecology SKIMS MCH, Bemina, where 63 participants were recruited in the current study. After obtaining ethical clearance, well-informed consent was taken from the participants. Privacy and confidentiality were maintained. After a detailed history, clinical examination, and laparoscopic procedure, patients were referred for hysterosalpingography as part of the infertility evaluation protocol.

A consecutive convenience-based sampling technique was used for the current study. After a thorough pre-invasive procedure, informed consent was taken from the patients. Patients were made to understand the procedure, advantages, complications, and need for HSG. After conducting a thorough history, initial assessment, and necessary investigations, they were asked to report post-menstrual in the proliferative phase for HSG as a part evaluation for infertility.

Inclusion criteria

- Patients having unexplained infertility in the reproductive age group
- Patients having a history of primary as well as secondary infertility.

Exclusion criteria

- Patients having any contraindication to HSG procedures such as previous major surgeries, peritonitis, hernia large pelvic mass, or any medical comorbidity
- Patients having contraindications to general anesthesia
- Major male infertility.

Procedure

Patients were advised to take a mild pain reliever before the procedure and were informed about any allergies,

particularly to iodine or contrast dye. The procedure was scheduled during the 1st week after the menstrual period to minimize the risk of interference with a possible pregnancy. Patients were asked to lie on an examination table, usually on their back with their feet in stirrups, similar to a pelvic examination. The cervix is visualized by inserting a speculum inside the vagina. The cervix was cleaned with an antiseptic solution to reduce the risk of infection. A thin, flexible catheter was then gently inserted through the cervix and into the uterine cavity. A radiopaque contrast dye was injected through the catheter into the uterus. The dye helps to outline the uterine cavity and fallopian tubes, making them visible on X-ray images. The radiologist evaluated the images to identify any abnormalities, such as uterine abnormalities, blockages in the fallopian tubes, or other issues that may contribute to infertility. Once the procedure was complete, the catheter was removed. The patient was monitored for a short period to ensure that there were no immediate complications. Patients were provided with instructions regarding post-procedure care, including restrictions on activities or medications. Mild cramping or discomfort during or after the procedure was explained. Vaginal spotting or light bleeding after the HSG is common. Any signs of infection (fever, severe pain, etc.) were asked to be reported to the health-care provider.⁷

Statistical analysis

All the collected data were collected replicated in Microsoft Excel and analyzed using the IBM SPSS 24.0. Frequencies and percentages were calculated.

RESULTS

Table 1 indicates that in our study, primary infertility was found in 45 (71.42%) of the 64 patients, and secondary infertility was found in 18 patients 28.12%.

Table 2 indicates that most patients in the primary infertility group were in the 31–35 years age group and understandably 34.3% from 26 to 30 years followed by 7.8% from the age group of 36–40 years.

Table 3 indicates that the majority of patients 65.07% had 3–6 years of duration of illness, followed by 25.39% who had a duration of fewer than 2 years and 9.52% had >6 years of duration.

Table 4 and Figures 1-3 indicates that the majority of patients having primary infertility had endometriosis (51.51%), pelvic adhesions 18.18%, tubal block 12.12%, myoma 9.09%, and hydrosalpinx 9.09%, whereas in secondary infertility, majority 50.00% had endometriosis, 37.5% had pelvic adhesions, and

Table 1: Type of infertility (n=63)		
Parameter	Frequency	Percentage
Primary infertility	45	71.42
Secondary infertility	18	28.57
Total	63	100

Table 2: Age distribution of patients (n=63)			
S. No	Age	Frequency	Percentage
1	21–25 years	04	6.34
2	26–30 years	22	34.92
3	31–35 years	32	50.79
4	36–40 years	05	7.93

Table 3: Duration of infertility (n=63)			
S. No.	Duration	Frequency	Percentage
1	≤2 years	16	25.39
2	3–6 years	41	65.07
3	>6 years	06	9.52

the tubal block was seen in 12.5%. The overall majority of patients had endometriosis 51.21%.

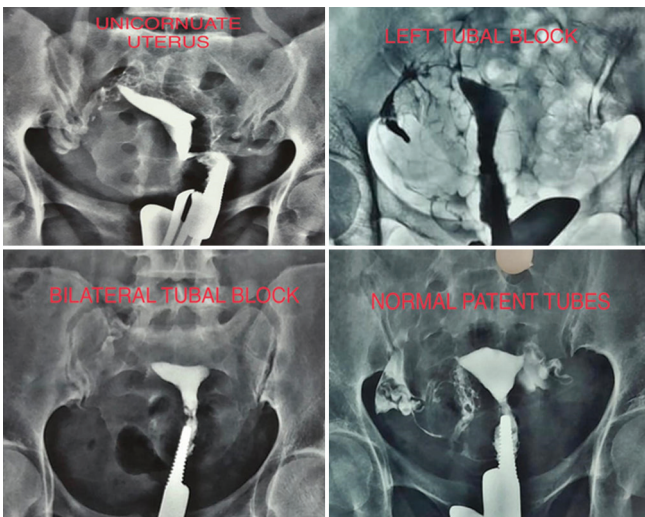


Table 5 and above HSG images indicate that a unicornuate uterus was found in 3.12%, an irregular shape of uterine cavity was found in 9.37%, unilateral tubal block was seen in 18.75%, and bilateral in 12.50%.

DISCUSSION

The study was done to ascertain the clinical profile of infertility patients undergoing HSG. The study was done from June to October 2023. Our study was a cross-sectional hospital-based study. A total of 63 infertile patients were evaluated. The majority of patients were from the age group of 26 to 35 years in our study which was done by study.⁸ Our study documented a little higher

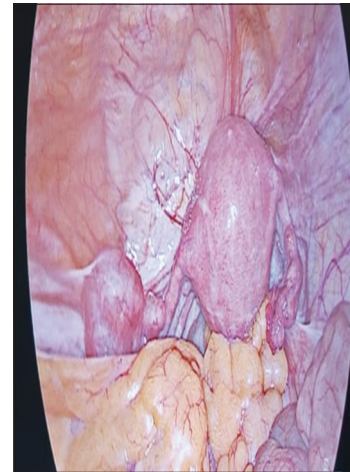

Figure 1: Hydrosalpinx

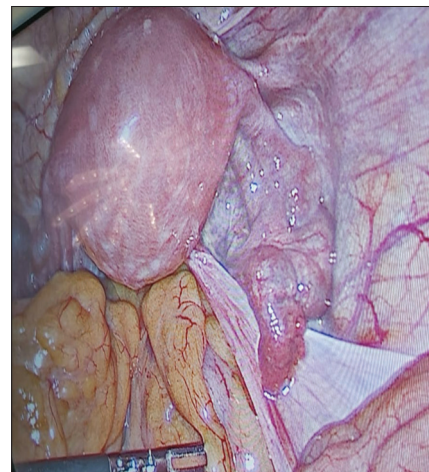


Figure 2: Adhesions

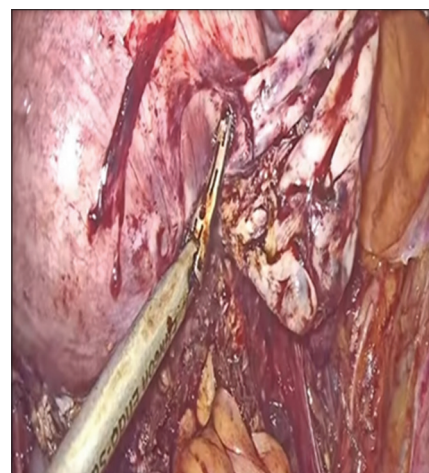

Figure 3: Endometriosis

percentage of primary infertility than the study done by Khan et al.⁹ The likely reason could be influenced by different characteristics of the study population and the definition of abnormalities. The majority of patients had a duration of infertility between 2 and 5 years which

Table 4: Statistics of laparoscopic findings (n=63)

S. No.	Laparoscopic findings	Primary infertility n/percentage	Secondary infertility n/percentage	Total
1	Pelvic adhesions	6 (18.18)	3 (37.5)	9 (21.95)
2	Endometriosis	17 (51.51)	4 (50.00)	21 (51.21)
3	Tubal block	4 (12.12)	1 (12.5)	5 (12.19)
4	Myoma uterus	3 (9.09)	00	3 (7.31)
5	Hydrosalpinx	3 (9.09)	00	3 (7.31)
	Total	33	8	41

Table 5: Findings of hysterosalpingography (n=63)

HSG finding	Frequency	Percentage
Unicornuate uterus	2	3.12
The irregular shape of the cavity	6	9.37
Unilateral tubal block	12	18.75
Bilateral tubal block	9	14.06
Both tubes normal	35	54.68

HSG: Hysterosalpingography

was in line with the international study by Haider et al., where the mean duration of infertility was >5 years.¹⁰ Our study documented that the majority of patients had endometriosis in laparoscopic findings which was in concordance with the study.^{11,12} In our study, the results showed that a significant number of participants had a unilateral and bilateral tubal block, similar findings have been explained in studies by Bello, Tvarijonaviciene, Tsuji et al.^{12,13,14} Different procedures are adopted to assess and evaluate the infertile population of reproductive age but still, HSG remains a good choice to investigate the uterine and tubal cause of infertility.

What this study adds?

- This study may provide diagnostic insight and treatment planning
- Improvement initiatives in health-care settings, encourage the refinement of diagnostic protocols and the enhancement of patient care for infertile individuals
- May foster collaboration between different medical specialties involved in infertility management, promoting a comprehensive and multidisciplinary approach to patient care.

Limitations of the study

1. The smaller sample size limits it to make it generalized
2. The sample was taken from a single tertiary care hospital
3. The study has recruited from a sample from similar ethnic or cultural populations
4. Need for a follow-up study to understand the long-term outcomes of infertile patients after HSG.

CONCLUSION

Our study provides an important overview of the clinical profile of infertile patients undergoing hysterosalpingography (HSG). Our findings reveal that a major proportion of these patients present with tubal blockages unilateral or bilateral, uterine abnormalities, and endometriosis. Our results highlight the importance of HSG in diagnosing and understanding the underlying causes of infertility. Extensive research is needed to explore the impact of HSG findings on treatment outcomes and to optimize management strategies for the infertile population.

ACKNOWLEDGMENT

We express our sincere thanks to patients, postgraduate students, faculty, and staff of the Department of Radiology and Obstetrics and Gynecology who gave their valuable time to make this study happen.

REFERENCES

1. Vander Borgh M and Wyns C. Fertility and infertility: Definition and epidemiology. *Clin Biochem.* 2018;62:2-10. <https://doi.org/10.1016/j.clinbiochem.2018.03.012>
2. Hessel M, Brandes M, De Bruin JP, Bots RS, Kremer JA, Nelen WL, et al. Long-term ongoing pregnancy rate and mode of conception after a positive and negative post-coital test. *Acta Obstet Gynecol Scand.* 2014;93(9):913-920. <https://doi.org/10.1111/aogs.12442>
3. Nandi A, Bhide P, Hooper R, Gudi A, Shah A, Khan K, et al. Intrauterine insemination with gonadotropin stimulation or *in vitro* fertilization for the treatment of unexplained subfertility. A randomised control trail. *Fertil Steril.* 2017;107(6):1329-1335. <https://doi.org/10.1016/j.fertnstert.2017.03.028>
4. De Cicco S, Tagliaferri V, Selvaggi L, Romualdi D, Di Florio C, Immediata V, et al. Expectant management may reduce overtreatment in women affected by unexplained infertility confirmed by diagnostic laparoscopy. *Arch Gynecol Obstet.* 2017;295(2):427-433. <https://doi.org/10.1007/s00404-016-4246-z>
5. Practice Committee of the American Society for Reproductive Medicine. Optimal evaluation of the infertile female. *Fertil Steril.*

- 2006;86(5 Suppl 1):S264-S267.
<https://doi.org/10.1016/j.fertnstert.2006.08.041>
6. National Institute for Health and Care Excellence (NICE). Fertility: Evidence Update March 2015: A Summary of Selected New Evidence Relevant to NICE Clinical Guideline 156 'Assessment and Treatment for People with Fertility Problems' (2013). London: National Institute for Health and Care Excellence (NICE); 2015.
 7. Onwuchekwa CR and Oriji VK. Hysterosalpingographic (HSG) pattern of infertility in women of reproductive age. *J Hum Reprod Sci.* 2017;10(3):178-184.
https://doi.org/10.4103/jhrs.JHRS_121_16
 8. Ibekwe P, Udensi M and Imo A. Hysterosalpingographic findings in patients with infertility in South Eastern Nigeria. *Niger J Med.* 2010;19(2):165-167.
<https://doi.org/10.4314/njm.v19i2.56510>
 9. Khan MI, Jesmin S, Jerin J, Shermin S and Chowdhury TA. Hysterosalpingography in Infertility. *Delta Med Coll J.* 2014;2(1):9-12.
<https://doi.org/10.3329/DMCJ.V2I1.17790>
 10. Haider G, Rani S, Talpur S, Zehra N and Munir A. Laparoscopic evaluation of female infertility. *J Ayub Med Coll Abbottabad.* 2010;22(1):136-138.
 11. Nayak PK, Mahapatra PC, Mallick J, Swain S, Mitra S and Sahoo J. Role of diagnostic hystero-laparoscopy in the evaluation of infertility: A retrospective study of 300 patients. *J Hum Reprod Sci.* 2013;6(1):32-34.
<https://doi.org/10.4103/0974-1208.112378>
 12. Bello TO. Tubal abnormalities on hysterosalpingography in primary and secondary infertility. *West Afr J Med.* 2006;25(2):130-133.
<https://doi.org/10.4314/wajm.v25i2.28263>
 13. Tvarijonavieiene E and Nadisauskiene RJ. The value of hysterosalpingography in the diagnosis of tubal pathology among infertile patients. *Medicina (Kaunas).* 2008;44(6):439-448.
 14. Tsuji I, Ami K, Miyazaki A, Hujinami N and Hoshiai H. Benefit of diagnostic laparoscopy for patients with unexplained infertility and normal hysterosalpingography findings. *Tohoku J Exp Med.* 2009;219(1):39-42.
<https://doi.org/10.1620/tjem.219.39>

Authors Contribution:

INS- Research question, protocol paper, statistical analysis; **ZAR-** Data collection, methodology; **MFM-** Peer review, literature survey; **MR-** Ethical committee presentation, manuscript writing.

Work attributed to:

All the patients visiting tertiary care hospital SKIMS MCH, Bemina, for their treatment.

Orcid ID:

Imran Nazir Salroo - <https://orcid.org/0000-0002-9934-6380>
Zahoor Ahmad Raina - <https://orcid.org/0009-0001-1005-5174>
Mohd Farooq Mir - <https://orcid.org/0009-0007-8866-1119>
Muzamil Rasool - <https://orcid.org/0009-0000-0485-540X>

Source of Support: Nil, **Conflicts of Interest:** None declared.