

Primary stromal sarcomas of the breast: Case series on a rare entity



Soumita Ghosh Sengupta¹, Bidisha Chakraborty², Kaushik Saha³, Gargi Raychaudhuri⁴

^{1,4}Associate Professor, ²Senior Resident, Department of Pathology, College of Medicine and Sagore Dutta Hospital, Kolkata, ³Associate Professor, Department of Pathology, Murshidabad Medical College and Hospital, Berhampore, West Bengal, India

Submission: 30-12-2023

Revision: 04-03-2024

Publication: 01-04-2024

ABSTRACT

Primary breast stromal sarcomas are rare entities arising from connective tissue within the breast, accounting for <5% of all soft tissue sarcomas and <1% of malignant breast tumors. Primary breast sarcomas are locally aggressive tumors and should be differentiated from malignant phyllodes tumor and metaplastic carcinoma of the breast, which are close mimickers. Here we present 4 cases of primary breast sarcoma that we found over the course of 7 years in our institution who presented with a breast lump. Mastectomy was performed, and they were diagnosed as primary stromal sarcoma of the breast.

Key words: Primary breast sarcomas; Stromal sarcoma of breast; Angiosarcoma

Access this article online

Website:

<http://nepjol.info/index.php/AJMS>

DOI: 10.3126/ajms.v15i4.61192

E-ISSN: 2091-0576

P-ISSN: 2467-9100

Copyright (c) 2024 Asian Journal of Medical Sciences



This work is licensed under a Creative Commons Attribution-NonCommercial 4.0 International License.

INTRODUCTION

Breast carcinoma is the most common cancer in women. Most breast cancers are epithelial, making mesenchymal neoplasms a rarity, with very few case reports and small studies described in the literature.¹⁻³

Breast sarcomas are a rare group of neoplasms that constitute de novo and therapy-related sarcomas, the latter being most common. Primary breast sarcoma is rare and accounts for <1% of breast malignancies and <5% of all soft tissue sarcomas.¹ Breast sarcomas were first described in 1887² and a generic term was given to malignant breast tumors thought to arise from the specialized mesenchymal tissue of the breast with a phyllodes-like pattern but lacking an epithelial component even on thorough histopathological sampling. Sarcomas arising from the

skin, muscle, and adjacent bone are excluded from this category.^{1,2,4,5}

Primary breast sarcomas, which occur mostly among women in their 5th or 6th decade of life and present as unilateral breast lumps growing more rapidly than breast carcinomas, can involve overlying skin. These tumors have a high risk of local recurrence, and the prognosis is very poor. Their spread is by local invasion or hematogenously involving the liver, lungs, and bone marrow.² They are a heterogeneous group, like soft tissue sarcomas of other parts of the body, and are classified according to their cell of origin.^{2,3,5,6}

Most cases of breast sarcomas, especially angiosarcomas, are secondary to radiotherapy following breast conservation treatment. Other contributing factors are chronic

Address for Correspondence:

Dr. Gargi Raychaudhuri, Associate Professor, Department of Pathology, College of Medicine and Sagore Dutta Hospital, Kolkata, West Bengal, India. **Mobile:** +91-9830089734. **E-mail:** gargi_rc@yahoo.co.in

lymphedema of the breast and arm, pre-existing biphasic tumors of the breast, and hereditary conditions like Li-Fraumeni syndrome or neurofibromatosis.^{1,6}

Here we are presenting 4 cases of primary breast sarcoma that we found over the course of 7 years in our institution.

CASE PRESENTATION

Methodology and criteria for case selection

We have selected all those patients who had undergone mastectomy for breast lump in our institution and histologically confirmed to be the cases of primary stromal sarcoma of breast with the help of immunohistochemical markers during the last 7 years (2017–2023). Patients with a history of preoperative chemotherapy or radiotherapy for the same lesion or sarcomas metastatic to the breast were excluded from our selection list.

Case 1

A 30-year-old female came with a surgery outpatient department with a complaint of a painful left breast lump that was gradually increasing in size. High-resolution sonography showed ill-defined heterogeneous solid SOL in the left breast, with increased vascularity extending to all quadrants (BIRADS 4A) (Figure 1a). There were no clinically or radiologically enlarged lymph nodes, and there was no history of radiotherapy.

The cytological picture revealed a malignant mesenchymal tumor with a predominance of pleomorphic spindle cells in the background of hemorrhage and necrosis.

We received a simple mastectomy specimen with one lobulated fleshy necrotic growth involving all quadrants. One skin nodule was identified overlying the lump.

Microscopic examination revealed a partially circumscribed hemorrhagic tumor showing plump spindle cells with anastomosing vascular channels (Figure 1c). Individual cells showed moderate pleomorphism and nuclear hyperchromasia with a high mitotic count (Figure 1d). Immunohistochemistry (IHC) revealed tumor cells to be positive for CD31 (Figure 1b), CD34, and vimentin, while negative for pan-CK.

The tumor was diagnosed as angiosarcoma of the breast.

Case 2

A 40-year-old female presented with right-sided, gradually increasing breast mass (Figure 2c) with no palpable axillary lymph node and no contralateral breast involvement. USG revealed a large mixed echogenic soft tissue lesion

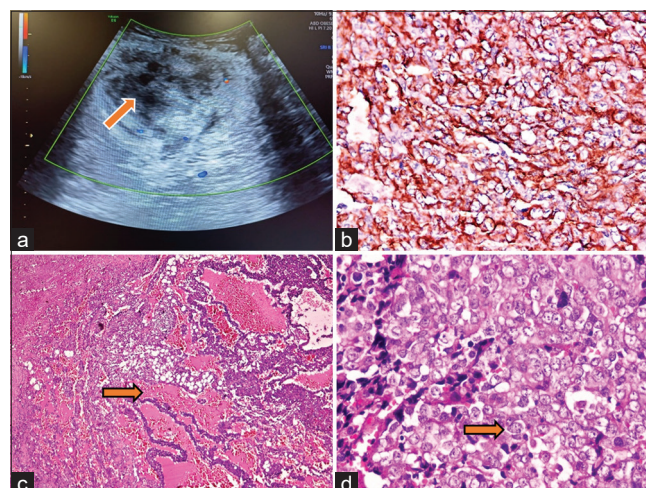


Figure 1: (a) Hypoechoic mass on USG in a case of angiosarcoma of breast, (b) CD31 (immunohistochemistry, $\times 400$) positive cells (c) photomicrograph showing low power view of angiosarcoma (H and E, $\times 100$) with many vessels formation, (d) high grade epithelioid cells of angiosarcoma (H and E, $\times 400$)

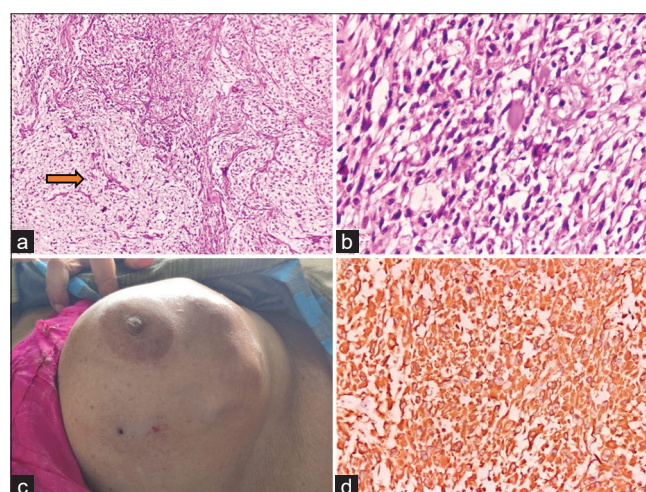


Figure 2: (a) Low power view of myxofibrosarcoma of breast (H and E, $\times 100$) (myxoid area marked with arrow), (b) high power view of myxofibrosarcoma (H and E, $\times 400$), (c) large breast mass of myxofibrosarcoma, (d) diffusely vimentin positive cells (immunohistochemistry, $\times 400$)

with irregular margins, cystic spaces, moderate internal vascularity, and no detectable calcification (BIRADS 4B). A core needle biopsy was done, following which it was diagnosed as a malignant mesenchymal neoplasm of the breast.

Microscopic examination revealed a spindle cell neoplasm with atypically elongated to plump spindle cells arranged in storiform as well as a herringbone pattern in a myxoid background (Figure 2a). Individual cells are pleomorphic, having hyperchromatic nuclei and focally vacuolated cytoplasm (Figure 2b). Focal cystic areas were seen. The mitotic count was 5/10 HPF.

IHC showed tumor cells were positive for vimentin (Figure 2d) only but negative for pancytokeratin, S100, CD34, SMA, desmin, and HMB45.

The tumor was diagnosed as myxofibrosarcoma of the breast.

Case 3

A 49-year-old female presented with a left-sided painful ulcerated large breast lump, which was clinically and by ultrasonography (Figure 3a) diagnosed as a phyllodes tumor. FNAC revealed a malignant spindle cell tumor with a doubtful epithelial component, raising suspicion of malignant phylodes or stromal tumors.

The patient underwent a simple mastectomy, followed by histopathological examination grossly showing greyish-white, solid, along with some cystic and necrotic areas. Microscopically, a mesenchymal neoplasm was found, which was composed of spindle and polygonal cells arranged in hyper- as well as paucicellular areas in a storiform pattern. Individual cells showed pleomorphism, hyperchromatic nuclei, focally clear cytoplasm, and occasional fibrillary processes (Figure 3c and d). Few necrotic areas are seen. Neither epithelial carcinomatous areas nor entrapped breast acini or ducts were seen on thorough sectioning. The mitotic count was $>10/10$ HPF.

IHC was done on the tumor, which was positive for vimentin and S100 (Figure 3b).

The tumor was diagnosed as a malignant peripheral nerve sheath tumor of the breast.

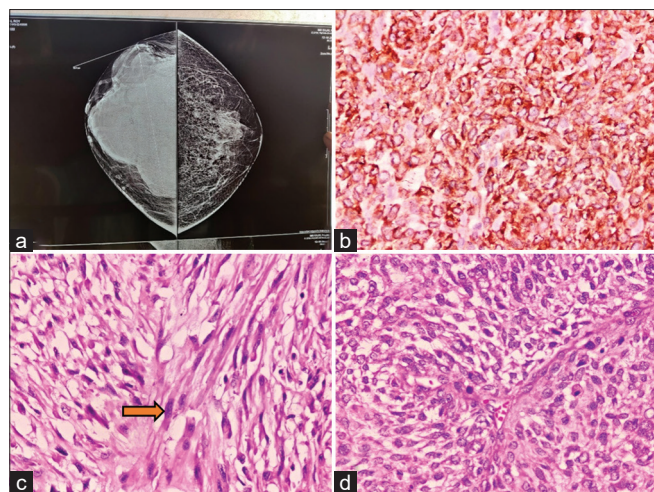


Figure 3: (a) USG in a case of MPNST of breast, (b) S100 (immunohistochemistry, $\times 400$) positive cells, (c) and (d) Photomicrograph showing high power view of MPNST (H and E, $\times 400$). MPNST: Malignant peripheral nerve sheath tumour

Case 4

A previously healthy 52-year-old woman with no previous breast disease and no familial history presented with a large tumor of the left breast that was rapidly growing with ulcers on the overlying skin (Figure 4a). Clinical suspicion was of phyllodes tumor. A modified radical mastectomy was done, and histopathology revealed the features of a high-grade sarcoma with marked mitotic activity and a diffusely infiltrative pattern (Figure 4c and d). The lymph nodes were uninvolved.

IHC showed positive results with vimentin stain only (Figure 4b). The tumor was diagnosed as primary stromal sarcoma, not otherwise specified.

DISCUSSION

Primary sarcoma of the breast constitutes a specific clinicopathologic entity, and it should be differentiated from the two main confounding entities in differential diagnosis: malignant phyllodes tumor and metaplastic carcinoma.^{5,7} The incidence, histological type, and clinical course of sarcomas of the breast are not well established to date due to the rarity of these tumors and a lack of definition in various reports.^{1,6}

Controversy still exists about the term “stromal sarcoma.” In 1962, when Berg *et al.*,^{4,8} introduced the term, stromal sarcoma breast, it was meant to unify all breast sarcomas other than cystosarcoma phyllodes, indicating their common origin from breast stroma. The classification proposed for extremity and truncal sarcomas is generally applied to breast sarcomas as well. Adem *et al.*, however,

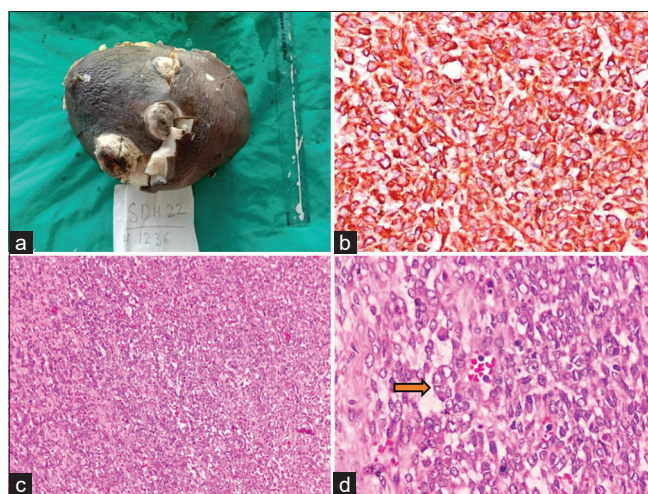


Figure 4: (a) Huge breast mass with skin ulceration in a case of primary stromal sarcoma, not otherwise specified, (b) diffusely vimentin positive cells (immunohistochemistry, $\times 400$), (c) photomicrograph showing low power view of the breast sarcoma (H and E, $\times 100$), (d) high grade pleomorphic cells of breast sarcoma (H and E, $\times 400$)

proposed that the term “stromal sarcoma” may be appropriate only for exceptionally rare sarcomatous tumors derived from specialized hormone-sensitive mammary stroma.⁷

Another confounding factor is angiosarcoma. This malignant mesenchymal neoplasm occurs disproportionately more often in the breast than at other sites in the body. Few studies preferred to keep angiosarcoma out of the rare stromal sarcoma series because of its occurrence in substantial numbers of cases in their initial observation, which might have corrupted the field of otherwise rare pathologies.⁵⁻⁷

The current classification schema adopted by the World Health Organization follows the general principle of classification of soft tissue neoplasms occurring elsewhere in the body. Likewise, the grading of such tumors is preferably done by the FNCLCC system.^{9,10}

Early diagnosis and surgical intervention are crucial in treatment, which relies predominantly on histopathological examination as imaging characteristics are mostly non-specific.⁵

In addition to specific morphological features, immunohistochemical analysis is sometimes valuable in excluding phyllode tumor and metaplastic breast carcinomas. Distinction with malignant phyllodes tumors and metaplastic carcinomas is important for treatment as well as for prognosis. A biphasic tumor with leaf-like architecture, stromal overgrowth, and atypia supports the diagnosis of malignant phyllodes, while finding a carcinomatous component or positivity for cytokeratin in neoplastic spindle cells favors a diagnosis of metaplastic carcinoma. Overall, the prognosis is poor and depends on tumor grade, size, and histological type.^{1,2,5-7}

The treatment of choice for primary breast sarcoma is mastectomy without axillary lymph node dissection. Axillary lymph dissection should be done only when nodes are involved clinically. Whereas surgical resection with a wide excision margin remains the gold standard of treatment for phyllodes tumors, metaplastic carcinomas are treated with mastectomy with axillary lymph node dissection or breast conservation surgery for smaller tumors.^{3,5}

CONCLUSION

In conclusion, we can say that primary breast sarcomas are rare, locally recurrent tumors with a poor prognosis.

Clinically, they are most often diagnosed as benign fibroadenomas, phyllodes tumors and carcinomas. Even radiology has a limited role and often cannot differentiate between sarcomas, malignant phyllodes tumors, and carcinomas. Histopathology, along with immunohistochemistry, plays a central role, as early diagnosis and complete microscopic resection are associated with a better prognosis.

ACKNOWLEDGMENT

None.

REFERENCES

1. Radovanovic A, Gligorijevic J, Zivkovic N and Anđelković-Matic M. Primary stromal sarcoma of the breast. *Arch Oncol.* 2012;20(1-2):24-25.
<https://doi.org/10.2298/ao01202024r>
2. Kumar S, Sharma J, Ralli M, Singh G, Kalyan S and Sen R. Primary stromal sarcoma of breast: A rare entity. *Iran J Pathol.* 2016;11(5):469-473.
3. Igot MO and Fernando GY. Primary breast sarcoma. *J Clin Case Rep Images.* 2022;2(3):9-21.
<https://doi.org/10.14302/issn.2641-5518.jcci-22-4323>
4. Berg JW, De Crosse JJ, Fracchia AA and Farrow J. Stromal sarcomas of the breast. A unified approach to connective tissue sarcomas other than cystosarcoma phyllodes. *Cancer.* 1962;15:418-424.
[https://doi.org/10.1002/1097-0142\(196203/04\)15:2<418:aid-cncr2820150226>3.0.co;2-v](https://doi.org/10.1002/1097-0142(196203/04)15:2<418:aid-cncr2820150226>3.0.co;2-v)
5. Ahuja M, Mallya V, Mandal S, Tomar R, Aggarwal R, Khurana N, et al. Primary breast sarcoma: A case series. *Indian J Pathol Microbiol.* 2022;65(1):152-156.
https://doi.org/10.4103/ijpm.ijpm_1315_20
6. Voutsadakis IA, Zaman K and Leyvraz S. Breast sarcomas: Current and future perspectives. *Breast.* 2011;20(3):199-204.
<https://doi.org/10.1016/j.breast.2011.02.016>
7. Adem C, Reynolds C, Ingle JN and Nascimento AG. Primary breast sarcoma: Clinicopathologic series from the Mayo Clinic and review of the literature. *Br J Cancer.* 2004;91(2):237-241.
<https://doi.org/10.1038/sj.bjc.6601920>
8. Hefny AF, Bashir MO, Joshi S, Branicki FJ and Abu-Zidan FM. Stromal sarcoma of the breast: A case report. *Asian J Surg.* 2004;27(4):339-341.
[https://doi.org/10.1016/s1015-9584\(09\)60064-6](https://doi.org/10.1016/s1015-9584(09)60064-6)
9. WHO Classification of Tumours Editorial Board. World Health Organization Classification of Soft Tissue and Bone Tumours. WHO Classification of Tumours Series. 5th ed., Vol. 3. Lyon, France: IARC Press; 2020. Available from: <https://publications.iarc.fr/Book-And-Report-Series/Who-Classification-Of-Tumours/Soft-Tissue-And-Bone-Tumours-2020>
10. Goldblum JR, Folpe AL and Weiss SW, editors. Enzinger and Weiss's Soft Tissue Tumors. 7th ed. Philadelphia, PA: Mosby Elsevier; 2020. Available from: <https://www.us.elsevierhealth.com/enzinger-and-weiss-soft-tissue-tumors-9780323610964.html>

Authors Contribution:

SGS- Concept, design and reporting pathologist; **BC-** Case collection and manuscript writing; **KS-** Manuscript preparation and revision of manuscript; **GR-** Concept, design and reporting pathologist.

Work attributed to:

College of Medicine and Sagore Dutta Hospital, Kolkata, West Bengal, India.

Orcid ID:

Dr. Soumita Ghosh Sengupta - <https://orcid.org/0000-0003-1748-1720>

Dr. Bidisha Chakraborty - <https://orcid.org/0000-0002-1984-0793>

Dr. Kaushik Saha - <https://orcid.org/0000-0002-7151-1268>

Dr. Gargi Raychaudhuri - <https://orcid.org/0009-0003-5805-9208>

Source of Support: Nil, **Conflicts of Interest:** None declared.