

Unraveling the anatomy of toe extensors: An aid to the clinical implications



Noor us Saba¹, Pratibha Shakya², Heena Singh³, Nikhil Aggarwal⁴, Punita Manik⁵, Navneet Kumar⁶

^{1,2,3}Assistant Professor, ^{5,6}Professor, Department of Anatomy, King George's Medical University Lucknow, Uttar Pradesh, ⁴Senior Resident, Department of Anatomy, Maulana Azad Medical College, New Delhi, India

Submission: 29-12-2023

Revision: 26-02-2024

Publication: 01-04-2024

ABSTRACT

Background: The extensor tendons of the foot are crucial for maintaining the intricate movements and stability of the foot and ankle complex. Understanding these variations is essential for health-care professionals involved in foot-related pathologies. **Aims and Objective:** The study was conducted to identify and document variations in extensor tendons of the foot during routine dissection of human cadavers and to highlight their clinical significance. **Materials and Methods:** This was an observational study conducted in the Department of Anatomy, King George's Medical University, Lucknow, India. Eight embalmed cadavers were examined, and the dorsum of the foot was dissected to explore the proximal and distal attachments of extensor muscles. **Results:** We observed unilateral variations in extensor tendons of the feet of three limbs during routine dissection. First case showed a bifurcation of extensor hallucis longus, giving tendons to great toe as well as 2nd toe. Second case showed a variation in extensor digitorum longus tendon of the 4th toe giving lateral and medial slips along with its main tendon. The medial slip further gave medial and lateral divisions to merge distally with the long tendons of 3rd and 4th toe, respectively. The third case depicted the bifurcation of extensor hallucis brevis to give tendinous slips to great toe and 2nd toe, respectively. **Conclusion:** Knowledge of these variations in extensor tendons of foot is crucial for accurate interpretation of diagnostic imaging, surgical planning, and optimizing treatment outcomes.

Key words: Variations; Extensor tendons; Foot; Clinical importance

INTRODUCTION

The long tendons in the dorsum of foot, from lateral to medial, are fibularis tertius, extensor digitorum longus (EDL), extensor hallucis longus (EHL), and tibialis anterior. Deep to these long extensors, extensor digitorum brevis (EDB) muscle is present which gives a slip to the great toe, named as extensor hallucis brevis (EHB) and three small slips to second, third, and fourth toe, respectively. Normally, tendons of the brevis muscle merge distally with long extensor tendons from their lateral side.¹

Variations in normal anatomy of the foot mostly represent developmental abnormalities such as, primitive tendon plate to develop EHL may give 2–3 separate slips² and

variations of EDL can occur during 5th week of intrauterine life.³ During ontogenesis of muscular pattern in EDB muscle, accessory heads of the muscle fasciculi might result in supernumerary tendon of the muscle.⁴ These variations manifest as painful foot on some occasions due to impingement of the surrounding structures.⁵

Although various studies have already been conducted representing the variations in extensor tendons of foot,^{6–15} the variations found in our study are rare and have not been previously reported in the literature. Description of tendons in foot is prerequisite for the surgeons to decide for suitable graft in various reconstructive surgeries and for the analysis of injuries in tendons.¹⁶ The purpose of this study is to further enhance the knowledge of variations in extensor tendons of foot and its clinical implications.

Access this article online

Website:

<http://nepjol.info/index.php/AJMS>

DOI: 10.3126/ajms.v15i4.61182

E-ISSN: 2091-0576

P-ISSN: 2467-9100

Copyright (c) 2024 Asian Journal of Medical Sciences



This work is licensed under a Creative Commons Attribution-NonCommercial 4.0 International License.

Address for Correspondence:

Dr. Noor us Saba, Assistant Professor, Department of Anatomy, King George's Medical University, Lucknow - 226003, Uttar Pradesh, India.
Mobile: +91-9368480101. E-mail: noorussaba83@gmail.com

Aims and objectives

Aim of the study was to ascertain the anatomical features of extensor tendons in cadavers. Objectives were focused on finding of possible variations according to the number and differences in insertions of accessory tendons and adding the knowledge to already classified variations in the literature.

MATERIALS AND METHODS

The study was conducted in the department of Anatomy, King George's Medical University, Lucknow, India. The lower limbs of eight embalmed cadavers were studied during routine dissection for medical graduates. No indications of damage or deformation on either right/left foot of any cadaver were seen. Dorsum of foot of all the cadavers was neatly dissected and proximal and distal attachments of extensor muscles were precisely explored. Three unilateral variations in extensor tendons of foot were recorded and photographed.

Observations

Case I

Presence of the bifurcated EHL tendon was noticed in the right foot of 63-year-old female cadaver. The deep fascia of the anterior leg was meticulously split, and the extensor retinaculum was explored. Individual muscles and tendons were observed from top to the bottom. Originating from the middle portion of the anterior surface of the fibula and the interosseous membrane, the EHL tendon was discovered to be divided into two slips (medial and lateral) before reaching the first metatarsal base. On further dissection, it was seen that the medial slip formed the extensor tendon of great toe, while the lateral slip emerged as the extensor tendon of 2nd toe. The EDL tendon divided to give extensor tendons of 3rd, 4th, and 5th toe. As a customary finding, EHL muscle was innervated by deep peroneal nerve (Figure 1a and b).

Case II

The exploration of anterior compartment of leg and dorsum of foot of a 62-year-old male cadaver, unveiled an unusual variant involving the EDL tendon of the 4th toe. A lateral slip (4A) and a medial slip (4C) along with its main tendon (4B) was noticed (Figures 2a and 3c); lateral slip (4A) was merged with 4th tendon of EDB muscle to join distally with main tendon (4B) of the 4th toe (Figures 2b and 3c), and medial slip (4C) had lateral and medial divisions. The lateral division of the medial slip of EDL tendon of 4th toe (4C-L) was merged with 4B (Figure 3a and c), while the medial division (4C-M) was merged first with EDB tendon of 3rd toe to join distally with the EDL tendon of 3rd toe (Figure 3b and c).

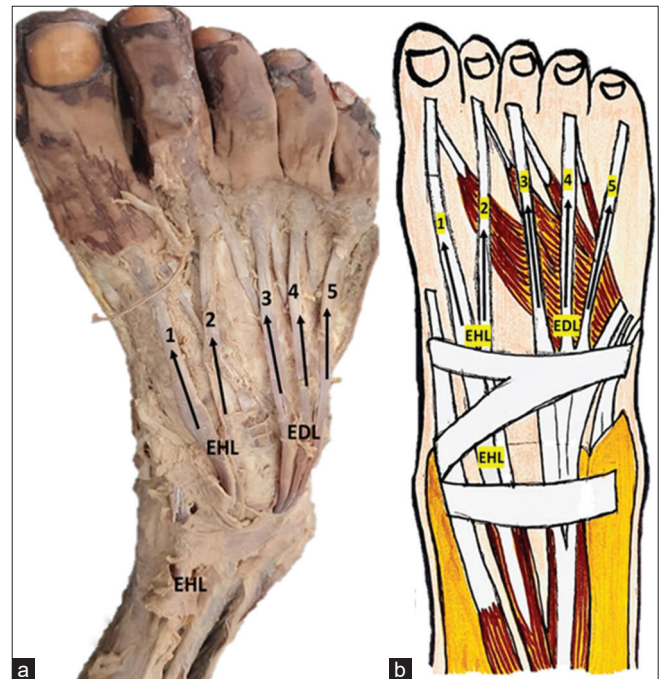


Figure 1: (a) Cadaveric image showing a bifurcation of extensor hallucis longus (EHL) muscle. Numbers 1 and 2 are long extensor tendons of great toe and 2nd toe, coming from EHL muscle. Numbers 3, 4, and 5 are long extensor tendons of 3rd, 4th and 5th toe, coming from extensor digitorum longus (EDL) muscle. (b) Schematic drawing of EHL muscle bifurcation and long extensors of EDL muscle for 3rd, 4th, and 5th toe

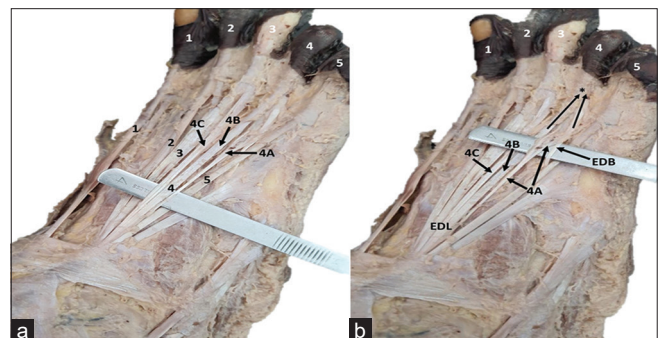


Figure 2: (a) Cadaveric image showing the extensor digitorum longus (EDL) tendon. Numbers 1, 2, 3, 4, and 5 are the long tendons of all the 5 toes, respectively. 4A and 4C are lateral and medial slips of main tendon (4B) of the 4th toe. (b) The lateral slip (4A) merged with 4th tendon of extensor digitorum brevis (EDB) muscle to join distally with main tendon (4B) for the 4th toe, shown by distal two arrows and asterisk (*) mark

Case III

A bifurcated EHB tendon was observed in the right foot of a 71-year-old male cadaver. Main EDB muscle was seen to be arising from dorsal surface of calcaneus and traced distally to notice the EHB and other slips for middle 3 toes. Further, on doing finer dissection and understanding the surrounding structures, it was found that great toe and 2nd toe were receiving the brevis tendon from EHB muscle. It was observed that EDL tendon of 2nd toe was receiving brevis tendon both from medial and lateral side (Figure 4a and b).

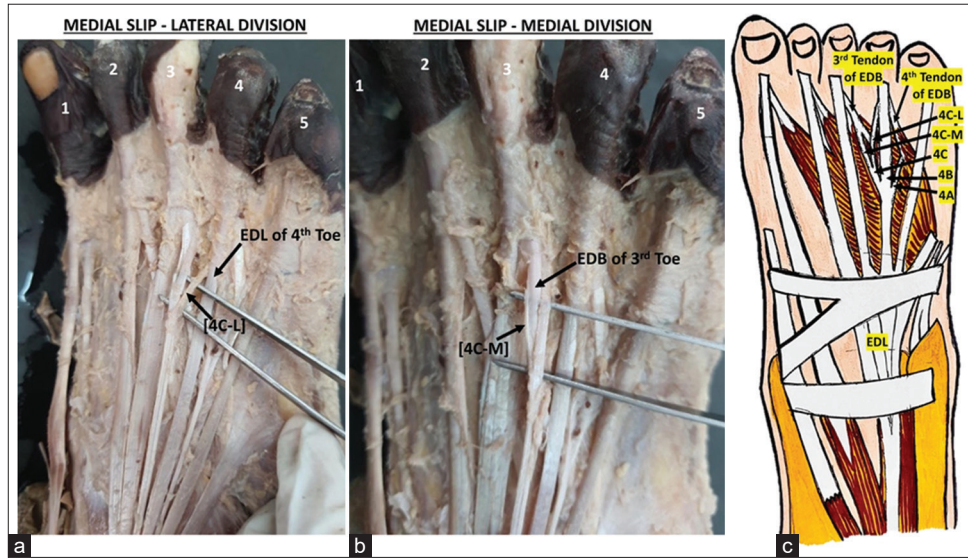


Figure 3: The medial slip (4C) of extensor digitorum longus (EDL) tendon (marked as number 4) for the 4th toe, further gave lateral (4C-L) and medial (4C-M) divisions. (a) The lateral division (4C-L) merged with EDL of 4th Toe (4B). (b) The medial division (4C-M) merged first with extensor digitorum brevis (EDB) tendon of 3rd toe to distally join the main EDL tendon of the 3rd toe. (c) Schematic drawing of EDL tendon of 4th toe; lateral slip (4A) merging with EDB of 4th toe to join distally with EDL of 4th toe (4B), medial slip (4C) gives lateral division (4C-L) merging EDL of 4th toe (4B), and medial division (4C-M) merging EDB tendon of 3rd toe to join distally with EDL tendon of 3rd toe

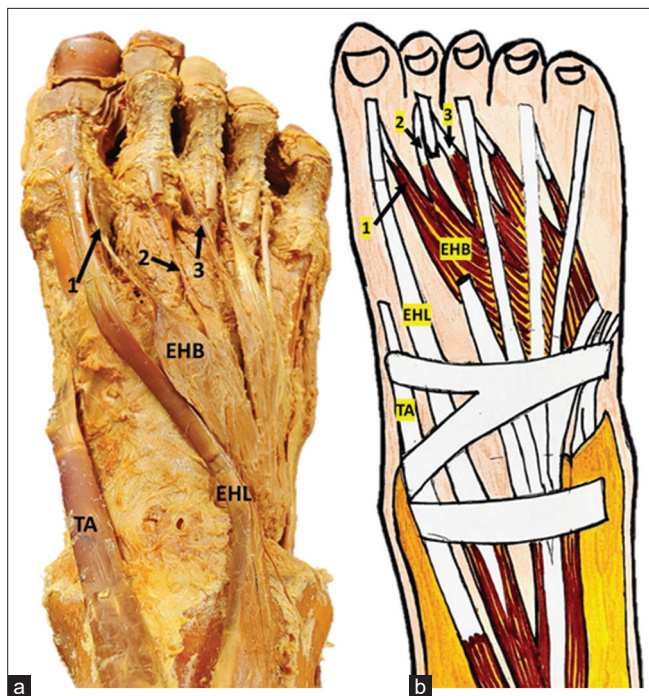


Figure 4: (a) Cadaveric image showing the bifurcation of extensor hallucis brevis (EHB). Number 1 is brevis tendon for great toe. Numbers 2 and 3 are the brevis tendon of second toe in both lateral and medial side of extensor digitorum longus (EDL) tendon of 2nd toe. (b) Schematic drawing of EHB tendons; number 1 for the great toe, numbers 2 and 3 for the second toe in both lateral and medial side of EDL tendon

DISCUSSION

To undertake tendinoplasty, tendon transfer, or resection procedures on the foot, plastic, and orthopedic surgeons must be aware of the altered forms of extensor tendons

of the foot. Many studies are documented to show multiple muscular variations, unilateral, or bilateral, in extensors of foot in cadavers.⁶⁻¹⁵ In the present study, bifurcation of EHL tendon was having medial and lateral slips. Medial slip was the main extensor tendon of great toe, whereas lateral slip was extensor tendon of 2nd toe. Accessory tendons of EHL muscle has been found in multiple studies with variable representations.^{11,17,18} Structure and function of the accessory tendons of EHL were described to suggest the novel treatments of hallux valgus deformity.² An idea of classification of different patterns of EHL tendon had been offered according to the numbers of accessory tendons and their distal insertions. Awareness of these types of variations is useful in the lower limb surgeries of the patients having hallux deformity.^{11,14}

Shikha et al. found a bifurcated tendon of EHL, showing its insertion on terminal and proximal phalanx of great toe,¹⁵ unlike our study. In a review literature, for the classification of EHL tendon variations, none of the type described the findings of our study.¹⁹ A systematic classification of EHL tendon is essential to plan various other surgical interventions on foot and ankle region. Some morphological variations denote alteration in phylogenetic development of the structures attributing to incomplete evolution of the muscle.⁹ Extensors in the ankle require quick diagnosis and treatment to prevent impending deformities after ankle trauma. Additional bands of extensor tendons, functionally, are useful to maintain normal functions of the muscle even after injury of the tendon.¹⁷

Understanding of the variations should be a part of clinician's daily practices and can be used to modify methods of surgeries in future.¹⁷ EDL tendon was seen to give tendon of 3rd, 4th, and 5th toe and the lateral slip of EHL tendon was replacing the tendon of EDL of 2nd toe in our observation. This feature can be missed by surgeons to confuse it by EDL tendon due to its insertion on the 2nd toe. In the absence of substantiating studies, still it is believed that variations of EHL can predispose damage in the foot. In tendon transfer surgeries, EHL is used to correct hallux and equinovarus deformities. It shows usefulness of the information to prevent confusion and mistakes in surgeries. Special emphasis is needed to understand the different types of variable extensor muscle tendons and their incidence for the surgeons. Preoperative diagnostic ultrasonography, for the identification of EHL variations and their relations with surrounding structures, improve the whole operative procedure and outcome.¹²

EDL muscle works in the long stride and slow walking of an individual along with its main use in the gait cycle.⁹ The unique presentation of EDL tendon, having multiple slips and their distal merging with the long tendons and brevis tendons both medially and laterally, was seen in our study. Thin and weak insertions of EDL muscle might affect its function during walking.⁹ Kamaşak et al. found double tendon of EDL in an 80-year-old cadaver, one medial and accessory lateral tendon. Medial tendon was further divided distally to give long extensor tendons of second and third toe, whereas lateral accessory tendon gave extensor slips to fourth and fifth toe.⁸ Abhinitha et al. observed only three slips of EDL tendon for second, third, and fourth toes in a 55-year-old female cadaver.⁹ There was absence of EDL muscle and tendon on the right side along with a small tendon of EDL on the left side for fifth toe in a study of Newton.²⁰

Contractures of EDL are of special concern for the clinicians. In correction of the foot deformities this muscle is used, especially in tarsometatarsal surgeries. Transferred tendon is sutured on the main tendon before the origin of small slips by surgeons to restore the function of toe extension in case of foot drop.⁹ Variations of EDL muscle can affect dorsiflexion of toes and movements in the ankle. Initial contact phase along with the midstance and swing of the gait cycle may also get restricted. Accessory tendon slips can be used in replacement of damaged tendons,⁸ tendon-Achilles, and lateral ankle ligaments' reconstruction by the surgeons.³

A thin EDB muscle arising from the calcaneum, giving small tendon slips of EHB and three more to medial four toes, was of little clinical importance till recently. EDB was first reported to be used as free flap in 1977, after which this muscle gets special consideration for the use in different plastic and reconstructive surgeries.^{4,21} The present case depicted distal merging of accessory tendon of EHB muscle

with the tendon of EDL of the second toe on the medial side of EDL. Second toe thus received the tendon of EDB muscle both from lateral and medial side. Similar findings were seen in the second toe of a 55-year-old cadaver by Sirasanagandla et al.³ Accessory tendons from EHB muscle has already been seen with innervation of the branches coming from deep peroneal nerve.^{10,22} A long tendon of accessory EDB muscle inserting on the proximal phalanx of the fifth toe was observed in a 75-year-old cadaver in Turkey.¹³

Orthopedic surgeons use EDB for surgical treatment of ankle instability. In plastic surgeries, microvascular grafting of EDB has been used in some cases of long-standing facial nerve palsy. Awareness of arterial supply and nerve innervation of these variations and pre-operative Doppler studies are becoming prerequisite for using the muscles in different reconstructive procedures.²¹ Main extensors of toes are long extensors of the foot due to which EDB can be used to correct toe and ankle deformities without compromising extension of the toes.³ Island flap and free flap are some other uses of EDB muscle for the treatment of soft tissue defects in ankle and foot.⁴

Limitations of study

Several limitations have been noted in the study - first, number of cases having tendon variations were less to ascertain any significant statistical test. Second, measurements or morphometry are not taken and study was focused only on the morphology of the extensor tendons. Third, there was no significant association described between the gender and variability of toe extensors.

CONCLUSION

Variations of the tendinous slips of long and short muscles on dorsum of foot are less studied until recently. There variable origins, insertions, and innervations are becoming more important for the clinicians, plastic surgeons, and orthopedic surgeons. They help in selection of accessory tendons for tendon transfer surgeries. Abnormal patterns of extensor tendon insertions in the foot may interfere with the normal functioning of the muscles. These types of findings should be reported generously so that the horizon of such variations will be increased and would be of great help to plastic and orthopedic surgeons.

ACKNOWLEDGMENT

We express our sincere gratitude to the selfless body donors who made this anatomical research possible. Their invaluable contribution enhances our knowledge and improves patient care. We extend our highest appreciation to these remarkable donors and their families.

REFERENCES

- Susan S. Gray's Anatomy - The Anatomical Basis of Clinical Practice. 42nd ed. Amsterdam: Elsevier; 2020. p. 1416-1418.
- Li Y, Zhang JY, Zhao XY, Pan LY, Jin DH, Xu HX, et al. Anatomical study of the accessory tendon of the extensor hallucis longus muscle and its clinical application. *Clin Orthop Surg*. 2021;13(2):261-265. <https://doi.org/10.4055/CIOS20054>
- Sirasanagandla SR, Satheesha BN, Bhat KM, Swamy RS and Deepthinath R. Anatomical variations of extensor tendons anatomical variation of the extensor tendons of the second toe in the dorsum of the foot: A case report. *J Surg Acad*. 2013;3:71-73.
- Sirasanagandla SR, Swamy RS, Nayak SB, Somayaji NS, Rao MK and Bhat KM. Analysis of the morphometry and variations in the extensor digitorum brevis muscle: An anatomic guide for muscle flap and tendon transfer surgical dissection. *Anat Cell Biol*. 2013;46(3):198-202. <https://doi.org/10.5115/ACB.2013.46.3.198>
- Aparisi Gómez MP, Aparisi F, Bartoloni A, Ferrando Fons MA, Battista G, Guglielmi G, et al. Anatomical variation in the ankle and foot: From incidental finding to inductor of pathology. Part II: Midfoot and forefoot. *Insights Imaging*. 2019;10(1):69. <https://doi.org/10.1186/S13244-019-0747-1>
- Harşa MI, Kocsis L, Czundel AM, Dénes L and Pap Z. Anatomical variations of the peroneus tertius and extensor digitorum longus muscles - case presentation. *J Interdiscipl Med*. 2021;6:162-166. <https://doi.org/10.2478/JIM-2021-0025>
- Imosemi IO and Atiba FA. Anatomical variations of the musculoskeletal system-a review of literatures. *J Med Med Sci*. 2015;6(7):151-155. <https://doi.org/10.14303/jmms.2015.092>
- Kamaşak B, Kirındı MH, Ulcay T, Uzun A and Aycan K. An unique unilateral tendon variation of the extensor digitorum longus muscle. *Surg Radiol Anat*. 2022;44(11):1427-1430. <https://doi.org/10.1007/S00276-022-03040-4>
- Abhinitha P, Mohandas Rao KG, Rao AS, Satheesha Nayak B and Shetty S. Anomalous pattern of tendinous slips of peroneus tertius and extensor digitorum longus muscles in the foot- a clinically important variation. *Gulhane Med J*. 2014;56:179. <https://doi.org/10.5455/gulhane.15192>
- Won HJ and Oh CS. Muscular variations of extensor digitorum brevis muscle related with anterior tarsal tunnel syndrome. *Korean J Phys Anthropol*. 2018;31:35-39. <https://doi.org/10.11637/KJPA.2018.31.1.35>
- Park JH, Choi YJ, Lee M, Kim D, Kwon HW, Park KR, et al. Anatomical characteristics of extensor hallucis longus tendon variations and its clinical implications: A Korean cadaveric study. *Int J Environ Res Public Health*. 2022;19(16):9833. <https://doi.org/10.3390/IJERPH19169833>
- Zdilla MJ, Paulet JE, Lear JJ, Addie KM and Lambert HW. A review of extensor hallucis longus variants featuring a novel extensor primi internodii hallucis muscle merging with extensor hallucis brevis. *J Foot Ankle Surg*. 2018;57(6):1218-1220. <https://doi.org/10.1053/J.JFAS.2018.03.031>
- Erçikti N, Apaydın N and Acer N. An additional tendon of the extensor digitorum brevis muscle of the foot: Is there an accessory muscle? *Anatomy*. 2015;9:189-191. <https://doi.org/10.2399/ana.15.021>
- Al-Saggaf S. Variations in the insertion of the extensor hallucis longus muscle. *Folia Morphol (Warsz)*. 2003;62(2):147-155.
- Shikha S, Vandana M, Shweta K and Suri RK. Anomalous insertion of extensor hallucis longus and its clinical importance. *J Surg Acad*. 2018;8:31-34. <https://doi.org/10.17576/JSA.2018.0802.07>
- Morales-Orcajo E, Becerro De Bengoa Vallejo R, Losa Iglesias M and Bayod J. Structural and material properties of human foot tendons. *Clin Biomech (Bristol, Avon)*. 2016;37:1-6. <https://doi.org/10.1016/J.CLINBIOMECH.2016.05.014>
- Olewnik Ł, Podgórski M, Polgaj M, Ruzik K and Topol M. A cadaveric study of the morphology of the extensor hallucis longus - a proposal for a new classification. *BMC Musculoskelet Disord*. 2019;20(1):310. <https://doi.org/10.1186/S12891-019-2688-8>
- Casal D, Pais D, Angélica-Almeida M, Bilhim T, Santos A and Goyri-O'Neill J. Morphometric analysis of the extensor tendons of the hallux and potential implications for tendon grafting. *Eur J Anat*. 2010;14(1):11-18.
- Zielinska N, Tubbs RS, Ruzik K and Olewnik Ł. Classifications of the extensor hallucis longus tendon variations: Updated and comprehensive narrative review. *Ann Anat*. 2021;238:151762. <https://doi.org/10.1016/J.AANAT.2021.151762>
- Newton B. Unilateral absence of an extensor digitorum longus muscle and variations of toe tendons. *Int J Anat Var*. 2014;7:42-44.
- Swathi, Geetha GN, Athavale S, Pare V and Nayak SG. Morphology and neurovascular supply of extensor digitorum brevis muscle of the foot in humans: Implications for reconstructive surgeries. *Indian J Clin Anat Physiol*. 2017;4(1):106-111. <https://doi.org/10.18231/2394-2126.2017.0028>
- Patel J, Dupont G, Katsuta J, Iwanaga J, Olewnik Ł and Tubbs RS. Concomitant variations of the tibialis anterior, and extensor hallucis longus, and extensor hallucis brevis muscles. *Anat Cell Biol*. 2023;56(1):137-140. <https://doi.org/10.5115/ACB.22.009>

Authors Contribution:

NuS - Definition of intellectual content, literature survey, prepared first draft of manuscript, implementation of study protocol, data collection, data analysis, manuscript preparation, preparation of Figures, and submission of article; **PS** - Concept, design, clinical protocol, manuscript preparation, editing, and manuscript revision; **HS** - Concept, design, clinical protocol, manuscript preparation, editing, and manuscript revision; **NA** - Literature survey, design of study, interpretation, editing, and manuscript revision; **PM** - Review manuscript; **NK** - Review manuscript.

Work attributed to:

Department of Anatomy, King George's Medical University, Lucknow, Uttar Pradesh, India.

Orcid ID:

Noor us Saba - <https://orcid.org/0009-0001-0204-0378>
 Pratibha Shakya - <https://orcid.org/0000-0002-9919-8496>
 Heena Singh - <https://orcid.org/0000-0003-3086-585X>
 Nikhil Aggarwal - <https://orcid.org/0000-0002-4653-7060>
 Punita Manik - <https://orcid.org/0000-0001-9942-250X>
 Navneet Kumar - <https://orcid.org/0000-0002-8960-3531>

Source of Support: Nil, **Conflicts of Interest:** None declared.