

# A comparative study between 0.5% ropivacaine with 50 mcg of dexmedetomidine and 0.5% ropivacaine with 8 mg of dexamethasone for ultrasound-guided supraclavicular brachial plexus block – A randomized controlled study



Narasimhan MK<sup>1</sup>, Renganathan T<sup>2</sup>, Muralidaran S<sup>3</sup>, Rajaram Jayaraman<sup>4</sup>

<sup>1,4</sup>Assistant Professor, <sup>2</sup>Associate Professor, <sup>3</sup>Senior Resident, Department of Anaesthesiology, Stanley Medical College and Hospital, Chennai, Tamil Nadu, India

Submission: 16-12-2023

Revision: 27-02-2024

Publication: 01-04-2024

## ABSTRACT

**Background:** Peripheral nerve block analgesia is augmented using dexamethasone with perineural local anesthesia. **Aims and Objectives:** The study aimed to assess and compare the effects of dexmedetomidine and dexamethasone on the onset and duration of the sensory and motor block when added to 0.5% ropivacaine for the supraclavicular brachial plexus block. **Materials and Methods:** This randomized controlled study was conducted at the Department of Orthopedics, Government Stanley Medical College and Hospital, Chennai, for 6 months (March 2021–September 2021). Eighty patients were randomly allocated into two groups. Group A (40 patients) received ultrasound-guided supraclavicular brachial plexus block with 0.5% ropivacaine (30 mL) + dexmedetomidine 50 mcg (0.5 mL) + normal saline (1.5 mL). Group B (40 patients) received ultrasound-guided supraclavicular brachial plexus block with 0.5% ropivacaine (30 mL) + dexamethasone 8 mg (2 mL). **Results:** The dexmedetomidine group had a significantly faster onset of sensory anesthesia (3.9 min) than the dexamethasone group (7.8 min), with a higher duration. The dexmedetomidine group also had a faster onset of motor anesthesia (4.9 min) and a longer duration of analgesia (892.3 min) compared to the dexamethasone group (538 min). The dexmedetomidine group also had a longer duration for rescue analgesia (906 min) than the dexamethasone group (727 min). Visual Analog scores at 10, 14 and 24<sup>th</sup> h were lower in the dexmedetomidine group than in the dexamethasone group, which is statistically significant ( $P < 0.001$ ). **Conclusion:** Dexmedetomidine has a faster onset, longer duration, longer analgesia, and prolonged duration for rescue analgesia compared to dexamethasone for ultrasound-guided supraclavicular brachial plexus block, with bradycardia and sedation as side effects.

**Key words:** Supraclavicular brachial plexus block; Dexmedetomidine; Ultrasound-guided dexamethasone; Ropivacaine; Rescue analgesia

## INTRODUCTION

Successful peripheral neural blocks widen the scope of an anesthesiologist in providing anesthetic care. The ultrasonographic visualization of the nerves to be blocked

is a relatively new technique that holds promise for the future. This allows direct visualization of peripheral nerves, the block needle, and local anesthetic distribution. The past few years have observed a great increase in the use of ultrasound for regional nerve blocks.<sup>1,2</sup> A brachial plexus

### Access this article online

#### Website:

<http://nepjol.info/index.php/AJMS>

DOI: 10.3126/ajms.v15i4.60268

E-ISSN: 2091-0576

P-ISSN: 2467-9100

Copyright (c) 2024 Asian Journal of Medical Sciences



This work is licensed under a Creative Commons Attribution-NonCommercial 4.0 International License.

### Address for Correspondence:

Dr. Rajaram Jayaraman, Assistant Professor, Department of Anaesthesiology, Stanley Medical College and Hospital, Chennai, Tamil Nadu, India. **Mobile:** +91-9884453390. **E-mail:** narasimhan\_mmc@yahoo.co.in

block for upper limb surgeries offers an effective alternative to general anesthesia, providing intraoperative analgesia, prolonged post-operative analgesia, reduced stress response, and minimizing the requirement for sedatives and anesthetic drugs. This block can be administered through different routes, including the inter-scalene, supraclavicular, infraclavicular, and axillary approaches.<sup>3</sup> However, the supraclavicular approach is effective because it is colloquially dubbed as the spinal anesthesia of the arm. One of the characteristic features of the brachial plexus at the supraclavicular region is the visibility of the nerve is better as it is at a shallow depth (20–30 mm), and it is also compactly packed.<sup>4,5</sup>

The search for the best adjuvant to local anesthetics for nerve blocks for rapid onset and prolonged duration of analgesia with fewer side effects has been never-ending. Various adjuvants such as opioids, neostigmine, midazolam, hyaluronidase, alpha 2 adrenergic receptor agonists, and dexamethasone have been used to modify the onset of action, enhance quality, prolong duration, and post-operative analgesia. Steroids have very good anti-inflammatory as well as analgesic properties. When steroids are injected around the nerves, they influence the block to a great extent. Various studies conducted in animals and humans showed that adding dexamethasone to local anesthetic drugs considerably prolonged the block duration. Ropivacaine (0.5%), as an (S)-stereoisomer, is less lipophilic than bupivacaine. It is increasingly used for regional nerve blocks as the threshold of cardiovascular and central nervous system toxicity is higher for ropivacaine than bupivacaine. A newer local anesthetic, ropivacaine, is known to have less cardiotoxic. However, the onset of action and duration of effect are not as favorable as the older drug bupivacaine. For brachial plexus block, concentrations of ropivacaine used are between 0.25% and 0.75%. The most preferred concentration is 0.5%.<sup>6</sup>

Some studies aim to improve the outcome of a supraclavicular brachial plexus block by adding adjuncts to the local anesthetics. Peripheral nerve block analgesia is augmented by using dexamethasone with perineural local anesthesia.<sup>7,8</sup> Another alpha-adrenergic agonist, dexmedetomidine, provides better pain management and anesthesia when mixed with local anesthetics. These adjuncts tend to improve the quality of the block given by ropivacaine.<sup>9,10</sup> Comparative and also single-centric studies that assess and compare the effects of dexmedetomidine and dexamethasone on the onset and duration of sensory and motor block when added to 0.5% ropivacaine for supraclavicular brachial plexus block are minimal.<sup>11,12</sup>

The study aimed to assess and compare the effects of dexmedetomidine and dexamethasone on the onset and

duration of sensory and motor block when added to 0.5% ropivacaine for the supraclavicular brachial plexus block.

### Aims and objectives

To assess and compare the effects of Dexmedetomidine and Dexamethasone on onset and duration of sensory and motor block when added to 0.5% Ropivacaine for supraclavicular brachial plexus block.

- Onset of sensory block when added to 0.5% Ropivacaine for supraclavicular brachial plexus block.
- Duration of sensory block when added to 0.5% Ropivacaine for supraclavicular brachial plexus block.
- Onset of motor block when added to 0.5% Ropivacaine for supraclavicular brachial plexus block.
- Duration of motor block when added to 0.5% Ropivacaine for supraclavicular brachial plexus block.

## MATERIALS AND METHODS

This randomized controlled study was conducted at the Department of Orthopedics, Government Stanley Medical College and Hospital, Chennai, for 6 months March 2021–September 2021).

### Inclusion criteria

All consenting patients with upper limb surgeries were included, aged above 18 years and below 60 years, American Society of Anesthesiologists (ASA) PS I and II, both sexes and patients with unilateral upper limb surgeries.

### Exclusion criteria

Patients refusal, patients with known allergic reactions to local anesthetics, dexamethasone and dexmedetomidine, hemodynamic instability, history of bleeding disorders and coagulation abnormalities, patients with significant neurological, psychiatric, or neuromuscular disorders, hepatic, renal or cardiopulmonary abnormalities, parturients, breastfeeding mothers, ASA PS III and IV, and infection at needle insertion site were excluded from the study.

After institutional ethical committee approval and informed written consent, 80 patients were selected for the study based on inclusion and exclusion criteria. Eighty patients were randomly allocated into two groups. Group A (40 patients): ultrasound-guided Supraclavicular brachial plexus block with 0.5% Ropivacaine (30 mL)+Dexmedetomidine 50 mcg (0.5 mL) +normal saline (1.5 mL). Group B (40 patients): Ultrasound-guided Supraclavicular brachial plexus block with 0.5% Ropivacaine (30 mL)+Dexamethasone 8 mg (2 mL).

After a thorough pre-anesthetic evaluation in the pre-anesthetic assessment clinic and explaining the procedure to the patients the day before surgery, the patients were on nil per oral, according to fasting guidelines. All

patients were investigated for Hemoglobin, leukocyte count, platelet count, random blood sugar, renal function test (urea, creatinine) and liver function tests, 12 lead electrocardiography (ECG) and chest X-ray.

Group allocation was done in the operation theater before the supraclavicular brachial plexus block administration. The drug was prepared by an anesthesiologist who was not involved in the study. In the operating room, the temperature was maintained at 23° Celsius. A pulse oximeter, non-invasive blood pressure (NIBP), and ECG monitor were attached in the operation theater, and baseline parameters were recorded. After securing an 18G wide bore intravenous cannula (i.v), a balanced salt solution infusion was started. All patients were premedicated with an injection of midazolam at 0.03 mg/kg before the procedure. The supraclavicular brachial plexus block procedure was performed using ultrasound with a linear probe in-plane approach. The patient was supine, and the brachial plexus was visualized using real-time visualization of the artery, first rib, and hypoechoic nodules. The patients were observed throughout the surgery for any adverse effects of the drugs. Onset of sensory and motor blockade was assessed every 3 min till the loss of sensory and motor sensations and every 30 min until the regain of sensations and motor power. Vital parameters such as heart rate (HR), mean arterial blood pressure, and oxygen saturation were also recorded during this period.

Sensory block duration is the time from onset to first post-operative pain or visual analog scale >3, while motor block duration is the time interval between onset and complete motor function recovery. Sensory onset was assessed using spirit swab testing, while motor block was assessed using the Bromage score. Sedation was evaluated using the Ramsay sedation score. Other associated side effects, such as hypotension (systolic blood pressure <20% of baseline), nausea, vomiting, bradycardia (HR <50/min), and hypoxemia, were observed. HR, continuous ECG, peripheral oxygen saturation (SPO<sub>2</sub>), and NIBP were also monitored.

### Statistical analysis

Analysis was done using Statistical software SPSS version 16. All continuous variables were expressed as mean and standard deviation. All categorical variables were expressed as percentages and proportions. The test was considered significant if  $P < 0.05$ , at a 95% confidence interval.

## RESULTS

The mean age in the dexamethasone group is 40.9 years (SD=11.5), and in the Dexmedetomidine group is

40.5 years (SD=10.2). Both groups are comparable in terms of age.

In the dexmedetomidine group, there were 22 females and 18 males. There were 21 females and 19 males in the dexamethasone group, and both groups are comparable in gender.

In the dexmedetomidine group, there were 25 patients in ASA I and 15 in ASA II. In the dexamethasone group, there were 26 patients in ASA I and 14 in ASA II. Both groups are comparable in terms of ASA.

The mean body mass index (BMI) in the dexamethasone group is 26 (SD=3.5), and in the dexmedetomidine group is 26.9 (SD=4.3). Both groups are comparable in terms of BMI (Table 1).

The mean duration of surgery in the dexmedetomidine group is 137 min (SD=23.1), and in the dexamethasone group is 138 min (SD=18.9). Both groups are comparable in terms of duration of surgery.

The mean duration of onset of sensory anesthesia in the dexmedetomidine group is 3.9 min (SD=0.7 min), and in the dexamethasone group is 7.8 min (SD=0.4 min). The onset of sensory anesthesia was faster in dexmedetomidine than in dexamethasone, which is statistically significant ( $P < 0.001$ ).

The mean duration of sensory anesthesia in the dexmedetomidine group is 832.3 min (SD=58.9 min), and in the dexamethasone group is 659.2 min (SD=53.7 min). The sensory anesthesia duration was higher in dexmedetomidine than in dexamethasone, which is statistically significant ( $P < 0.001$ ).

The mean duration of onset of motor anesthesia in the dexmedetomidine group is 5.9 min (SD=0.7 min), and in the dexamethasone group is 9.8 min (SD=0.5 min). The onset of motor anesthesia was faster in dexmedetomidine than in dexamethasone, which is statistically significant ( $P < 0.001$ ).

**Table 1: Demographic data**

| Variables | Drug           |                 |
|-----------|----------------|-----------------|
|           | Dexamethasone  | Dexmedetomidine |
| Sex       |                |                 |
| Female    | 21             | 22              |
| Male      | 19             | 18              |
| Age       | 40.925±11.5167 | 40.55±10.2105   |
| ASA       |                |                 |
| I         | 26             | 25              |
| II        | 14             | 15              |
| BMI       | 26±3.5301      | 26.9±4.3252     |

BMI: Body mass index, ASA: American Society of Anesthesiologists

The mean duration of motor anesthesia in the dexmedetomidine group is 720 min (SD=59 min), and in the dexamethasone group is 567 min (SD=58.1 min). The duration of motor anesthesia was higher in dexmedetomidine than in dexamethasone, which is statistically significant ( $P<0.001$ ).

The mean duration of analgesia in the dexmedetomidine group is 892.3 min (SD=59 min), and in the dexamethasone group is 718 min (SD=53.8 min). The duration of analgesia was higher in dexmedetomidine than in dexamethasone, which is statistically significant ( $P<0.001$ ).

The mean duration for rescue analgesia in the dexmedetomidine group is 906 min (SD=58 min), and in the dexamethasone group is 727 min (SD=38.2 min). The duration for rescue analgesia was higher in dexmedetomidine than in dexamethasone, which is statistically significant ( $P<0.001$ ) (Table 2).

Visual analog scores at 6<sup>th</sup> h and 18<sup>th</sup> h did not show any difference. Visual analog scores at 10, 14, and 24<sup>th</sup> h were lower in the dexmedetomidine group than in the dexamethasone group, which is statistically significant ( $P<0.001$ ) (Figure 1).

Vital parameters at 15, 30, 60, 120, 180, 240, and 300 min were comparable between the two groups with a  $P>0.05$  (Table 3).

None of the patients in the dexamethasone group had any side effects. In contrast, five patients in the dexmedetomidine group had bradycardia, which is statistically significant ( $P<0.05$ ). The sedation score was one in all patients in the dexamethasone group, whereas it was two in all patients in the dexmedetomidine group (Table 4).

## DISCUSSION

The supraclavicular brachial plexus block is one of the peripheral nerve blockades used for upper limb surgery. Compared to general anesthesia, it has many benefits,

such as efficient analgesia and strong motor blockade, awake patients, prolonged post-operative analgesia, early mobilization, no direct airway stimulation, and avoidance of polypharmacy. Ultrasonography guidance was selected for our study due to its multiple benefits, including the precise visualization of anatomical variations of the brachial plexus, identification of pleura to mitigate pneumothorax risk, reduction in block procedure duration, decreased likelihood of accidental vascular puncture, minimized use of local anesthetic dosage, and improvement in the quality of the block.

Some studies aim to improve the outcome of a supraclavicular brachial plexus block by adding adjuncts such as opioids, alpha 2 adrenergic agonists, dexmedetomidine, dexamethasone, adrenaline, and soda bicarbonate to the local anesthetics. Peripheral nerve block analgesia is augmented by using dexamethasone with perineural local anesthesia. Alarasan et al.,<sup>7</sup> conclude that dexamethasone increases the duration of analgesia in patients receiving low-volume supraclavicular brachial plexus block. In their study, Pani et al.,<sup>8</sup> added dexamethasone to levobupivacaine, prolonging the time for first rescue analgesia and reducing the requirement for further rescue analgesia.

Alpha 2-adrenergic agonist dexmedetomidine provides better pain management and anesthesia when mixed with local anesthetics. Ping et al.,<sup>9</sup> confirm in their study that adding dexmedetomidine to local anesthetics improves the block quality by prolonging the duration of sensory and motor block and the duration of analgesia. Marhofer et al.,<sup>13</sup> also confirm dexmedetomidine as an adjuvant to local anesthetics. These adjuncts tend to improve the quality of the block given by ropivacaine. Ropivacaine, a 0.5% regional anesthetic, is less lipophilic than bupivacaine and is more selective toward alpha-2 adrenoceptor agonists. It is used for regional nerve blocks due to its higher cardiovascular and central nervous threshold. Ropivacaine is also used in chronic pain management. It is effective in peripheral nerve blocks but less potent in epidural or intravenous routes. Clinically adequate doses are associated with lower motor block grades.

**Table 2: Duration of surgery, sensory, motor, and analgesia between groups**

| Variables                    | Drug              |                   | P-value |
|------------------------------|-------------------|-------------------|---------|
|                              | Dexmedetomidine   | Dexamethasone     |         |
| Duration of surgery (in min) | 137.375 (23.1092) | 138.125 (18.8954) | <0.5    |
| Onset of sensory (in min)    | 3.9 (0.6718)      | 7.8 (0.4641)      | <0.001  |
| Duration of sensory          | 832.375 (58.9653) | 659.25 (53.7987)  | <0.001  |
| Onset of motor               | 5.9 (0.6718)      | 9.85 (0.5335)     | <0.001  |
| Duration of motor            | 720.25 (59.1928)  | 567 (58.087)      | <0.001  |
| Duration of analgesia        | 892.375 (58.9653) | 718 (53.885)      | <0.001  |
| Rescue analgesia             | 906.125 (58.3588) | 727.25 (38.2125)  | <0.001  |



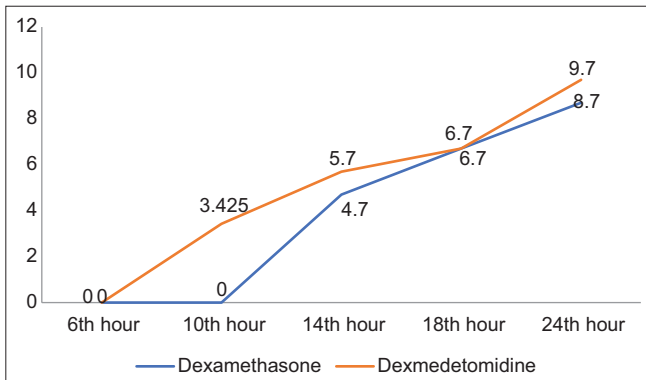


Figure 1: Visual analog scale score between groups

| Vitals           | Drug          |                 | P-value |
|------------------|---------------|-----------------|---------|
|                  | Dexamethasone | Dexmedetomidine |         |
| Pulse            | 87.575±7.2356 | 80.15±6.1375    | >0.05   |
| Systolic BP      | 117.55±6.2263 | 115±5.6205      | >0.05   |
| Diastolic BP     | 71.125±5.4452 | 68.9±7.7783     | >0.05   |
| SPO <sub>2</sub> | 99.1±0.6325   | 98.925±0.6558   | >0.05   |

BP: Blood pressure

| Variables      | Drug          |                 |
|----------------|---------------|-----------------|
|                | Dexamethasone | Dexmedetomidine |
| Side effect    |               |                 |
| Bradycardia    | 0             | 5               |
| Nil            | 40            | 35              |
| Sedation score |               |                 |
| 1              | 40            | 0               |
| 2              | 0             | 40              |

Ropivacaine is an important option for regional anesthesia, post-operative pain management, and labor analgesia due to its efficacy, lower motor block propensity, and reduced central nervous system and cardiotoxicity risks. Lee et al.<sup>14</sup> compare the efficacy of dexmedetomidine with dexamethasone as an adjuvant to local anesthetics but state there was no statistical significance between those two groups, which contradicts our study. Kaur et al.<sup>15</sup> compare 50 mcg of dexmedetomidine and 8 mg of dexamethasone as an adjuvant to local anesthetics, similar to our dose study. The result of this study also correlates with our study as it concludes that the dexmedetomidine group has a faster onset and longer sensory and motor block duration. Gao et al.<sup>16</sup> also show that dexmedetomidine has prolonged the duration of local anesthetics compared to dexamethasone.

### Limitations of the study

This study is marked by several limitations, notably its limited sample size, single-center approach, abbreviated follow-up period, absence of blinding, and specific criteria

for participant inclusion and exclusion. Furthermore, the observed side effects such as bradycardia and sedation in the Dexmedetomidine group require in-depth examination. The chosen dosages may not be representative of prevailing clinical norms, and it is crucial to openly acknowledge the potential presence of publication bias. Moving forward, future research should prioritize efforts to mitigate these limitations for a more comprehensive and robust investigation.

## CONCLUSION

The dexmedetomidine group has a faster onset of sensory and motor blockade, longer duration of sensory and motor blockade, a prolonged period of analgesia, and prolonged duration for rescue analgesia than the dexamethasone group for ultrasound-guided supraclavicular brachial plexus block. Bradycardia and sedation were side effects noted in the dexmedetomidine group, which were not observed in the dexamethasone group.

## ACKNOWLEDGMENT

We want to express our sincere gratitude to the patients who participated in this study. Their contribution was invaluable in generating the data and insights presented in this research paper. We also extend our appreciation to the head of the department, as well as the medical staff, for their support and dedication throughout the study.

## REFERENCES

- Boezaart AP, Davis G and Le-Wendling L. Recovery after orthopedic surgery: Techniques to increase duration of pain control. *Curr Opin Anaesthesiol.* 2012;25(6):665-672. <https://doi.org/10.1097/ACO.0b013e328359ab5a>
- Hobson-Webb LD, Padua L and Martinoli C. Ultrasonography in the diagnosis of peripheral nerve disease. *Expert Opin Med Diagn.* 2012;6(5):457-471. <https://doi.org/10.1517/17530059.2012.692904>
- Bruce BG, Green A, Blaine TA and Wesner LV. Brachial plexus blocks for upper extremity orthopaedic surgery. *J Am Acad Orthop Surg.* 2012;20(1):38-47. <https://doi.org/10.5435/JAAOS-20-01-038>
- Chan VW, Perlas A, Rawson R and Odukoya O. Ultrasound-guided supraclavicular brachial plexus block. *Anaesth Analg.* 2003;97(5):1514-1517. <https://doi.org/10.1213/01.ANE.0000062519.61520.14>
- Choi S and McCartney CJ. Evidence base for the use of ultrasound for upper extremity blocks: 2014 Update. *Reg Anesth Pain Med.* 2016;41(2):242-250. <https://doi.org/10.1097/AAP.0000000000000155>
- Singelyn FJ. Clinical application of ropivacaine for the upper extremity. *Curr Top Med Chem.* 2001;1(3):219-225. <https://doi.org/10.2174/1568026013395326>

7. Alarasan AK, Agrawal J, Choudhary B, Melhotra A, Uike S and Mukherji A. Effect of dexamethasone in low volume supraclavicular brachial plexus block: A double-blinded randomized clinical study. *J Anaesthesiol Clin Pharmacol.* 2016;32(2):234-239.  
<https://doi.org/10.4103/0970-9185.182108>
8. Pani N, Routray SS, Mishra D, Pradhan BK, Mohapatra BP and Swain D. A clinical comparison between 0.5% levobupivacaine and 0.5% levobupivacaine with dexamethasone 8 mg combination in brachial plexus block by the supraclavicular approach. *Indian J Anaesth.* 2017;61(4):302-307.  
[https://doi.org/10.4103/ija.IJA\\_509\\_16](https://doi.org/10.4103/ija.IJA_509_16)
9. Ping Y, Ye Q, Wang W, Ye P and You Z. Dexmedetomidine as an adjuvant to local anaesthetics in brachial plexus blocks: A meta-analysis of randomized controlled trials. *Medicine (Baltimore).* 2017;96(4):e5846.  
<https://doi.org/10.1097/MD.0000000000005846>
10. Kirkham KR, Guillarmod AJ and Albrecht E. Optimal dose of perineural dexamethasone to prolong analgesia after brachial plexus blockade: A systematic review and meta-analysis. *Anesth Analg.* 2018;126(1):270-279.  
<https://doi.org/10.1213/ANE.0000000000002488>
11. Chaithanya K and Reddy N. A comparative study between 0.375% ropivacaine with 50 mcg of dexmedetomidine and 0.375% ropivacaine with 8 mg of dexamethasone for ultrasound-guided supraclavicular brachial plexus block. *Indian J Clin Anaesth.* 2017;4(1):69-73.
12. Verma NK and Ranjan A. A clinical comparison of dexmedetomidine and dexamethasone as an adjuvant to ropivacaine in supraclavicular brachial plexus blocks for upper arm surgeries. *Int J Adv Res Biol Sci.* 2016;3(7):56-61.
13. Marhofer D, Kettner SC, Marhofer P, Pils S, Weber M and Zeitlinger M. Dexmedetomidine as an adjuvant to ropivacaine prolongs peripheral nerve block: A volunteer study. *Br J Anaesth.* 2013;110(3):438-442.  
<https://doi.org/10.1093/bja/aes400>
14. Lee MJ, Koo DJ, Choi YS, Lee KC and Kim HY. Dexamethasone or dexmedetomidine as local anesthetic adjuvants for ultrasound-guided axillary brachial plexus blocks with nerve stimulation. *Korean J Pain.* 2016;29(1):29-33.  
<https://doi.org/10.3344/kjp.2016.29.1.29>
15. Kaur M, Lakhani A and Hashia AM. Comparative study between dexamethasone and dexmedetomidine in a supraclavicular block. *Int J Adv Med.* 2018;5(1):57-61.  
<https://doi.org/10.18203/2349-3933.ijam20175878>
16. Gao Z, Xiao Y, Wang Q and Li Y. Comparison of dexmedetomidine and dexamethasone as an adjuvant for ropivacaine in ultrasound-guided erector spinae plane block for video-assisted thoracoscopic lobectomy surgery: A randomized, double-blind, placebo-controlled trial. *Ann Transl Med.* 2019;7(22):668.  
<https://doi.org/10.21037/atm.2019.10.74>

**Author's contributions:**

**MKN**- Editing manuscript; **TR**- Review manuscript; **SM**- Protocol review, review manuscript; **NK**- Manuscript preparation, literature review, data collection, data analysis; and **BV**- Study design, review manuscript.

**Work Attributed to:**

Department of Anesthesiology, Stanley Medical College and Hospital, Chennai, Tamil Nadu, India.

**Orcid ID:**

Dr. Narasimhan MK - <https://orcid.org/0009-0000-9197-7340>  
 Dr. Renganathan T - <https://orcid.org/0009-0003-6192-4039>  
 Dr. Muralidaran S - <https://orcid.org/0009-0009-2745-1710>  
 Dr. Rajaram Jayaraman - <https://orcid.org/0009-0003-6762-3923>

**Source of Support:** Nil, **Conflicts of Interest:** None declared.