

Accessory cavitated uterine mass in a young female with chronic pelvic pain and dysmenorrhea



Deepti Naik

Professor, Department of Radio-diagnosis, MS Ramaiah Medical College, Bengaluru, Karnataka, India

Submission: 15-11-2023

Revision: 28-01-2024

Publication: 01-03-2024

ABSTRACT

Accessory and cavitated uterine mass is a rare form of developmental Mullerian anomaly seen in young females, which presents as chronic recurrent pelvic pain and severe dysmenorrhea. Hysterosalpingography (HSG), ultrasonography, and magnetic resonance imaging (MRI) are the mainstay of diagnostic imaging. This entity is often underdiagnosed; therefore, a high index of suspicion combined with HSG and MRI imaging can help in making an accurate and timely diagnosis and thus prevent unnecessary interventions.

Key words: Accessory; Mullerian duct anomalies; Accessory and cavitated uterine mass

Access this article online

Website:

<http://nepjol.info/index.php/AJMS>

DOI: 10.3126/ajms.v15i3.59927

E-ISSN: 2091-0576

P-ISSN: 2467-9100

Copyright (c) 2024 Asian Journal of Medical Sciences



This work is licensed under a Creative Commons Attribution-NonCommercial 4.0 International License.

INTRODUCTION

Accessory and cavitated uterine mass (ACUM) is a rare form of developmental Mullerian anomaly seen in young females, which presents as chronic recurrent pelvic pain and severe dysmenorrhea. It is an accessory cavity located within an otherwise normal uterus. It is lined by functional endometrium and is surrounded by myometrium-like smooth muscle cells; hence, it has striking macroscopic and microscopic resemblance to the uterus.

CASE REPORT

A 20-year-old nulliparous female was referred to a private diagnostic center in Mumbai for magnetic resonance imaging (MRI) of pelvis. She had a history of chronic recurrent pelvic pain and severe dysmenorrhea for the

past 5 years for which she has been visiting her family physician and gynecologist every 6 months. She had undergone ultrasonography (USG) few times in the past 5 years and she was diagnosed to have a left adnexal cystic lesion adjacent to the left ovary measuring 9×7×9 mm, suggestive of para-ovarian cyst or endometrioma. She underwent CT scan of abdomen and pelvis in December 2017 in a private diagnostic center in South Mumbai and was diagnosed to have a left adnexal para-ovarian cystic lesion measuring 13×11×13 mm. Her symptoms persisted and in spite of medical treatment, she continued to have chronic pelvic pain and dysmenorrhea. She was referred for USG and MRI in February 2020 to another private diagnostic center in Mumbai. USG of the pelvis revealed a left para-ovarian cystic lesion measuring 17×13×17 mm, which has increased in size as compared to previous sonographies and CT scan.

Address for Correspondence:

Dr. Deepti Naik, Professor, Department of Radio-diagnosis, MS Ramaiah Medical College, Bengaluru, Karnataka, India.

Mobile: +91-9902044052. **E-mail:** drdeepti2004@hotmail.com

MRI of the pelvis was done in NM diagnostic center, marine lines which revealed a well-defined left adnexal lesion measuring 25×21×25 mm with central rounded cystic component measuring 18×14×18 mm surrounded by thick rind of soft tissue measuring 7 mm (Figures 1-3). The central cystic component was hyperintense in T1W, T2W, and T1 fat-saturated sequences consistent with blood degradation products. The lesion was thick walled with signal intensity of the wall of the cystic lesion similar to the uterine myometrium in all the sequences. The lesion was contiguous with the left lateral wall of uterus and was located inferior to the round ligament and medial to the left ovary. There was no communication of the lesion with the endometrial cavity. Bilateral uterine cornua were visualized separately. The uterine cavity, the junctional zone, the endo-myometrial interface, and the myometrium showed normal signal intensity. There was no evidence of any endometriotic deposits

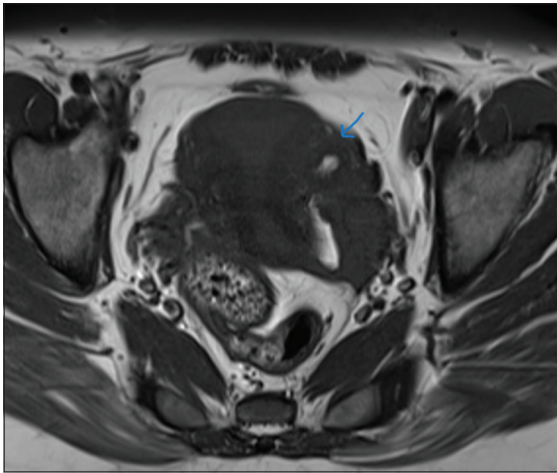


Figure 1: T1 axial contrast study shows a well-defined cystic lesion adjacent to left ovary and lateral to uterus, not communicating with uterine cavity

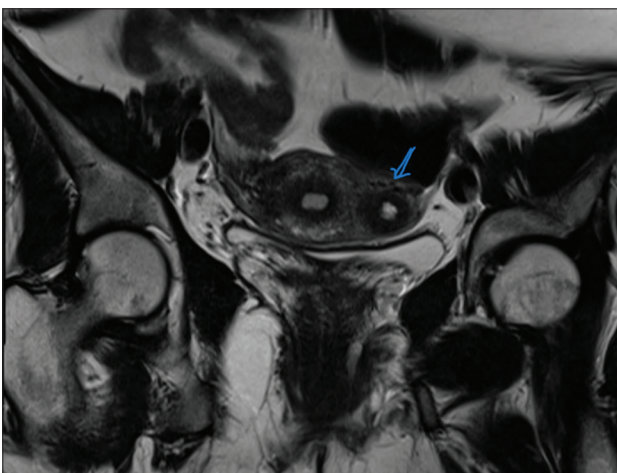


Figure 2: T2 coronal contrast study shows a well-defined cystic lesion adjacent to left ovary and lateral to uterus, not communicating with uterine cavity

or hydrosalpinx. Both ovaries were visualized separately and were normal in size, morphology, and signal intensity. There was no free fluid in the pelvis or pelvic lymphadenopathy. A diagnosis of ACUM was given. The patient underwent laparoscopic resection of the left para-ovarian lesion in March 2020 and a blood-filled cystic lesion measuring 18×14×15 mm was resected and sent for frozen section and histopathologic examination which confirmed the diagnosis of ACUM.

DISCUSSION

Uterus-like masses (ULMs) are rare lesions that resemble the uterus; both macroscopically uteruses develop from the embryonic fusion of the two Mullerian ducts. Seven classes of uterine anomalies are described in the literature including septate uterus, arcuate uterus, and unicornuate uterus as well as microscopically.¹ Such masses can occur within the uterus or any other sites and at any age. ACUMs are non-communicating ULMs that occur contiguously along the wall of the uterus. The uterine cavity in ACUMs is normal unlike other Mullerian anomalies and hence needs to be described more accurately. ACUM is considered to be a developmental anomaly by the majority of authors.² It is considered to develop due to a duplication of the Mullerian duct at the level of attachment of the round ligament. ACUMs generally present in women under 30 years. Repeated bleeding within the ACUM during the menstrual cycle causes distension of its cavity and chronic pelvic pain. ACUM may be larger in size when the woman is older. To characterize a lesion as an ACUM on imaging the following criteria need to be met:³

1. An accessory cavitated mass with orientation of the lesion around the round ligament.

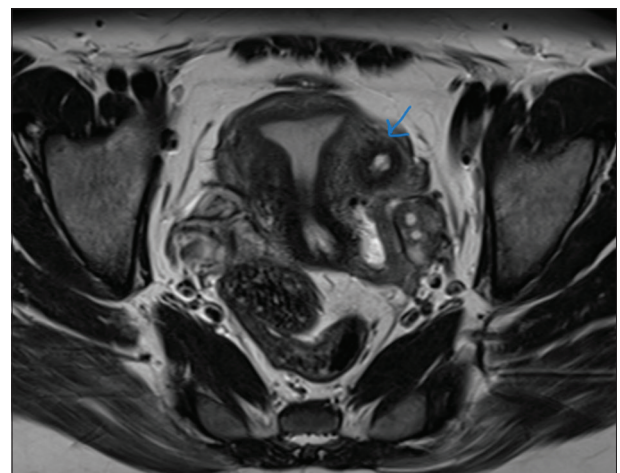


Figure 3: T2 axial contrast study shows a well-defined cystic lesion adjacent to left ovary and lateral to uterus, not communicating with uterine cavity

2. Normal uterus, endometrial cavity, fallopian tubes, and ovaries.
3. Cystic component within the lesion showing chocolate-colored content and signal intensity of blood degradation products.
4. No signs of adenomyosis in the uterus, however, tiny foci of adenomyosis may be seen in the myometrium of ACUM due to increase intracystic pressure.⁴
5. No pelvic endometriotic deposits.

ACUM may coexist with other Mullerian anomalies as reported in the literature and may further complicate the diagnosis.⁴ MRI remains the modality of choice as it clearly distinguishes a contiguous, non-communicating lesion with cystic component within ACUM as opposed to other Mullerian anomalies. The uterus, ovaries, and fallopian tubes are well demonstrated and so are the hemorrhagic or endometriotic foci. Other diagnostic modalities include transvaginal sonography, and hysterosalpingography (HSG). To our knowledge, most of the cases are often misdiagnosed as cystic degeneration in leiomyomas or adenomyomas or bicornuate uterus with obstructed rudimentary horn. Clinical suspicion of ACUM is based on the occurrence of symptoms, recurrence of symptoms, patient age, and knowledge and awareness of this entity, and thus, it will help to consider preoperative diagnosis of ACUM by the radiologist. Early diagnosis and early surgical intervention involving laparoscopic removal of the mass can shorten the usual prolonged suffering of these young women.⁵

On MRI, ACUM resembles a non-communicating functional accessory horn within a normal uterus; the mass, most often round-shaped, had a central hemorrhagic cavity surrounded by a regular ring which had the same signal intensity as the uterine myometrium. It is classically located inferior to the insertion of round ligament. ACUM may be intramyometrial and/or in the broad ligament.⁶

CONCLUSION

ACUM is a rare Mullerian anomaly. HSG, USG, and MRI are the mainstay of diagnostic imaging. This entity is often underdiagnosed; therefore, a high index of suspicion combined with HSG and MRI imaging can help in making an accurate and timely diagnosis and thus prevent unnecessary interventions and appropriate curative and fertility-sparing laparoscopic resection can be performed by the gynecologist.

ACKNOWLEDGMENT

NM diagnostic center, Marine lines, Mumbai.

REFERENCES

1. Putta T, John R, Simon B, Sathyakumar K, Chandramohan A and Eapen A. Imaging manifestations of accessory cavitated uterine mass-a rare mullerian anomaly. *Indian J Radiol Imaging*. 2021;31(3):545-550.
<https://doi.org/10.1055/s-0041-1735504>
2. Gupta S, Manchanda S, Vyas S, Malhotra N, Mathur SR and Kulshrestha V. Imaging features of accessory cavitated uterine mass (ACUM): A peculiar yet correctable cause of dysmenorrhea. *Abdom Radiol (NY)*. 2023;48(3):1100-1106.
<https://doi.org/10.1007/s00261-022-03790-0>
3. Dekkiche S, Dubruc E, Kanbar M, Feki A, Mueller M, Meuwly JY, et al. Accessory and cavitated uterine masses: A case series and review of the literature. *Front Reprod Health*. 2023;5:1197931.
<https://doi.org/10.3389/frph.2023.1197931>
4. Rackow BW. Accessory cavitated uterine mass: A new müllerian anomaly? *Fertil Steril*. 2022;117(3):649-650.
<https://doi.org/10.1016/j.fertnstert.2022.01.006>
5. Hu YL, Wang A and Chen J. Diagnosis and laparoscopic excision of accessory cavitated uterine mass in a young woman: A case report. *World J Clin Cases*. 2021;9(30):9122-9128.
<https://doi.org/10.12998/wjcc.v9.i30.9122>
6. Peyron N, Jacquemier E, Charlot M, Devouassoux M, Raudrant D, Golfier F, et al. Accessory cavitated uterine mass: MRI features and surgical correlations of a rare but under-recognised entity. *Eur Radiol*. 2019;29(3):1144-1152.
<https://doi.org/10.1007/s00330-018-5686-6>

Author Contribution:

DN- Concept and design, manuscript preparation and consultant radiologist.

Work attributed to:

MS Ramaiah Medical College, Bengaluru - 560 054, Karnataka, India. NM Diagnostic centre, Marine Lines, Mumbai.

Orcid ID:

Dr. Deepti Naik - <https://orcid.org/0000-0003-2389-5890>

Source of Support: Nil, Conflicts of Interest: None declared.