

# A comparative study between laser hemorrhoidoplasty with digital-guided hemorrhoidal artery ligation and conventional (Milligan-Morgan) hemorrhoidectomy



Rajkumar Verma<sup>1</sup>, Narendra Kumar<sup>2</sup>, Vipin Mishra<sup>3</sup>

<sup>1</sup>Professor, <sup>2,3</sup>Junior Resident, Department of Surgery, M.L.B. Medical College, Jhansi, Uttar Pradesh, India

Submission: 29-10-2023

Revision: 28-12-2023

Publication: 01-02-2024

## ABSTRACT

**Background:** Hemorrhoids have a much higher incidence than rectum and colon diseases worldwide. The prevalence was estimated to be between 2.9% and 27.9% among the worldwide population, of which 4% are symptomatic. Based on the Gauss method, the highest incidence was present in patients aged between 45 and 65 years. **Aims and Objectives:** To compare laser hemorrhoidoplasty with digital-guided hemorrhoidal artery ligation (DGHAL) and conventional (Milligan-Morgan) open hemorrhoidectomy procedures. **Materials and Methods:** A prospective follow-up study was undertaken in the Department of Surgery, Maharani Laxmi Bai Medical College, Jhansi, from January 2020 to June 2021. In this comparative and prospective study, 60 patients were included, of whom 30 were treated with open surgical hemorrhoidectomy (Milligan-Morgan) and 30 were treated with laser hemorrhoidoplasty with the DGHAL method. **Results:** Male patients numbered 41 and female patients numbered 19. Between laser hemorrhoidoplasty with DGHAL and the open surgical hemorrhoidectomy (Milligan-Morgan) approach, there were significant differences in operating time, blood loss, bleeding; and early postoperative pain. In terms of early postoperative pain, there were statistically significant differences between the two groups ( $P < 0.001$ ). The mean operational time for laser hemorrhoidoplasty with DGHAL was  $22.57 \pm 1.794$  min, compared to  $29.43 \pm 3.664$  min for the open surgical hemorrhoidectomy (Milligan-Morgan) method ( $P < 0.002$ ). **Conclusion:** Laser hemorrhoidoplasty with Doppler-guided hemorrhoidal artery ligation (DGHAL) is safe and effective in cases of all grades of hemorrhoids as compared to open surgical (Milligan-Morgan) hemorrhoidectomy.

**Key words:** Hemorrhoids; Laser hemorrhoidoplasty; Open hemorrhoidectomy; Post-operative pain

## INTRODUCTION

Hemorrhoids are a very common anorectal condition, defined as the symptomatic enlargement and distal displacement of the normal anal cushions.<sup>1,2</sup> Characteristically lie in the 3, 7, and 11 o'clock positions (with the patient in the lithotomy position).<sup>3</sup> They affect millions of people around the world. Predictable prevalence ranges from 2.9% to 27.9%, of which >4% are patients who are symptomatic. Males are more frequently affected than females. Symptoms vary from painless bleeding

to embarrassing painful prolapse mass, itching, and thrombosis. Hemorrhoids represent a major medical and socioeconomic problem. Peak incidence occurs between 45 and 65 years of age, with a subsequent decline after 65 years of age. The development of hemorrhoids before age 18 was unusual. Whites were affected more frequently than blacks, and increased prevalence rates were associated with higher socioeconomic status.<sup>4</sup>

There are many treatment modalities available, such as stapled hemorrhoidopexy, sclerotherapy, Doppler-

### Access this article online

#### Website:

<http://nepjol.info/index.php/AJMS>

DOI: 10.3126/ajms.v15i2.59505

E-ISSN: 2091-0576

P-ISSN: 2467-9100

Copyright (c) 2024 Asian Journal of Medical Sciences



This work is licensed under a Creative Commons Attribution-NonCommercial 4.0 International License.

### Address for Correspondence:

Dr. Narendra Kumar, Junior Resident, Department of Surgery, M.L.B. Medical College, Jhansi - 284 128, Uttar Pradesh, India.

Mobile: +91-6386424114. E-mail: narendra15101991@gmail.com

guided artery ligation, hemorrhoidal dearterialization, and finally surgical excision (Milligan-Morgan's and Ferguson's techniques). However, no single treatment method has been considered the best treatment. Milligan Morgan's hemorrhoidectomy is the gold standard and a frequently performed open surgical procedure. Post-hemorrhoidectomy pain and bleeding are the most common problems associated with surgical techniques.

The laser was primarily recognized by Maymen in 1960 upon the construction of the ruby laser.<sup>5</sup> Lasers were first used in medicine and ophthalmology. In 2009, Salfi<sup>6</sup> described the laser hemorrhoidectomy. Today, laser treatment is not uncommon in the treatment of hemorrhoids. During treatment, the arterial blood flow of hemorrhoids is halted using Doppler laser coagulation.

### Aims and objectives

To compare laser hemorrhoidoplasty with digital-guided hemorrhoidal artery ligation (DGHAL) and conventional (Milligan-Morgan) open hemorrhoidectomy procedures.

## MATERIALS AND METHODS

A prospective follow-up study was undertaken in the Department of Surgery, Maharani Laxmi Bai Medical College, Jhansi, from January 2020 to June 2021. In this comparative and prospective study, 60 patients were included, of whom 30 were treated with open surgical hemorrhoidectomy (Milligan-Morgan) and 30 were treated with laser hemorrhoidoplasty with the DGHAL method. Ethical clearance from the institute ethics committee was taken, procedures were explained in detail, and informed consent was taken.

### Inclusion criteria

- Age >18.
- Hemorrhoid grade 3 and 4.
- Accepting participation.

### Exclusion criteria

- Age <18 years.
- Pregnancy.
- Any previous anal surgery.
- With any other anal pathology like fissure, anal stenosis, rectal prolapse, etc.
- With anticoagulant treatment.
- Intestinal chronic inflammatory disease.

### Methodology

#### Group A (open surgical [Milligan-Morgan] Hemorrhoidectomy)

First, expose the field with a proctoscope, and then make an elliptical incision (v-shape incision) after fixation of the hemorrhoid by Kocher's hemostatic forceps. Second,

cutting the skin and the mucuous membrane at the mucocutaneous junction pushes the internal sphincter laterally, until reaching the pedicle of the hemorrhoid, which is then ligated or transfixed with a vicryl 2.0 ligature. At the end, excise the hemorrhoid distal to the ligature. Repeat the procedure for all hemorrhoids and leave it open until anal packing is done.

#### Group B (laser hemorrhoidoplasty with DGHAL)

In this study, we use Laser MAR 1500 (Eufoton) as a type of diode laser, which is composed of an ARC laser generator device and 600 µm hemofiber (Figure 1).

All cases underwent anorectal examination for any other anorectal disease, such as cancer, fistula, rectal prolapse, fissures, etc. Before laser shooting, we must wear anti-laser glasses. A diode 8-W laser with a 1470-nm wavelength was used for this procedure, with a maximum of 200 jules in one pile. Before the diode laser, we hold piles and digitally guide superior hemorrhoidal artery ligation 2 cm above the dentate line with the help of a vicryl 2.0 suture, as shown in figure of eight fashion. Eight pulses at a power of 8 W, each lasting for 1.2 s with a 0.6 s pause between pulses, were delivered to the tissue. After diode laser application, we apply an icepack. The laser beam induced a degeneration of mucosal and submucosal tissues, causing shrinkage of the underlying tissue and its arterial branch to a depth of ~5 mm. This can be repeated for all hemorrhoids at any other site (Figures 2 and 3).

### Statistical analysis

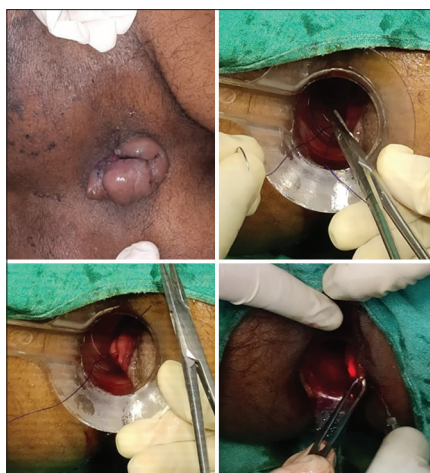
The data were collected and entered in a Microsoft Excel sheet, and later, the excel sheet was transported to SPSS 21.0 and an appropriate statistical test, Chi-square and unpaired t-tests are applied.



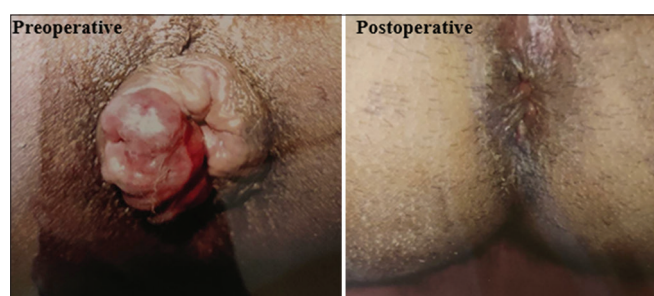**Figure 1:** Laser MAR 1500 (Eufoton) components as a type of diode laser of 1470 nm with Eufoton 600 µm hemofiber

## RESULTS

In our study, the majority of patients are between the ages of 30 and 45 (Table 1), which indicates that, the incidence



**Figure 2:** Steps of laser haemorrhoidoplasty with digital guided haemorrhoidal artery ligation



**Figure 3:** Patient before and after laser treatment

Table 1: Age distribution				
Age (in years)	Group A (open surgical [Milligan-Morgan] hemorrhoidectomy)		Group B (laser hemorrhoidoplasty with DGHAL)	
	N	%	N	%
18–30 years	3	10.00	5	16.67
31–40 years	9	30.00	13	43.33
41–50 years	9	30.00	5	16.67
51–60 years	4	13.33	6	20.00
>60 years	5	16.67	1	3.33
Total	30	100	30	100

DGHAL: Digital-guided hemorrhoidal artery ligation

Table 2: Sex distribution				
Sex	Group A (open surgical [Milligan Morgan] Hemorrhoidectomy)		Group B (Laser Hemorrhoidoplasty with DGHAL)	
	Number of patients	Percentage	Number of patients	Percentage
Male	17	56.67	24	80.00
Female	13	43.33	6	24.00
Total	30	100	30	100

DGHAL: Digital-guided hemorrhoidal artery ligation

of hemorrhoid is increasing even in young patients because of their sedentary lifestyle and lack of a fiber diet.

In Group A, there are 17 males and 13 females; in Group B, 24 male and 6 female patients. In our study, males are more affected than females (Table 2).

## DISCUSSION

This is a comparative and prospective study of two groups of patients. Group A includes 30 patients who underwent open surgical (Milligan Morgan) hemorrhoidectomy, and Group B includes 30 patients who underwent laser hemorrhoidoplasty. DGHAL patients were selected randomly in both groups, and the period of observation and follow-up was from post-operative day to 6 months (patients included in this group were between January 2020 and June 2021).

### Mean operative time

Mean operative time 20–40 min ( $29.43 \pm 3.664$ ) in Group A patients and Group B having mean operative time of 20–30 min ( $22.57 \pm 1.794$ ) (Table 3). Hence, in Group B, patients had less intraoperative time as compared to Group A, which was comparable with Maluku et al.<sup>7</sup>

### Mean blood loss (intraoperative period)

During the intraoperative period, Group A had a mean blood loss of  $41 \pm 4.235$  (ml) and Group B had  $12.33 \pm 2.090$  (ml) with a P value of 0.005 (Table 3). Blood loss was estimated with the soakage of gauze. In Group A, open hemorrhoidectomy had more blood loss than in Group B, laser hemorrhoidoplasty, which was comparable to the study by Alsisy et al.<sup>8</sup>

### Mean hospital stay

Mean hospital stay 2–3 days ( $2.33 \pm 0.479$ ) in Group A and Group B mean hospital stay 1–2 days ( $1.13 \pm 0.346$ ) (Table 3), which is comparable with the study Alsisy et al.<sup>8</sup> Laser hemorrhoidoplasty in Group B patients significantly reduced duration of hospital stay as compared to Group A.

### Complication

In Group A, the persistence of pain was reported in 6 (20%) patients, and 4 (13.33%) patients had bleeding, 2 (6.67%)

**Table 3: Different parameter mean in the study group**

Parameters	Group A (open surgical [Milligan-Morgan] Hemorrhoidectomy)	Group B (Laser Hemorrhoidoplasty with DGHAL)	p value
Mean operative time (in min)	29.43±3.664	22.57±1.794	0.002 (S)
Mean blood loss (in ml)	41.00±4.235	12.33±2.090	0.005 (S)
Mean pain (visual analogue scale)	5.07±1.946	2.57±1.977	0.001 (S)
Mean hospital stay (in days)	2.33±0.479	1.13±0.346	0.001 (S)
Mean duration of return work (in days)	15.70±2.879	8.13±1.074	0.001 (S)

DGHAL: Digital-guided hemorrhoidal artery ligation

**Table 4: Complications**

Anaesthesia	Group A (open surgical [Milligan Morgan] Hemorrhoidectomy)		Group B (laser hemorrhoidoplasty with DGHAL)	
	Number of patients	Percentage	Number of patients	Percentage
Pain	6	20.00	3	10.00
Bleeding	4	13.33	1	3.33
Infection	2	6.67	1	3.33
Fistula in ANO	1	3.33	0	0.00
Anal stenosis	2	6.67	0	0.00
Fecal incontinence	1	3.33	0	0.00
Recurrence	2	6.67	1	3.33

DGHAL: Digital-guided hemorrhoidal artery ligation

patients had an infection, of which 1 (3.33%) patient presented as a fistula in Ano. 2 (6.67%) patients presented with anal stenosis, 1 (3.33%) patient had fecal incontinence, and 2 (6.67%) patients presented with a recurrence of hemorrhoids. In Group B, only 3 (10%) patients presented with persistent pain, 1 (3.33%) patient had bleeding, 1 (3.33%) patient had an infection that was treated with proper antibiotic coverage, and 1 (3.33%) patient presented with a recurrence of hemorrhoids (Table 4).

In our study, Group B patients with laser treatment had very less postoperative complications as compared to Group A, which is comparable with Hassan and El-Shemy.<sup>9</sup>

#### Duration of return work

In Group A, the mean time return to work was 15.7±2.879 days less than in group B, 8.13±1.074, P=0.001 (S), which is comparable with Milligan et al.<sup>10</sup>

#### Limitation of the study

Sample size small and single center study.

### CONCLUSION

- Laser hemorrhoidoplasty with Doppler-guided hemorrhoidal artery ligation (DGHAL) is safe and effective in cases of all grades of hemorrhoids as compared to open surgical (Milligan-Morgan) hemorrhoidectomy.
- Laser hemorrhoidoplasty with the DGHAL procedure significantly reduced intraoperative bleeding and

postoperative pain as compared to open Milligan-Morgan hemorrhoidectomy.

- Laser hemorrhoidoplasty with the DGHAL procedure significantly reduced the duration of hospital stay compared to open Milligan-Morgan hemorrhoidectomy.

### ACKNOWLEDGMENT

The author would like to thank the Department of General Surgery, Maharani Laxmi Bai Medical College, Jhansi, Uttar Pradesh - 284 128.

### REFERENCES

1. Lohsiriwat V. Approach to hemorrhoids. *Curr Gastroenterol Rep.* 2013;15(7):332. <https://doi.org/10.1007/s11894-013-0332-6>
2. Lohsiriwat V. Hemorrhoids: From basic pathophysiology to clinical management. *World J Gastroenterol.* 2012;18(17):2009-2017. <https://doi.org/10.3748%2Fwjg.v18.i17.2009>
3. Brisinda G. How to treat haemorrhoids. Prevention is best; haemorrhoidectomy needs skilled operators. *BMJ.* 2000;321(7261):582-583. <https://doi.org/10.1136/bmj.321.7261.582>
4. Gazet JC, Redding W and Rickett JW. The prevalence of haemorrhoids. A preliminary survey. *Proc R Soc Med.* 1970;63(Suppl 1):78-80.
5. Patel A. Anesthesia for laser airway surgery. In: Hagberg CA, editor. *Benumof and Hagberg's Airway Management.* 3<sup>rd</sup> ed., Ch. 40. Philadelphia, PA: W.B. Saunders; 2013. p. 824-858.

- e4. Available from: <https://clinicalgate.com/anesthesia-for-laser-airway-surgery> [Last accessed on 2015 Feb 27].
6. Salfi R. A new technique for ambulatory hemorrhoidal treatment. *Coloproctol.* 2009;31:99-103.  
<https://doi.org/10.1007/s00053-009-0009-7>
7. Maloku H, Lazović R and Terziqi H. Laser hemorrhoidoplasty versus Milligan-Morgan hemorrhoidectomy-short term outcome. *Vojnosanit Pregl.* 2017;76:70.  
<https://doi.org/10.2298/vsp170125070m>
8. Alsisy AA, Alkhateep YM and El Salem I. Comparative study between intrahemorrhoidal diode laser treatment and Milligan-Morgan hemorrhoidectomy. *Menoufia Med J.* 2019;32(2): 560-565.  
[https://doi.org/10.4103/mmj.mmj\\_101\\_18](https://doi.org/10.4103/mmj.mmj_101_18)
9. Hassan A and El-Shemy GG. Laser hemorrhoidoplasty versus open hemorrhoidectomy in Upper Egypt. *Al-Azhar Int Med J.* 2021;2(2):84-89.  
<https://doi.org/10.21608/aimj.2021.57763.1397>
10. Milligan ET, Morgan CN and Jones LE, Officer R. Surgical anatomy of the anal canal and the operative treatment of hemorrhoids. *Lancet.* 1937;2:1119-1124.  
[https://doi.org/10.1016/S0140-6736\(00\)88465-2](https://doi.org/10.1016/S0140-6736(00)88465-2)

**Authors Contribution:**

**RV, NK, VM-** Concept and design of the study, prepared first draft of manuscript; Interpreted the results; reviewed the literature and manuscript preparation; Concept, coordination, preparation of manuscript and revision of the manuscript.

**Work attributed to:**

M.L.B. Medical College, Jhansi, Uttar Pradesh, India.

**Orcid ID:**

Rajkumar Verma - <https://orcid.org/0009-0002-4645-4529>

Narendra Kumar - <https://orcid.org/0009-0005-3190-6109>

Vipin Mishra - <https://orcid.org/0009-0000-2122-1505>

**Source of Support:** Nil, **Conflicts of Interest:** None declared.