

# A retrospective analysis of post-treatment complications in patients with carcinoma vulva undergoing surgery as a primary treatment modality



Balamurugan G<sup>1</sup>, Senthil Kumar N<sup>2</sup>, Ramkumar P<sup>3</sup>, Selvaraj N<sup>4</sup>

<sup>1</sup>Professor, <sup>2</sup>Assistant Professor, <sup>3</sup>Resident, <sup>4</sup>Associate Professor, Department of Surgical Oncology, Regional Cancer Centre, Government Coimbatore Medical College and Hospital, Coimbatore, Tamil Nadu, India

Submission: 08-09-2023

Revision: 29-11-2023

Publication: 01-01-2024

## ABSTRACT

**Background:** Vulvar carcinoma accounts for 5% of all malignant neoplasms in the female genital tract, with a higher incidence in developing countries and increased risk associated with human papillomavirus (HPV) infection. **Aims and Objectives:** The study aimed to retrospectively evaluate treatment complications in patients with carcinoma vulva who had undergone primary surgery alone or as part of multimodality therapy. It also aimed to evaluate HPV marker positivity in this group of patients and its relation to disease profile and prognosis. **Materials and Methods:** This is a retrospective study wherein data from the Regional Cancer Centre, Coimbatore, from 2017 to 2023, about 42 patients who underwent primary surgery for carcinoma vulva were analyzed. Patient information, including age, symptoms, imaging, biopsy, staging, and treatment options, were retrieved for analysis. **Results:** Regarding post-operative complications, ten patients developed seroma (23%), 9 had limb edema (21%), five patients had wound dehiscence (11%), and nine patients had post-radiotherapy/chemotherapy complications (21%). The mortality rate among patients in the study was 9% (4 patients). All four died because of nodal relapse. Six patients (14%) had disease recurrence in this study group, among whom 5 were HPV-negative (83%). Two patients had a recurrence in the primary site, and four had a nodal recurrence. HPV marker p16 was positive in 18 patients (43%) overall, and they were found to belong to the younger age group and had good treatment outcomes. **Conclusion:** Primary surgery for carcinoma vulva patients in our study is associated with limited but manageable complications amenable to rectification. HPV-associated carcinoma vulva is increasing in prevalence (43% in younger age group) with a positive prognosis.

**Key words:** Vulva; Human papillomavirus; Carcinoma; Surgery; Complications; Post-treatment; p16

## INTRODUCTION

Vulvar squamous cell carcinoma (VSCC) is the most common subtype of vulvar carcinoma in post-menopausal women. The mean age at diagnosis has decreased recently due to increased human papillomavirus (HPV)-related vulvar cancer. Primary vulvar malignancy is an infrequent gynecological neoplasm, accounting for 5–8% of cases.<sup>1</sup> It ranks as the fourth most prevalent gynecological

malignancy, predominantly afflicting post-menopausal women at a median age of 68.<sup>2,3</sup> The American Cancer Society projects that approximately 6,330 vulvar cancer cases will be diagnosed in 2022, with an estimated 1560 deaths attributed to vulvar cancer. Squamous cell carcinoma (SCC) encompasses over 90% of vulvar cancer incidences, followed by melanoma, adenocarcinoma, basal cell carcinoma, sarcoma, and undifferentiated variants.<sup>4</sup> VSCC associated with HPV is most commonly observed

### Access this article online

**Website:**

<http://nepjol.info/index.php/AJMS>

**DOI:** 10.3126/ajms.v15i1.58448

**E-ISSN:** 2091-0576

**P-ISSN:** 2467-9100

Copyright (c) 2024 Asian Journal of Medical Sciences



This work is licensed under a Creative Commons Attribution-NonCommercial 4.0 International License.

### Address for Correspondence:

Dr. Selvaraj N, Associate Professor, Department of Surgical Oncology, Regional Cancer Centre, Government Coimbatore Medical College and Hospital, Coimbatore, Tamil Nadu, India. **Mobile:** +91 87545 70002. **E-mail:** drsels@yahoo.com

in younger patients. It is postulated to arise from high-grade squamous intraepithelial lesions (HSIL) and exhibits a histological profile characterized by basaloid/warty morphology, which is non-keratinizing in nature.<sup>5</sup>

Vulvar intraepithelial neoplasia (VIN) is divided into two categories: HPV-dependent usual type and HPV-independent differentiated type. The first type is associated with high-risk HPV infection and occurs in women around 30–40 years of age. HPV prevalence is usually higher in vulvar high-grade lesions than in invasive vulvar cancer, with up to 80% of high-grade lesions harboring HPV. In contrast, only 20–80% of vulvar invasive lesions have HPV. Differentiated type is associated with chronic dermatoses, including lichen sclerosus et atrophicus and lichen planus. Invasive cancer that rises from the second type lacks detectable HPV sequences and usually occurs in older women (ages 55–85 years).<sup>6</sup>

The low-grade squamous intraepithelial lesion is associated with low-risk HPV subtypes such as type 6 and 11. In contrast, high-risk HPV subtypes 16, 18, and 33 are associated with HSIL. More than 90% of invasive vulvar cancers are VSCC. There are two subtypes: differentiated variety – keratinizing (not associated with HPV) and classic variety (warty or Bowenoid) associated with HPV types such as 16, 18, and 33.<sup>7</sup> Inguinal nodal status is the most important prognostic factor associated with progression-free and disease-specific survival. Nodal involvement decreases the 5-year OS rate from 90% to 50%. The status of surgical margins correlates strongly with the risk of local recurrence. Small lesions <2 cm confined to the vulva without extension to adjacent perineal structures (urethra, vagina, and anus) can be managed with radical local excision with a 1-cm margin of normal tissue, the deep margin being the inferior fascia of the urogenital diaphragm.<sup>8</sup>

Recently, there have been endeavors to enhance the quality of life for individuals receiving treatment for vulvar carcinoma. These initiatives encompass the advancement of less intrusive surgical methodologies, such as minimally invasive and robotic-assisted procedures, with the goal of reducing post-operative complications and enhancing cosmetic results. Furthermore, comprehensive supportive care measures, including pain management, psychosocial assistance, and rehabilitation services, assume a pivotal role in attending to the comprehensive needs of patients and fostering their overall well-being throughout treatment. Optimal management of inguinal lymph nodes is the most important factor in reducing mortality from vulvar cancer. Various management modes, such as sentinel node biopsy, inguinofemoral lymph node dissection followed by radiotherapy (RT), RT followed by nodal dissection, or RT alone, are employed

based on staging.<sup>9,10</sup> Prior studies have not subjected the prevalence and prognostic significance of HPV infection in vulvar cancer to statistical aggregation. To validate these individual observations, the objectives of this study were twofold: first, to assess the prevalence of HPV; second, to ascertain the prognostic relevance of HPV and elucidate the potential contributing factors to the heterogeneity in both prevalence and prognostic significance of HPV in vulvar cancer.

This study contributes to the statistics pool regarding the post-treatment complications and short-term follow-up profile of patients with this fourth most common gynecological malignancy.

## Aim and objectives

### Primary objective

To evaluate the incidence and severity of post-treatment complications in patients with carcinoma vulva who have undergone primary surgery.

### Secondary objective

- (1) To evaluate HPV marker positivity in this group of patients and its relation to disease profile and prognosis.
- (2) To assess post-treatment recurrence and mortality encountered during the follow-up period.

## MATERIALS AND METHODS

This retrospective study was conducted in the Regional Cancer Centre, Coimbatore, where data regarding patients with carcinoma vulva who underwent primary surgery were collected from medical records from 2017 to 2023 and scrutinized. Patients satisfying the inclusion criteria were taken up for the study.

### Inclusion criteria

Patients diagnosed with carcinoma vulva who had undergone primary surgery either alone/as part of multimodality treatment, invasive SCC/*in situ* disease histologically, and follow-up data available for at least 18-month post-surgery/adjunct therapy were included in the study.

### Exclusion criteria

Patients with inoperable/metastatic disease at presentation, non-squamous histologies, and inadequate follow-up/defaulters were excluded from the study.

### Ethical consideration

The hospital ethics committee approved the study before initiation. During the enrollment of participants, proper informed consent was taken with an explanation of all the procedures and methods of data collection. Patients who

provided approval for pictorial representation during and after the procedure were enrolled in the study.

### Data collection

The following information was retrieved; patient age, marital and obstetric status, duration of symptoms, imaging, biopsy, staging, multidisciplinary tumor board management decision, surgery performed (type of surgery, nodal dissection done, or not), post-operative course on follow-up, post-operative histopathology (HPE) report (tumor size, histology, margins, LVSI, nodes), HPV marker status by immunohistochemistry, reassessment status post-surgery, adjuvant treatment modality received - RT (number of fractions, duration), chemotherapy (number of cycles, drugs), complications of adjuvant treatment, if any. Due to non-feasibility, the management protocol did not include sentinel lymph node biopsy. The information obtained was analyzed and compared with previous studies, and conclusions were drawn.

### Data analysis and interpretation

The collected data are presented as tables and figures in percentages and values.

## RESULTS

The age distribution included 8 patients below 40 years, 16 between 40 and 60, and 18 patients above 60. Clinical staging revealed 6 cases of VIN, 6 cases of IA, 8 cases of IB, 8 cases of II, and 14 cases of III; no cases were classified as Stage IV (Figure 1). Surgical interventions were performed based on clinical stage: wide excision was conducted in 6 cases for VIN, 6 cases for IA; wide excision with superficial groin dissection in 8 cases for IB; and wide excision with iliofemoral and pelvic node dissection in 22 cases for II and III (Figure 2). Notably, no cases of Stage IV were observed in this cohort (Table 1).

### Staging change after post-operative HPE

There was a change in staging in 3 patients after the final HPE. Two patients whose initial biopsy was vulvar intraepithelial neoplasia were reported as SCC after HPE of the excised specimen (Figures 3 and 4). Based on imaging and clinical examination, another patient initially staged as stage III was found to have positive pelvic nodes on post-operative pathology (Stage IV).

VIN: Initially, there were 6 cases, which were reduced to 4 after post-operative HPE. IA: Initially, there were 6 cases, which increased to 8 after post-operative HPE. IB: The number of cases remained stable at 8 after post-operative HPE. II: Similarly, the number of cases in this stage remained constant at 8 after post-operative HPE. III: Initially, there were 14 cases, which were reduced to 13

after post-operative HPE. IV: While no cases were initially classified as Stage IV, 1 was reclassified as Stage IV after post-operative HPE (Table 2).

### Adjuvant treatment received

In around 52.3% of patients, surgery as the sole modality of treatment sufficed. Twenty patients (around 47%) with Stage II and higher had to undergo adjuvant therapy in chemo RT (Table 3).

### Post-procedure complications

Patients belonging to Stage I had minimal post-operative morbidity overall (only two patients developed seroma post-operatively – managed conservatively). After surgery, nine patients had limb edema, which was managed conservatively (Table 4).

**Table 1: Clinical characteristics of the study group**

Patients characteristics	Number of patients (n)
Age	
Below 40 years	8
40–60 years	16
Above 60 years	18
Clinical stage	
VIN	6
IA	6
IB	8
II	8
III	14
IV	0
Surgical procedure	
Wide excision	6 (VIN)+6 (IA)
Wide excision with superficial groin dissection	8 (IB)
Wide excision with iliofemoral and pelvic node dissection	22 (II, III)

VIN: Vulvar intraepithelial neoplasia

**Table 2: Change in staging post-surgery**

Stage	No. of cases belonging to the specific stage pre-operatively	No. of cases in each stage after post-operative HPE
VIN	6	4
IA	6	8
IB	8	8
II	8	8
III	14	13
IV	0	1

VIN: Vulvar intraepithelial neoplasia, HPE: Histopathology

**Table 3: Adjuvant therapy**

No. of cases	Adjuvant therapy +/-
22	Received
20	Not received

Five patients in Stage III developed seroma, and two had wound dehiscence (Figure 5). It was initially managed by debridement and dressings. Later, raw area cover was given using a tensor fascia lata flap, and after a successful cover, RT was planned (Figure 6).

Taking into account patients in all stages, out of 42 patients, 10 patients had seroma (23%), 9 of them had limb edema (21%), five patients had wound dehiscence (11.5%), nine patients had post-RT/chemotherapy complications (21%) such as edema, skin reactions in the vulva and nodal basins and bowel disturbances.

Complications encountered stage-wise were as follows.

### Disease recurrence

Most recurrences of vulvar cancer occur within the first 1–2 years. Six patients (14%) had recurrence within 18 months. Two patients had local recurrence (one in Stage II and another in Stage III), and four patients had nodal recurrence (in Stages III and IV) (Table 5).

Out of 42 patients, four patients died (9%) within the follow-up period. All four of them died due to nodal relapse. Three of these patients were HPV-negative (75%).

### Association with HPV

p16 positivity indicating HPV association was detected in 18 patients (43%), mostly belonging to the younger age group. Out of 6 patients who developed recurrence, five were found to be negative for HPV marker. Likewise, out of the four patients who died, three were negative for HPV markers (Figures 7 and 8).

Among the 42 patients analyzed in this study, 8 were below 40 years old, all of whom tested positive for p16 (100% positivity rate). Among the 16 patients aged 40 to 60, 10 were p16 positive (63% positivity rate). Interestingly, none of the 18 patients above 60 years were p16 positive. In total, 18 patients across all age groups were p16 positive (43% positivity rate). The preponderance of HPV positivity is high in early-stage and young-age patients (Table 6).

In VIN, 75% of patients were HPV positive; in Stage IA, there was an equal number of HPV positive and negative patients, in Stage IB, 62.5% of patients were HPV positive, in Stage II, 37.5% of patients were HPV positive, and in Stage III, only 15.4% of patients showed HPV positivity, and one case in Stage IV was HPV positive (Table 7).

## DISCUSSION

As vulvar carcinoma is often overshadowed by other gynecological malignancies in frequency of occurrence,

fewer studies in India documenting its demography and outcome. One such study by Nandwani *et al.*, studied the demographic features and outcomes of vulvar carcinoma in the year 2017–2018 in northeast India. Thirty-three patients were studied, belonging to the age group of 60–69 years. The study included all patients with vulvar carcinoma, irrespective of treatment modality.<sup>11</sup> Ours was a similar retrospective study but included only patients who underwent surgery first either alone or followed by RT/chemotherapy and covered a longer duration of case selection – 5 years (2017–2023), with a specific focus on post-surgical outcome.

The current study included a few post-operative complications where seroma was reported in two patients, and nine patients had limb edema managed conservatively. There were concurrences and dissimilarities when comparing the post-operative complication profile we encountered with previously published studies.<sup>12,13</sup> The incidence of seroma or limb edema can be attributed to inadequate wound healing with improper management. However, regular drainage tubes can be placed around the incision to avoid seroma. Cirik *et al.*, reported a 10% incidence of post-operative limb edema and a 23% wound dehiscence rate.<sup>14</sup> Nandwani *et al.*, reported 6% and 18%, whereas our outcomes were 21% and 11%, respectively.<sup>11</sup> These variations may be attributed to factors like patient nutrition and variations in surgical technique.

Patients with Stage III carcinoma also developed seroma, and two were reported with wound dehiscence. The initial debridement and dressings were conducted, followed by a covering with tensor fascia lata flap and RT was planned after the successful covering of the wound. The implementation of soft tissue reconstruction following resection of advanced or recurrent vulvar malignancies is correlated with a diminished incidence of post-operative complications, reduced pain levels, and enhanced functional capabilities. Zhang *et al.*, reported even with the elevated recurrence rate, a notable proportion of individuals undergoing resection for advanced or recurrent vulvar cancer, coupled with reconstructive surgical intervention, demonstrate discernible advantages.<sup>15</sup>

The recurrence rate in our study amounted to 14%, closely resembling the results of a South Indian study by Jeevarajan *et al.*, where it was 20.5%, the minor discrepancy possibly due to the longer period of follow-up (32 months as against 18 months in our study). Similarly, the median age of study group patients in our study was 51 years, comparable with 55 years in the above study.<sup>16</sup>

Patients in our study group had been subjected to wide excision, lymphadenectomy, and the addition of adjuvant

**Table 4: Post-procedure complications**

Stage	Complications – number of cases			
	Seroma	Wound dehiscence	Limb edema	post-RT/chemo reactions
IA	-	-	-	-
IB	2	-	-	-
II	2	2	-	-
III	5	2	8	8
IV	1	1	1	1

RT: Radiotherapy

**Table 5: Site of recurrence**

Site of recurrence	Number of patients
Primary	2
Nodal basin	4

**Table 6: HPV association among age groups**

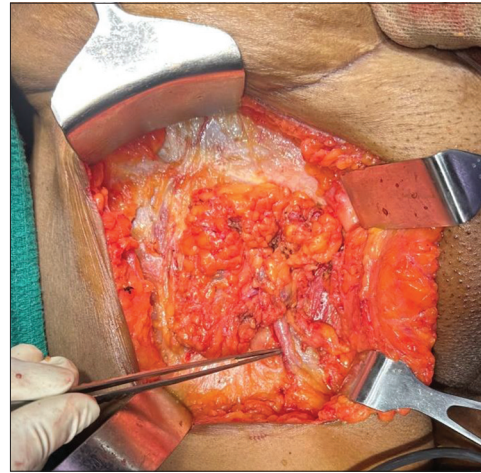
Age group	Number of patients	Number of patients positive for p16
Below 40 years	8	8 (100%)
40–60 years	16	10 (64%)
Above 60 years	18	0
Total	42	18 (43%)

HPE: Histopathology, HPV: Human papillomavirus

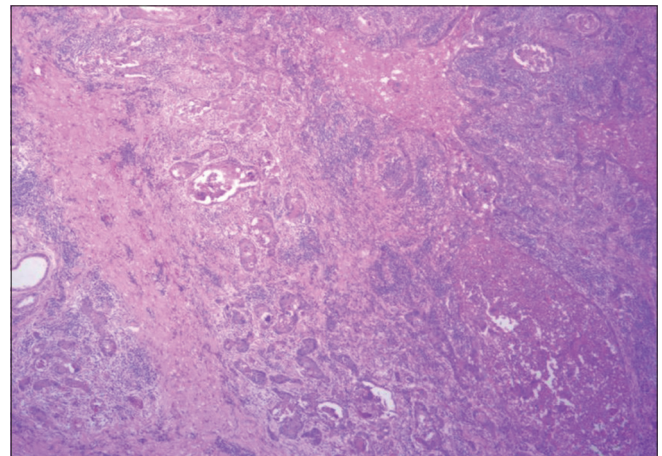
**Table 7: HPV association among HPE stage**

Stage	HPV (p16)	
	Positive	Negative
VIN	3	1
IA	4	4
IB	5	3
II	3	5
III	2	11
IV	1	0

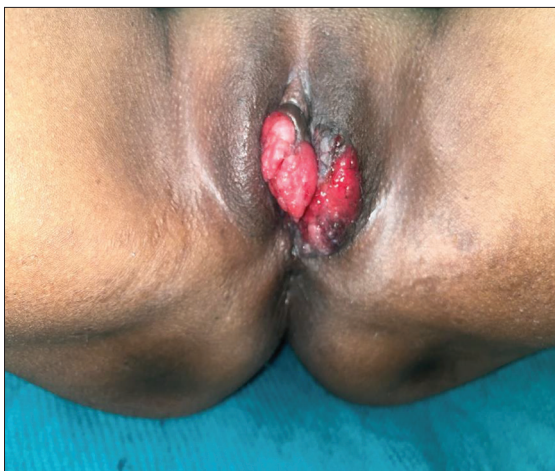HPE: Histopathology, HPV: Human papillomavirus, VIN: Vulvar intraepithelial neoplasia



**Figure 2:** Groin node dissection

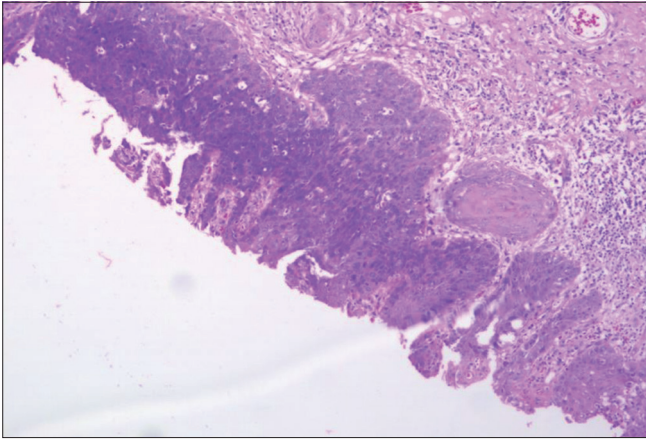


**Figure 3:** Moderately differentiated squamous cell carcinoma

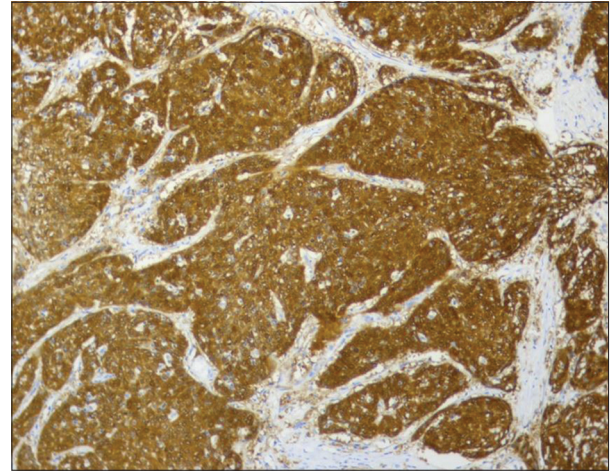


**Figure 1:** A case of carcinoma vulva involving clitoris, labia majora, and minora

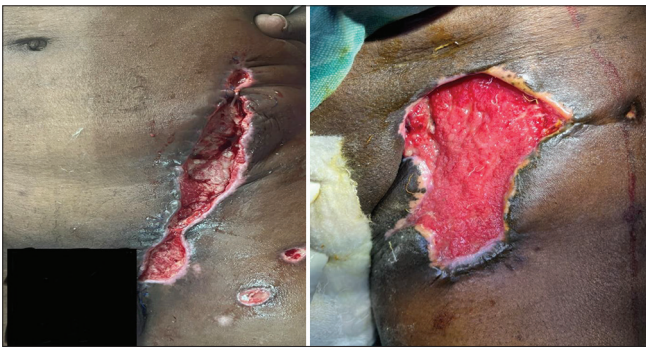therapy as per prescribed guidelines.<sup>17,18</sup> However, due to insufficient facilities for sentinel node biopsy, superficial groin node dissection was carried out for early vulval carcinoma (Stage IB). Alkatout *et al.*, emphasized the importance of sentinel nodal staging in node-negative patients with early-stage vulval cancer as it reduced the operative morbidity caused by inguinofemoral lymphadenectomy.<sup>19</sup> Since our study included only patients who underwent surgery primarily rather than after chemo RT, there were only a few situational comparisons that



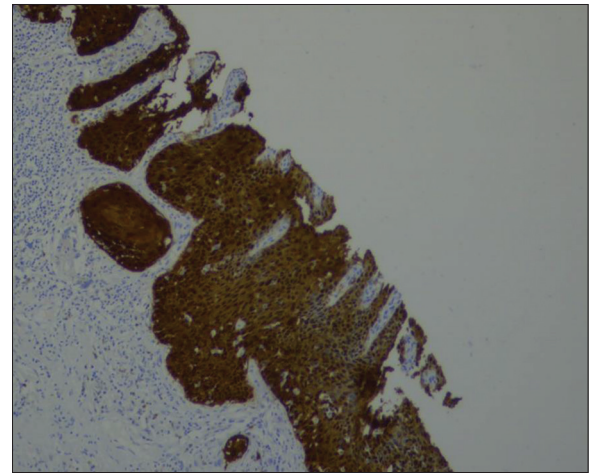
**Figure 4:** Carcinoma *in situ*



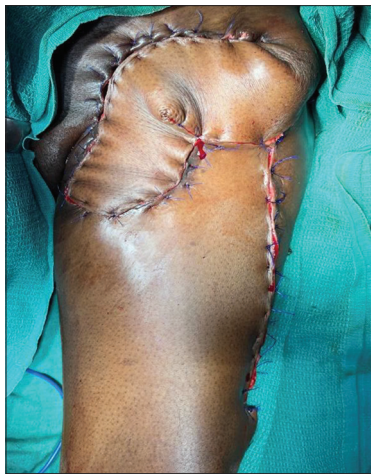**Figure 7:** Strong p16 positivity in invasive component



**Figure 5:** Wound dehiscence



**Figure 8:** P16 stain in *in situ* component



**Figure 6:** Tensor fascia lata flap

could be made, in contrast to the study by Shylasree *et al.*, which made broader comparisons related to the sequence of different treatment modalities.<sup>20</sup>

The current reported a positive status of HPC for 18 patients (43%), mostly in the younger age group. Recurrent patients with valvular carcinoma did not report positive status for HPV (1/5 patients). In addition, morbid patients were presented with negative HPV

status. The prevalence of HPV in vulvar cancer varied in previous studies in different regions of the world, and the prevalence we recorded was 43%. A Danish meta-analysis by Faber *et al.*, reported a pooled prevalence of 39%.<sup>21</sup> Zhang *et al.*, mentioned a prevalence rate of 45% in Asian patients.<sup>22</sup> In most of these studies, p16 and HPV DNA had been used as markers, whereas we could use only p16 for immunohistochemistry due to feasibility concerns. The association between HPV marker positivity as a good prognostic indicator has been documented in some previous studies.<sup>23-25</sup> Bacalbasa *et al.*, studied HPV association with carcinoma vulva in Italian women and concluded that HPV positivity was related to better overall survival.<sup>26</sup> Even though our study was not preplanned to correlate this cause-effect relationship directly, we could indirectly infer the same as mortality and recurrence rates were higher in HPV marker-negative patients in our study. Literature has supported the prevalence of HPV in patients with valvular carcinoma; furthermore, it was observed that HPV positivity was more prevalent in younger patients, contrasting with a higher occurrence

of HPV negativity in older patients with vulvar cancer. Age was identified as a significant prognostic factor in vulvar cancer.<sup>27</sup> In addition, various factors associated with HPV status could potentially impact the prognosis of vulvar cancer patients. For instance, recent research by Rodrigues *et al.*, demonstrated that the loss of  $\beta$ -catenin and heightened expression of Slug, Snail, and Twist were linked with HPV-negative tumors.<sup>28</sup> These alterations in  $\beta$ -catenin and slug expression may augment the likelihood of deeper infiltration and metastasis, indicating a potentially more aggressive behavior exhibited by tumor cells at the tumor periphery. Consequently, patients with HPV-positive tumors tend to exhibit a generally more favorable prognosis, likely attributed to the absence of epithelial-mesenchymal transition (EMT)-like events. Conversely, HPV-negative tumors, which undergo EMT-like events, may display an increased capacity for invasion and progression, ultimately resulting in an unfavorable prognosis and inferior clinical outcomes.

#### Limitations of the study

Since our study's designated post-treatment follow-up period was comparatively short (18 months), few long-term complications and possible mortality could have been missed. Sentinel node biopsy, the standard of management of N0 groin could not be done in our study due to feasibility concerns, which may have resulted in an exaggerated assessment of local morbidity.

#### CONCLUSION

This retrospective analytical study of 42 patients undergoing primary surgery for carcinoma vulva over a 7-year period reported a postoperative wound complication rate of 11%, a recurrence rate of 14%, and a mortality rate of 9% due to nodal disease. Post-operative complications such as seroma in 10 patients with Stage III carcinoma are the highest incidence. Stage III carcinoma was prevalent with most post-operative complications, including limb edema, wound dehiscence, and use of RT or chemotherapy. The current data can help identify the trend of post-operative complications seen in patients with a vulva and HPV. Management strategies such as drainage, debridement, and post-operative antibiotics can be initiated to prevent post-operative complications in patients.

Our data also concur with an increasing prevalence of HPV-associated carcinoma vulva (43%, mostly in the younger age group) and the positive prognosis attributed to it. Although the study has a few inherent limitations such as a narrow spectrum of comparison, non-inclusion of sentinel node biopsy, and shorter follow-up period, we consider it significantly contributing to the post-treatment

analysis pool in our region, especially when HPV vaccines are all set to battle its occurrence.

#### ACKNOWLEDGMENTS

The authors thank doctors, nursing staff, Coimbatore Medical College, and Hospital technicians for their constant support during the procedure (Surgery, ChemoRT), post-operative care, and data collection.

#### REFERENCES

- Shetty AS and Menias CO. MR Imaging of vulvar and vaginal cancer. *Magn Reson Imaging Clin N Am.* 2017;25(3):481-502. <https://doi.org/10.1016/j.mric.2017.03.013>
- Chow L, Tsui BQ, Bahrami S, Masamed R, Memarzadeh S, Raman SS and Patel MK. Gynecologic tumor board: A radiologist's guide to vulvar and vaginal malignancies. *Abdom Radiol (NY).* 2021;46(12):5669-5686. <https://doi.org/10.1007/s00261-021-03209-2>
- Merlo AS. Modern treatment of vulvar cancer. *Radiol Oncol.* 2020;54(4):371-376. <https://doi.org/10.2478/raon-2020-0053>
- Weinberg D and Gomez-Martinez RA. Vulvar cancer. *Obstet Gynecol Clin North Am.* 2019;46(1):125-135. <https://doi.org/10.1016/j.ogc.2018.09.008>
- Ueda Y, Enomoto T, Kimura T, Yoshino K, Fujita M and Kimura T. Two distinct pathways to development of squamous cell carcinoma of the vulva. *J Skin Cancer.* 2011;2011:951250. <https://doi.org/10.1155/2011/951250>
- Siegel RL, Miller KD and Jemal A. Cancer statistics, 2017. *CA Cancer J Clin.* 2017;67(1):7-30. <https://doi.org/10.3322/caac.21387>
- Hansen BT, Campbell S and Nygård M. Long-term incidence trends of HPV-related cancers, and cases preventable by HPV vaccination: A registry-based study in Norway. *BMJ Open.* 2018;8(2):e019005. <https://doi.org/10.1136/bmjopen-2017-019005>
- De Hullu JA and Van der Zee AG. Surgery and radiotherapy in vulvar cancer. *Crit Rev Oncol Hematol.* 2006;60(1):38-58. <https://doi.org/10.1016/j.critrevonc.2006.02.008>
- Rogers LJ. Management of advanced squamous cell carcinoma of the vulva. *Cancers (Basel).* 2021;14(1):167. <https://doi.org/10.3390/cancers14010167>
- Zweizig S, Korets S and Cain JM. Key concepts in management of vulvar cancer. *Best Pract Res Clin Obstet Gynaecol.* 2014;28(7):959-966. <https://doi.org/10.1016/j.bpobgyn.2014.07.00>
- Nandwani M, Barmon D, Begum D, Liegise H and Katakaci AC. An overview of vulvar cancer: A single-center study from Northeast India. *J Obstet Gynaecol India.* 2019;69(6):541-545. <https://doi.org/10.1007/s13224-019-01261-z>
- Wills A and Obermair A. A review of complications associated with the surgical treatment of vulvar cancer. *Gynecol Oncol.* 2013;131(2):467-479. <https://doi.org/10.1016/j.ygyno.2013.07.082>
- Huang J, Yu N, Wang X and Long X. Incidence of lower limb lymphedema after vulvar cancer: A systematic review and meta-

- analysis. *Medicine (Baltimore)*. 2017;96(46):e8722.  
<https://doi.org/10.1097/md.00000000000008722>
14. Cirik DA, Karalok A, Ureyen I, Tasci T, Kalyoncu R, Turkmen O, et al. Early and late complications after inguinofemoral lymphadenectomy for vulvar cancer. *Asian Pac J Cancer Prev*. 2015;16(13):5175-5179.  
<https://doi.org/10.7314/apjcp.2015.16.13.5175>
  15. Zhang W, Zeng A, Yang J, Cao D, He X, Wang X, et al. Outcome of vulvar reconstruction in patients with advanced and recurrent vulvar malignancies. *BMC Cancer*. 2015;15:851.  
<https://doi.org/10.1186/s12885-015-1792-x>
  16. Jeevarajan S, Duraipandian A, Seenivasagam RK, Shanmugam S and Ramamurthy R. Treatment outcome of carcinoma vulva ten-year experience from a tertiary cancer centre in south India. *Int J Surg Oncol*. 2017;2017:7161437.  
<https://doi.org/10.1155/2017/7161437>
  17. Maggino T, Landoni F, Sartori E, Zola P, Gadducci A, Alessi C, et al. Patterns of recurrence in patients with squamous cell carcinoma of the vulva. A multicenter CTF study. *Cancer*. 2000;89(1):116-122.  
[https://doi.org/10.1002/1097-0142\(20000701\)89:1<116::aid-cncr16>3.0.co;2-4](https://doi.org/10.1002/1097-0142(20000701)89:1<116::aid-cncr16>3.0.co;2-4)
  18. Levenback CF, Ali S, Coleman RL, Gold MA, Fowler JM, Judson PL, et al. Lymphatic mapping and sentinel lymph node biopsy in women with squamous cell carcinoma of the vulva: A gynecologic oncology group study. *J Clin Oncol*. 2012;30(31):3786-3791.  
<https://doi.org/10.1200/jco.2011.41.2528>
  19. Alkatout I, Günther V, Schubert M, Weigel M, Garbrecht N, Jonat W, et al. Vulvar cancer: Epidemiology, clinical presentation, and management options. *Int J Womens Health*. 2015;7:305-313.  
<https://doi.org/10.2147/ijwh.s68979>
  20. Shylasree TS, Bryant A and Ej Howells RE. Chemoradiation for advanced primary vulvar cancer. *Cochrane Database Syst Rev*. 2011;2011(4):CD003752.  
<https://doi.org/10.1002/14651858.cd003752.pub3>
  21. Faber MT, Sand FL, Albieri V, Norrild B, Kjaer SK and Verdoodt F. Prevalence and type distribution of human papillomavirus in squamous cell carcinoma and intraepithelial neoplasia of the vulva. *Int J Cancer*. 2017;141(6):1161-1169.  
<https://doi.org/10.1002/ijc.30821>
  22. Zhang J, Zhang Y and Zhang Z. Prevalence of human papillomavirus and its prognostic value in vulvar cancer: A systematic review and meta-analysis. *PLoS One*. 2018;13(9):e0204162.  
<https://doi.org/10.1371/journal.pone.0204162>
  23. Santos M, Landolfi S, Olivella A, Lloveras B, Klaustermeier J, Suárez H, et al. P16 Overexpression identifies HPV-positive vulvar squamous cell carcinomas. *Am J Surg Pathol*. 2006;30(11):1347-1356.  
<https://doi.org/10.1097/01.pas.0000213251.82940.bf>
  24. Hay CM, Lachance JA, Lucas FL, Smith KA and Jones MA. Biomarkers p16, human Papillomavirus and p53 predict recurrence and survival in early stage squamous cell carcinoma of the vulva. *J Low Genit Tract Dis*. 2016;20(3):252-256.  
<https://doi.org/10.1097/lgt.0000000000000182>
  25. Rasmussen CL, Sand FL, Hoffmann Frederiksen M, Andersen KL and Kjaer SK. Does HPV status influence survival after vulvar cancer? *Int J Cancer* 2018;142(6):1158-1165.  
<https://doi.org/10.1002/ijc.31139>
  26. Bacalbasa N, Balescu I, Suciú I, Dima S and Suciú N. HPV Infection and Vulvar Cancer. *Current Perspectives in Human Papillomavirus*. London: IntechOpen; 2018.
  27. Miljanović-Špika I, Madunić MD, Topolovec Z, Kujadin Kenjereš D and Vidosavljević D. Prognostic factors for vulvar cancer. *Acta Clin Croat* 2021;60(1):25-32.  
<https://doi.org/10.20471/acc.2021.60.01.04>
  28. Rodrigues IS, Lavorato-Rocha AM, de M Maia B, Stiepcich MM, de Carvalho FM, Baiocchi G, et al. Epithelial-mesenchymal transition-like events in vulvar cancer and its relation with HPV. *Br J Cancer* 2013;109:184-94.  
<https://doi.org/10.1038/bjc.2013.273>

**Author's Contributions:**

**BG**- Review manuscript; **SKN**- Editing manuscript; **RP**- Manuscript preparation, literature review, data collection, data analysis; **SN**- Protocol review, review manuscript

**Work attributed to:**

Department of Surgical Oncology, Regional Cancer Centre, Government Coimbatore Medical College and Hospital, Coimbatore, Tamil Nadu, India.

**Orcid ID:**

Dr. Balamurugan G- <https://orcid.org/0009-0000-9849-208X>

Dr. Senthil Kumar N- <https://orcid.org/0009-0006-4107-725X>

Dr. Ramkumar P- <https://orcid.org/0000-0002-4683-6490>

Dr. Selvaraj N- <https://orcid.org/0009-0005-0648-8080>

**Source of Support:** Nil, **Conflicts of Interest:** None declared.