

Morphometrical parameters of acetabulum of hip bone - An osteological study



Meril Ann Soman¹, Rani Nallathamby², Shivarama Bhat³, Godly Sara Sabu⁴

¹Associate Professor, Department of Anatomy, Believers Church Medical College and Hospital, Thiruvalla, ²Associate Professor, Department of Anatomy, Azeezia Medical College, Azeezia Institute of Medical Sciences and Research, Kollam, ⁴Assistant Professor, Department of Anatomy, Government T. D. Medical College, Alappuzha, Kerala, ³Professor, Department of Anatomy, Yenepoya Medical College, Mangaluru, Karnataka, India

Submission: 24-08-2023

Revision: 02-11-2023

Publication: 01-12-2023

ABSTRACT

Background: Acetabulum is an approximately hemispherical cavity on the lateral aspect of the hip bone. Acetabulum is not always of the same shape, size, or depth. Any deviations of the parameters from normal range have strong correlation with the development of various kinds of pathologies. **Aims and Objectives:** Acetabulum is an approximately hemispherical cavity on the lateral aspect of the hip bone. Acetabulum is not always of the same shape, size or depth. Any deviations of the parameters from normal range have strong correlation with the development of various kinds of pathologies. **Materials and Methods:** This study was conducted in department of Anatomy, Yenepoya Medical College, Mangalore. Two hundred hip bones were included in the study. Various parameters of the acetabulum were measured. The morphometrical parameters measured were: (a) Transverse diameter of acetabulum, (b) acetabular height, (c) acetabular depth, (d) acetabular volume, (e) distance from pubic tubercle to anterior rim of acetabulum, (f) ratio between distance from pubic tubercle to anterior rim of acetabulum and acetabular height. Range, mean, standard deviation, and standard error of mean were determined for each parameter. P value was also calculated to compare the parameters side wise. **Results:** The independent T test was done and the P value was calculated for each parameter. Acetabular volume showed a significant difference between left- and right-sided bones. Most of the parameters showed highly significant difference between male and female hip bones in both right side and left side. **Conclusion:** As total and partial hip replacements are common surgeries performed these days, knowledge of the dimensions of acetabulum will assist prosthetists to construct suitable prosthesis for Indian population. It would be also useful in the fields of anatomy, osteology, and anthropology.

Key words: Acetabulum; Pelvic bone; Forensic anthropology; Parameters; Hip replacement surgeries

INTRODUCTION

The hip bone also known as innominate bone, pelvic bone, or coxal bone is composed of three smaller bones – ilium, ischium, and pubis. Acetabulum (cotyloid cavity) (Latin Acetabulum - shallow vinegar cup) is an approximately hemispherical cavity on the lateral aspect of the hip bone, facing anteroinferiorly and is directed laterally, downward and forward. It is surrounded by an irregular margin and is deficient inferiorly at the acetabular notch. The acetabular fossa which forms the central floor is rough and non-articular.¹ The fossa is devoid of cartilage and contains fibroelastic fat

which is covered by synovial membrane. The acetabular depth is increased by a fibrocartilaginous rim, the acetabular labrum attached to the acetabular margin. The labrum deepens the cup and bridges the acetabular notch forming the transverse acetabular ligament. The sides of the cup present a horse shoe shaped (lunate) articular surface which is widest superiorly (the “dome”), where weight is transmitted to the femur in the erect attitude. All the three innominate elements of hip bone contribute to the formation of acetabulum in humans but not in equal proportions. Ischium forms the lower and side boundaries to the acetabulum. Ilium forms the upper boundary and the rest is formed by the pubis.²

Access this article online

Website:

<http://nepjol.info/index.php/AJMS>

DOI: 10.3126/ajms.v14i12.57942

E-ISSN: 2091-0576

P-ISSN: 2467-9100

Copyright (c) 2023 Asian Journal of Medical Sciences



This work is licensed under a Creative Commons Attribution-NonCommercial 4.0 International License.

Address for Correspondence:

Dr. Shivarama Bhat, Professor, Department of Anatomy, Yenepoya Medical College, Mangaluru, Karnataka, India.

Mobile: +91-9448811296. E-mail: bhatshivarama2000@gmail.com

Acetabulum is not always of the same shape, size, or depth. Any deviations of the parameters from normal range have strong correlation with the development of various kinds of pathologies related to acetabulum.

The anatomy of the acetabulum of hip bone, in recent years has received the much deserved attention because of the importance of early treatment of congenital dislocation of hip joint and advent of arthroplasty procedures. The knowledge of normal anatomical features and the morphometry of the acetabulum are prerequisites for complete understanding of the mechanics of hip joint. The diameter, depth, and volume of the acetabulum are important in the surgical treatment of acetabular fractures and hip arthroplasty. Hip replacement surgeries are commonly done these days. Most common complications include prosthetic loosening and geometric discrepancies between the natural acetabulum and the implant.³

Precise size and measurement of acetabulum are useful in total or hemi arthroplasty to plan the size of prosthesis. The knowledge of range of various acetabular parameters may be of great help for prosthetists, radiologists, orthopedicians, and clinicians for better understanding of the hip joint and preparing suitable size of prosthesis, thus preventing complications such as prosthetic loosening or dislocation.⁴

Aims and objectives

The present study was undertaken to measure certain morphometrical parameters of acetabulum in dry human hip bones of South Indian population. The values are then compared based on gender and laterality and conclusions are drawn through statistical analysis.

The morphometrical parameters measured are

- a) Transverse diameter of acetabulum
- b) Acetabular height
- c) Acetabular depth
- d) Acetabular volume
- e) Distance from pubic tubercle to anterior rim of acetabulum
- f) Ratio between distance from pubic tubercle to anterior rim of acetabulum and acetabular height.

MATERIALS AND METHODS

This study was conducted in department of Anatomy, Yenepoya Medical College, Mangalore. Hip bones of both sides were included in the study. Of the 200 bones studied, 116 belonged to right side (58%) and 84 belonged to left side (42%). Among 84 left-sided hip bones, 52 were male and 32 were female hip bones. Among 116 right-sided bones, 58 were male and 58 were female hip bones.

All the hip bones selected were dry, complete and showed normal anatomical features. Specimens showing osteoarthritic changes, evidence of any previous trauma or skeletal disorders, presence of any prosthesis and pediatric-sized bones were excluded from the study. Various parameters of the acetabulum were measured. The measurements were taken using sliding Vernier Calipers, graduated scale, ceramic powder, and a graduated measuring cylinder.

Three readings were taken for each parameter at different times and the average was recorded. All measurements were carried out with the same instrument throughout the study.

Side determination and determination of gender were done based on the following features:

Side determination

1. The acetabulum is directed laterally
2. Ilium forms upper part of the bone that lies above the acetabulum
3. The obturator foramen lies below the acetabulum.

Determination of gender

- Male hip bones showed prominent muscular markings, thick and everted ischio-pubic rami, large acetabular cavity, large and oval obturator foramen, and scarcely visible pre-auricular sulcus.
- Female hip bones showed less prominent muscular markings, thin and inverted ischio pubic rami, small acetabular cavity, triangular obturator foramen, and predominantly visible pre-auricular sulcus.

Transverse diameter

It was measured using the vernier caliper as the maximum anteroposterior transverse distance between the margins of acetabular cavity (Figure 1).

Acetabular height

It was measured as the vertical diameter of the acetabulum measured along its axis keeping the bone in anatomical position. The measurement was taken using vernier caliper (Figure 2).

Acetabular depth

It was taken as the maximum vertical distance from the brim of the acetabulum to the deepest point in the acetabular cavity and was measured using vernier calipers. A thin metallic strip was placed across the brim of the acetabular cavity and then the distance from the metallic strip to the depth of the acetabulum was measured using a vernier caliper (Figure 3).

Volume

It was considered as the capacity of the acetabular cavity. The acetabular notch was plugged using a small

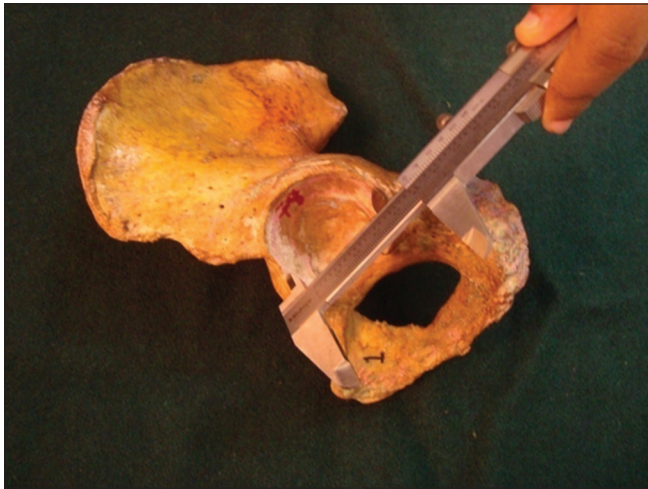


Figure 1: Measurement of transverse diameter of acetabulum

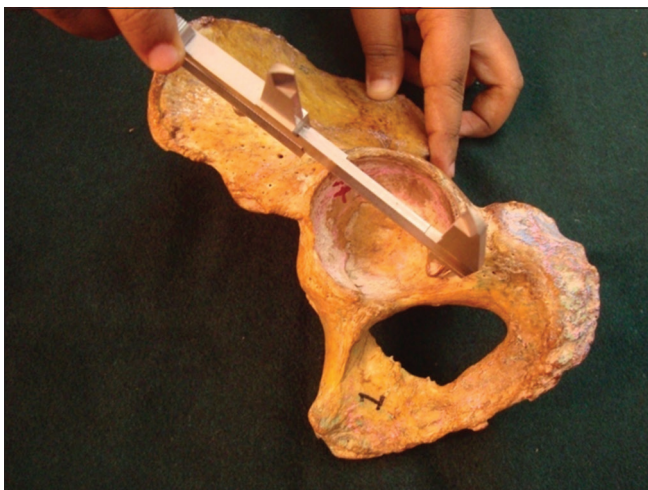

Figure 2: Measurement of acetabular height

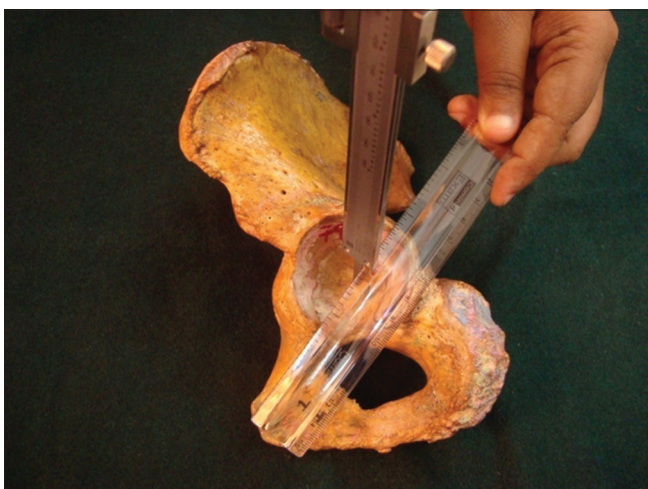

Figure 3: Measurement of acetabular depth

cardboard piece and the acetabular cavity was filled with the ceramic powder. The powder was then transferred into a graduated measuring cylinder and the volume was recorded (Figure 4).

The distance from pubic tubercle to anterior rim of acetabulum

It was measured using the vernier caliper from the pubic tubercle to the most prominent point on the anterior rim of acetabulum (Figure 5).

Ratio between distance from the pubic tubercle to anterior rim of acetabulum and acetabular height

It was calculated for each hip bone.

Range, mean, standard deviation, and standard error of mean were determined for each parameter. P value was also calculated to compare the parameters.

RESULTS

Of the 200 bones measured, 116 belonged to right side (58%) and 84 belonged to left side (42%). (Table 1 and Chart 1). An attempt was made to compare the morphometrical parameters of acetabulum sidewise using independent t-test. Independent t-test, also




Figure 4: (a and b) Measurement of acetabular volume



Figure 5: Measurement of distance from pubic tubercle to anterior acetabular rim

known as the two Sample *t*-test or Student's *t*-test, is an inferential statistical test that determines whether there is a statistically significant difference between the means in two unrelated groups. It compares the means between two unrelated groups on the same continuous dependent variable. Unrelated groups or independent groups are groups in which the cases in each group are different. P value indicates the significance value of the test.

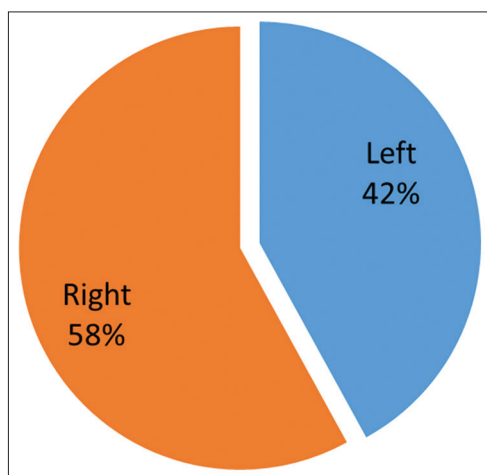


Chart 1: Percentage of distribution of the sample in terms of laterality

Table 1: Frequency and percentage of distribution of the sample in terms of laterality		
Entity	Frequency	Percentage of distribution
Left	84	42.0
Right	116	58.0
Total	200	100.0

Table 2 shows the side-wise comparison of the morphometrical parameters. The maximum value, minimum value, mean, standard deviation, median and standard error of mean were calculated for each parameter. P value was also calculated to compare the parameters side wise.

The independent T test was done and the P value was calculated for each parameter. Acetabular volume showed a significant difference between left- and right-sided bones. All the other parameters are non-significant in terms of laterality. Therefore, the table shows that there is no much significant difference in the parameters between right and left hip bones except for acetabular volume (Table 2 and Diagram 1).

Table 3 shows the frequency and percentage of distribution of males and females in both right side and left sided bones.

Among 84 left-sided hip bones, 52 were male bones and 32 were female bones. Among 116 right sided bones, 58 were male and 58 were female bones (Table 3).

A comparative study was done between the genders in right-sided bones and also in left-sided bones. Table 4 shows the comparison of the morphometrical parameters between males and females of both right-sided and left-sided bones. The maximum value, minimum value, mean, standard deviation, median, and standard error of mean were calculated for each parameter. P value was also calculated to compare the parameters.

The independent T test was done and the P value was calculated for each parameter. All the parameters showed significant difference between male and female hip bones

Table 2: Comparison of the morphometrical parameters in terms of laterality										
Parameters	Side	Number	Minimum value	Maximum value	Mean	Standard deviation	Median	Standard error of mean	t test value	P value
Transverse diameter of acetabulum	Left	84	38	56	47.70	3.779	48.00	0.412	1.059	0.291
	Right	116	38	56	47.14	3.676	47.00	0.341		
Acetabular height	Left	84	42	58	49.65	3.579	49.50	0.390	0.049	0.961
	Right	116	41	62	49.63	3.675	50.00	0.341		
Acetabular depth	Left	84	19	38	25.71	3.747	25.00	0.409	0.595	0.552
	Right	116	18	34	25.41	3.352	25.00	0.311		
Acetabular Volume	Left	84	10	45	23.96	6.083	23.50	0.664	2.436	0.016
	Right	116	11	42	22.04	5.045	21.50	0.468		
Distance from PT-anterior rim of acetabulum	Left	84	43	76	53.57	6.110	53.00	0.667	0.259	0.796
	Right	116	42	64	53.38	4.397	53.00	0.408		
Ratio between distance from PT- anterior rim of acetabulum and acetabular height	Left	84	0.82	1.46	1.0818	0.12338	1.0600	0.01346	0.149	0.882
	Right	116	0.85	1.33	1.0795	0.09526	1.0800	0.00884		

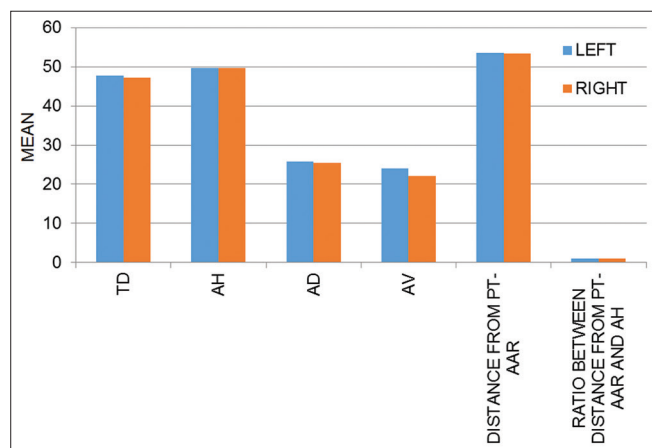


Diagram 1: Comparison of the morphometrical parameters of acetabulum in terms of laterality

Table 3: Frequency and percentage of distribution of males and females in both right-sided and left-sided bones

Side of hip bone	Gender		Total
	Male	Female	
Laterality			
Left	52 (61.9%)	32 (38.1%)	84 (100%)
Right	58 (50%)	58 (50%)	116 (100%)
Total	110 (55%)	90 (45%)	200 (100%)

in both right side and left side except for acetabular depth. No significant difference was obtained in case of acetabular depth between males and females of both right side and left side. Furthermore, ratio between distance from pubic tubercle to anterior rim of acetabulum and acetabular height showed no significant difference between male and female bones of the right side (Table 4).

DISCUSSION

The advantage of studying bones of human remains is that they are very resistant to time and their features can be observed and measured even long after the death of the individual. Hip joint is one of the major joints of the body. Although it is described as a ball and socket variety of synovial joint, Menschik⁵ describes it as a rotational conchoid. Knowledge of the anatomical parameters of the bony components of hip joint is very essential as it will open new horizons into better understanding of etiopathogenesis of diseases such as osteoarthritis of hip joint.

As total and partial hip replacements are common surgeries performed these days, knowledge of the dimensions of acetabulum will assist prosthetists to construct suitable prosthesis for Indian population. The largest hip failure occurs from prosthetic loosening. It can be either due to an

originally weak interface or because the cemented interface is not strong enough to bear the loads.⁶

As race, climate, heredity, and geographical areas have strong influence over the anthropometric parameters of bone, the present study was undertaken to note the morphological and the morphometrical parameters of acetabulum in south Indian cadaveric hip bones. Not many works have been done in Indian population. The implant devices and prosthesis designed for Western skeleton are larger in size, angles, orientations, and thread length exhibiting mismatches when the same is used in Indian skeletons. To avoid this problem, the surgeons fit the prosthesis or implants by removing more bone which decreases bone density, increasing the risk of intra operative fractures and post-operative complications. Implants that are designed by taking into account anthropometric and bio mechanic data will help in designing patient specific implants thereby minimizing these complications. Proper positioning of the components and good soft-tissue repair is the key to the success of arthroplasty surgery. Therefore, the present study would have great anthropological, forensic, and clinical significance.⁷

In the present study, 200 bones were studied of which 116 belonged to the right side and 84 belonged to the left side. Among 84 left-sided hip bones, 52 were male bones and 32 were female bones. Among 116 right-sided bones, 58 were male and 58 were female bones. The morphometrical parameters were statistically analyzed. Independent t test were applied for the morphometrical parameters and p value was calculated. According to the study, the parameters showed no significant difference in terms of laterality except for acetabular volume which showed significant difference between right- and left-sided bones. The study was also done among male and female bones of both right side and left side. Significant results were obtained in both right side and left side except for acetabular depth. The ratio between distance from pubic tubercle to anterior rim of acetabulum and acetabular height showed significant difference only on the left side.

In the present study, the acetabular diameter was measured and compared with the findings of the previous studies. The mean diameter of acetabulum in the present study is 47.14 mm on the right side and 47.70 mm on the left side. The values obtained in the present study are similar to the values obtained by Chauhan et al.⁸ and Vyas et al.⁹ The values obtained from studies done by Dhindsa¹⁰ and Ukoha et al.,¹¹ are comparatively higher than the values from present study. The diameter of the acetabular cavity is constricted by the labral rim, which embraces the femoral head, maintaining joint stability both as a static restraint and by providing proprioceptive information (Table 5).

Table 4: Comparison of the morphometrical parameters between genders in both right-sided and left-sided bones

Parameters	Side	Sex	Number	Minimum value	Maximum value	Mean	Standard deviation	Median	Standard error of mean	t test value	P value
Transverse diameter of acetabulum	Left	Male	52	42	56	48.94	3.578	49.00	0.496	4.200	0.000
		Female	32	38	51	45.69	3.227	45.00	0.571		
		Total	84	38	56	47.70	3.779	48.00	0.412		
	Right	Male	58	41	56	48.57	3.569	49.00	0.469	5.364	0.000
		Female	58	38	53	45.71	3.217	45.50	0.422		
		Total	116	38	56	47.14	3.676	47.00	0.341		
Acetabular height	Left	Male	52	44	58	51.08	3.149	51.50	0.437	3.006	0.004
		Female	32	42	54	47.34	3.012	47.50	0.532		
		Total	84	42	58	49.65	3.579	49.50	0.390		
	Right	Male	58	42	62	51.21	3.722	52.00	0.489	3.726	0.000
		Female	58	41	55	48.05	2.886	48.00	0.379		
		Total	116	41	62	49.63	3.675	50.00	0.341		
Acetabular depth	Left	Male	52	20	34	26.63	3.401	26.00	0.472	1.228	0.223
		Female	32	19	38	24.22	3.850	24.00	0.681		
		Total	84	19	38	25.71	3.747	25.00	0.409		
	Right	Male	58	18	34	26.14	3.415	25.50	0.448	1.891	0.062
		Female	58	18	32	24.69	3.152	24.00	0.414		
		Total	116	18	34	25.41	3.352	25.00	0.311		
Acetabular volume	Left	Male	52	16	45	25.77	5.893	25.00	0.817	4.536	0.000
		Female	32	10	35	21.03	5.252	20.00	0.928		
		Total	84	10	45	23.96	6.083	23.50	0.664		
	Right	Male	58	14	42	24.26	5.028	24.00	0.660	5.102	0.000
		Female	58	11	29	19.83	4.009	20.00	0.526		
		Total	116	11	42	22.04	5.045	21.50	0.468		
Distance from PT-anterior rim of acetabulum	Left	Male	52	43	76	54.21	6.515	53.50	0.903	2.373	0.019
		Female	32	43	70	52.53	5.322	51.00	0.941		
		Total	84	43	76	53.57	6.110	53.00	0.667		
	Right	Male	58	46	64	54.67	4.240	54.00	0.557	5.247	0.000
		Female	58	42	60	52.09	4.198	52.00	0.551		
		Total	116	42	64	53.38	4.397	53.00	0.408		
Ratio between distance from PT-anterior rim of acetabulum and acetabular height	Left	Male	52	0.82	1.36	1.0621	0.11361	1.0400	0.01575	3.301	0.001
		Female	32	0.83	1.46	1.1138	0.13348	1.0900	0.02360		
		Total	84	0.82	1.46	1.0818	0.12338	1.0600	0.01346		
	Right	Male	58	0.85	1.33	1.0714	0.10126	1.0600	0.01330	0.916	0.362
		Female	58	0.92	1.28	1.0876	0.08900	1.0800	0.01169		
		Total	116	0.85	1.33	1.0795	0.09526	1.0800	0.00884		

Table 5: Comparison of transverse diameter of acetabulum in the present study with the past studies

Authors	Year	Mean diameter of acetabulum (mm)	
		Right	Left
Lander ¹²	1918	57	56
Mukhopadhyay and Barooah ¹⁴	1967	45.7	45.9
Chauhan et al. (in male bones) ⁸	2002	47.1	47.5
Chauhan et al. (in female bones) ⁸	2002	44.4	46
Dhindsa ¹⁰	2013	51.3	50.3
Vyas et al. ⁹	2013	48.3	47.9
Ukoha et al. ¹¹	2014	53.9	53.2
Present study	2015	47.14	47.70

Table 6: Comparison of height of acetabulum in the present study with the past studies

Authors	Year	Acetabular height (mm)
Aksu et al. ⁴	2006	54.29
Mukhopadhyay and Barooah ¹⁴	2012	50.30
Parmara et al. ¹³	2013	49.23
Present study	2015	49.64

acetabular height in the present study is 49.64 mm which is in close accordance with the study done by Parmara et al.¹³ and Mukhopadhyay and Barooah.¹⁴ The mean value of the acetabular height is slightly higher in the study done by Aksu et al.⁴ (Table 6).

In the present study, the acetabular height was measured and compared with the findings of the past studies. The mean

In the present study, the acetabular depth was measured and compared with the findings of the past studies. In

Table 7: Comparison of the depth of acetabulum in the present study with the past studies

Authors	Year	Range of acetabular depth
Chauhan et al. ⁸	2002	23–34 mm
Aksu et al. ⁴	2006	22.6–38.6 mm
Dhindsa ¹⁰	2013	20–32 mm
Vyas et al. ⁹	2013	19.6–32.2 mm
Parmara et al. ¹³	2013	19.07–32.13 mm
Rajkumar et al. ¹⁵	2014	13–38 mm
Ukoha et al. ¹¹	2014	21.7–35.7 mm
Devi and Chandra ¹⁶	2014	21.8–34.6 mm
Present study	2015	18–38 mm

Table 8: Comparison of volume of acetabulum in the present study with the past studies

Authors	Year	Mean volume of acetabulum (in ml)
Tan et al. ¹⁷	2001	31.5
Chung et al. ¹⁸	2008	14.2
Dhindsa ¹⁰	2013	35.12
Khobragade and Vatsalawamy ¹⁹	2014	20.74
Present study	2015	22.85

the present study, the acetabular depth ranges from 18 to 38 mm. The values obtained from studies done by Rajkumar et al.¹⁵ and Devi et al.¹⁶ are almost similar with the data obtained from present study as shown in the table. The main complication for acetabular placement will be positioning the acetabular cup implant and acetabular inclination to the correct location according to its acetabular version and the acetabular depth. Dysplastic hip correlates with the acetabular depth (Table 7).

In the present study, the volume of the acetabulum was measured and compared with the findings of the past studies. Acetabular volume also showed significant difference between right sided and left sided hip bones. The parameter also showed highly significant difference in male and female bones of both right side and left side.

The mean value of volume in the present study is 22.85 ml. The value obtained by Tan et al.,¹⁷ was 31.5 ml and value obtained by Chung et al.,¹⁸ was 14.2 ml. The value obtained by Khobragade and Vatsalawamy¹⁹ was 20.74 ml which is in accordance with the values obtained from the present study as shown in the table. Reconstructive acetabular osteotomies can affect the acetabular volume. Volume mismatch between the femoral head and the acetabulum should be considered preoperatively. Accurate measurement of the volume of acetabulum is difficult because of the unusual shape and the spatial orientation of the acetabulum (Table 8).

In the present study, the distance from pubic tubercle to anterior acetabular rim was also measured. It also showed

significant difference among male and female bones of both right and left sides.

The ratio between the distance from pubic tubercle to anterior acetabular rim and acetabular height was also calculated in the present study. It showed significant difference between male and female hip bones of the left side.

Limitations of the study

However, it should be kept in mind that the present study and the previous studies have included small number of hip bones and though the results showed significant differences, it is worthwhile to perform a similar further study with a large number of bones from different age periods and from diverse population of India.

CONCLUSION

The overall goal of this study was to generate data that would be useful to the orthopedicians for geometric modeling. The study would also help the forensic experts in specimen identification and sex determination from skeletal remains. It would also be valuable for the anthropologists in their racial and population studies.

More studies are to be conducted in this field, as knowledge about these differences may prove great use in the management of orthopedic hip conditions and defines the prognosis in hip replacement as well as correction procedures. The present study was undertaken to prevent problems following surgical procedures such as acetabular reconstruction and femoroacetabular impingement. The results of this study would be definitely useful in the selection of patients for prosthesis and preoperative planning for total hip replacement surgery and also in various fields of orthopedics and general surgery in Indian population. It would be also useful in the fields of anatomy, osteology, and anthropology.

ACKNOWLEDGMENT

We thank Yenepoya Medical College for providing us the bones to conduct the study and to reach a conclusion.

REFERENCES

1. Standring S and Williams A. Pelvic Girdle, Gluteal Region and Hip Joint. Grays Anatomy: The Anatomical Basis of Clinical Practice. 39th ed. New York: Elsevier Churchill Livingstone; 2005. P. 1421-1440.
2. Govsa F, Ozer MA and Ozgur Z. Morphologic features of the acetabulum. Arch Orthop Trauma Surg. 2005;125(4):453-461. <https://doi.org/10.1007/s00402-005-0020-6>
3. Vandenbussche E, Saffarini M, Taillieu F and Mutschler C. The

- asymmetric profile of the acetabulum. *Clin Orthop Relat Res.* 2008;466(2):417-423.
<https://doi.org/10.1007/s11999-007-0062-x>
4. Aksu FT, Ceri NG, Arman C and Tetik S. Morphology and morphometry of the acetabulum. *Deu Tip Fakultesi Dergisi.* 2006;20(3):143-148.
 5. Menschik F. The hip joint as a conchoid shape. *J Biomechan.* 1997;30(9):971-973.
[https://doi.org/10.1016/S0021-9290\(97\)00051-1](https://doi.org/10.1016/S0021-9290(97)00051-1)
 6. Murray RO. The aetiology of primary osteoarthritis of the hip. *Br J Radiol.* 1965;38(455):810-824.
<https://doi.org/10.1259/0007-1285-38-455-810>
 7. Leung KS and Chen CM. Multicenter trial of modified gamma nail in East Asia. *Clin Orthop Relat Res.* 1996;323:146-154.
<https://doi.org/10.1097/00003086-199602000-00020>
 8. Chauhan R, Paul S and Dhaon BK. Anatomical parameters of north Indian hip joints: Cadaveric study. *J Anat Soc India.* 2002;51(1):39-42.
 9. Vyas K, Shroff B and Zanzrukiya K. An osseous study of morphological aspect of hip bone. *Int J Res Med.* 2013;2(1):78-82.
 10. Dhindsa GS. Acetabulum: A morphometric study. *J Evolut Med Dent Sci.* 2013;2(7):657-665.
<https://doi.org/10.14260/jemds/320>
 11. Ukoha UU, Umeasalugo KE, Okafor JI, Ndukwe GU, Nzeakor HC and Ekwunife DO. Morphology and morphometry of dry adult acetabula in Nigeria. *Rev Arg Anat Clin.* 2014;6(3):150-155.
<https://doi.org/10.31051/1852.8023.v6.n3.14139>
 12. Lander KF. The examination of a skeleton of known age, race, and sex. *J Anat.* 1918;52(Pt 3):282-291.
 13. Parmara G, Rupareliab S, Patelc SV, Patelb SM and Jethvaa N. Morphology and morphometry of acetabulum. *Int J Biol Med Res.* 2013;4(1):2924-2926.
 14. Mukhopadhaya B and Barooah B. Osteoarthritis of hip in Indians. An anatomical and clinical study. *Indian J Orthopaed.* 1967;1(1):55-62.
 15. Rajkumar, Sachan A and Meena KR. The relationship between depth and diameter of human acetabulum in dry hip bone of Indian population. *Int J Sci Res.* 2014;3(12):1574-1576.
 16. Devi TB and Chandra PX. Acetabulum-morphological and morphometrical study. *RJPBCS.* 2014;5(6):793-799.
 17. Tan V, Seldes RM, Katz MA, Freedhand AM and Klimkiewicz JJ. Contribution of acetabular labrum to articulating surface area and femoral head coverage in adult hip joints: An anatomic study in cadavera. *Am J Orthop.* 2001;30(11):809-812.
 18. Chung CY, Choi IH, Cho TJ, Yoo WJ, Lee SH and Park MS. Morphometric changes in the acetabulum after Dega osteotomy in patients with cerebral palsy. *J Bone Joint Surg Br.* 2008;90(1):88-91.
<https://doi.org/10.1302/0301-620X.90B1.19674>
 19. Khobragade L and Vatsalawamy P. A study on morphometric measurement of volume of acetabulum. *Int J Anat Res.* 2014;2(3):549-552.

Authors Contribution:

MAS- Concept, design, literature survey, prepared first draft of manuscript, data collection, data analysis, manuscript preparation and submission of article.

RN- Concept, literature survey, manuscript revision. **SB-** Concept, design, literature survey, manuscript preparation, manuscript review. **GSS-** Manuscript revision.

Work attributed to:

Yenepoya Medical College, Mangaluru, Karanataka, India.

Orcid ID:

Dr. Meril Ann Soman - <https://orcid.org/0009-0001-9556-943X>

Dr. Rani Nallathamby - <https://orcid.org/0009-0007-4483-9405>

Dr. Shivarama Bhat - <https://orcid.org/0000-0001-8520-1968>

Dr. Godly Sara Sabu - <https://orcid.org/0009-0006-0849-1029>

Source of Support: Nil, **Conflicts of Interest:** None declared.