

Case of triple extradural hematoma in a single patient: A rare case report



Jolly Sinha¹, Avdhesh Shukla², Vivek Kumar Kankane³, Avinash Sharma⁴, Sutradhar Sridham⁵

^{1,5}Senior Resident, ^{2,4}Professor, ³Associate Professor, Department of Neurosurgery, Gajra Raja Medical College, Gwalior, Madhya Pradesh, India

Submission: 14-08-2023

Revision: 29-10-2023

Publication: 01-12-2023

ABSTRACT

Epidural hematoma (EDH) is found in 1–4% of traumatic brain injury cases. Acute triple extradural hematoma is a rare presentation of head trauma injury. In sporadic cases, they represent 0.5–1% of all extradural hematomas. Here is a case report of a 36-year-old female patient who presented to us with a head injury due to fall from a bike due to collision with a stray animal. The patient had a Glasgow Coma Scale of 9 (E2V2M5) with bilateral sluggishly reacting pupil to light. Computed tomography showed asymmetric bilateral posterior fossa EDHs along with an extradural hematoma in the right frontal region with multiple small contusions with mass effect. The surgical evacuation was performed first of the posterior fossa in the prone position and then right frontal hematoma evacuation in the supine position in the same sitting. The patient recovered well and was discharged on the 10th post-operative day with no neurological deficit. Early drainage of hematomas has been demonstrated to be an effective technique that soon decreases the intracranial pressure and promotes an efficient resolution to the neurological damage.

Key words: Triple extradural hematoma; Stray animal; Early drainage of haematomas

Access this article online

Website:

<http://nepjol.info/index.php/AJMS>

DOI: 10.3126/ajms.v14i12.57608

E-ISSN: 2091-0576

P-ISSN: 2467-9100

Copyright (c) 2023 Asian Journal of Medical Sciences



This work is licensed under a Creative Commons Attribution-NonCommercial 4.0 International License.

INTRODUCTION

Trauma is the leading cause of death among young people. Head injury is associated with at least 50% of the fatalities related to trauma.¹ One of the most important complications of head injury is intracranial hematomas, which occur in 25–45% of severe cases and 3–12% of moderate cases.² Although extradural hematomas (EDH) are uncommon (1–2% of all cases), their mortality rates range from 10% to 40%.^{1,3}

EDHs arise from injury to the MMA, or from its terminal arterial branches in about 55% of the patients, from the middle meningeal vein in 30% of cases, and from diploic veins or a torn dural venous sinus in the remaining 15% of cases.¹ Posterior fossa EDHs are rare in association

with other EDHs and represent about 4–7% of the cases of all EDHs. This rare condition is rapidly fatal because of limited space in the posterior cranial fossa.^{1,2} The ipsilateral occurrence of more than one EDH is uncommon.⁴

CASE PRESENTATION

A 36-year-old female was admitted to our center 2 h after a head injury due to fall from a bike after a collision with a stray animal. At the time of admission, the patient had a Glasgow Coma Scale (GCS) of 9 (E2V2M5) with bilateral normal size sluggishly reacting pupils. Her past medical history was unremarkable. A non-contrast computed tomography head was performed, which showed

Address for Correspondence:

Dr. Avdhesh Shukla, Professor, Department of Neurosurgery, Gajra Raja Medical College, Gwalior, Madhya Pradesh, India.
Mobile: +91-8318100530. **E-mail:** sinhajolly.gsvm@gmail.com

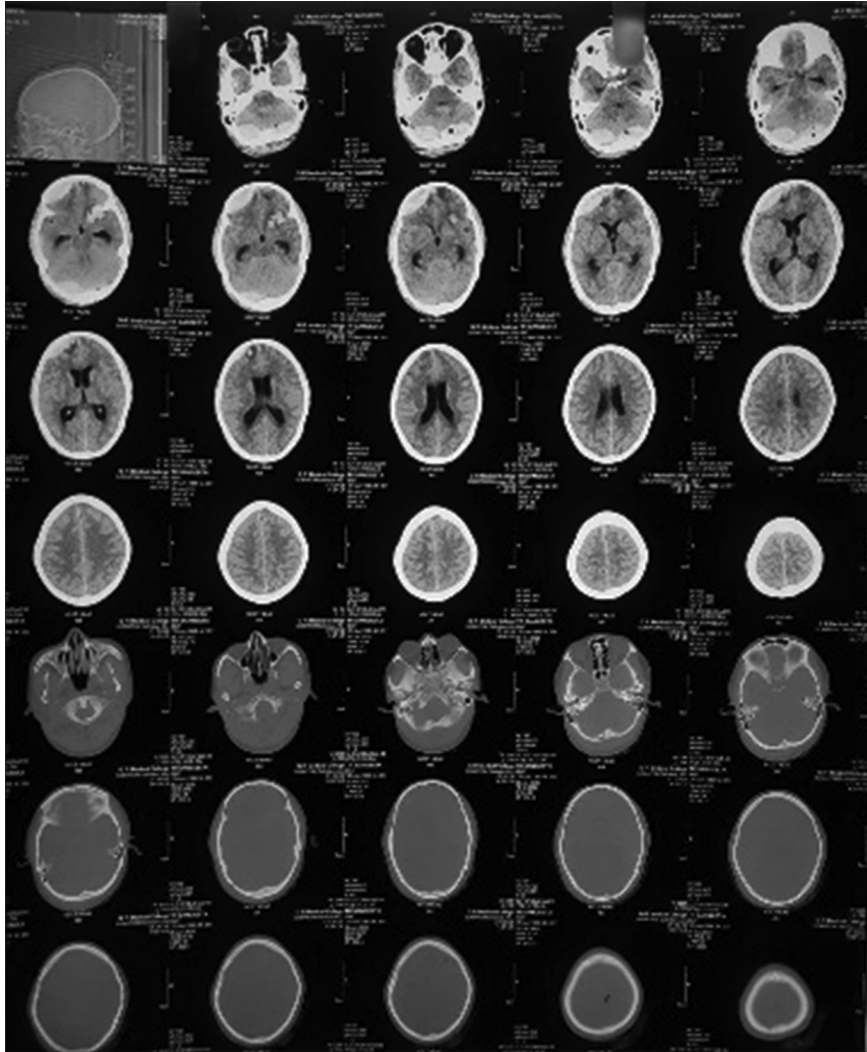


Figure 1: With bony and parenchymal window

asymmetric bilateral EDH in the posterior fossa with effacement of the 4th ventricle causing dilation of bilateral lateral ventricles and the third ventricle and a right frontal epidural hematoma with mass effect along with multiple small contusions scattered throughout the parenchyma, as shown in Figures 1 and 2.

Urgent surgical evacuation of the hematoma was carried out. First, the posterior fossa hematoma was evacuated in a prone position using a midline suboccipital incision up to C2, followed by evacuation of the right frontal hematoma using a right frontal hairline incision and trephine craniotomy. Initially, the patient was kept on mechanical ventilation and was later weaned off from it. The patient recovered well in the post-operative period and a post-operative scan was done on the 2nd day, which showed complete removal of the EDH, as shown in Figures 3 and 4. The patient was discharged on the 10th post-operative day with a GCS of E4V5M6 after suture removal with no neurological deficit.

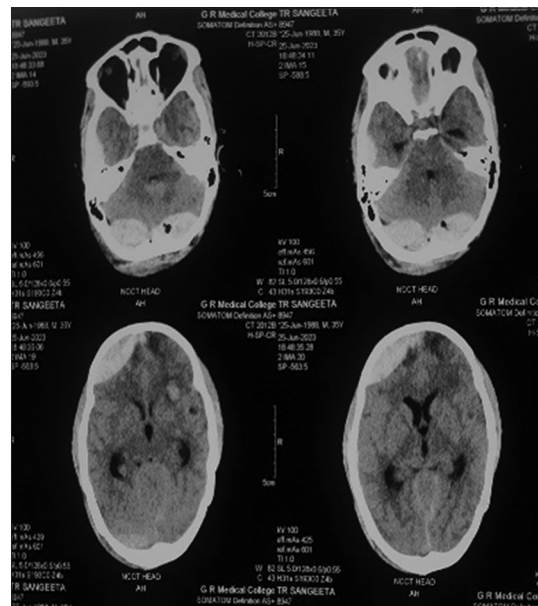


Figure 2: Pre-operative scan of the patient showing bilateral posterior fossa epidural hematoma (EDH) with right frontal EDH with multiple contusions

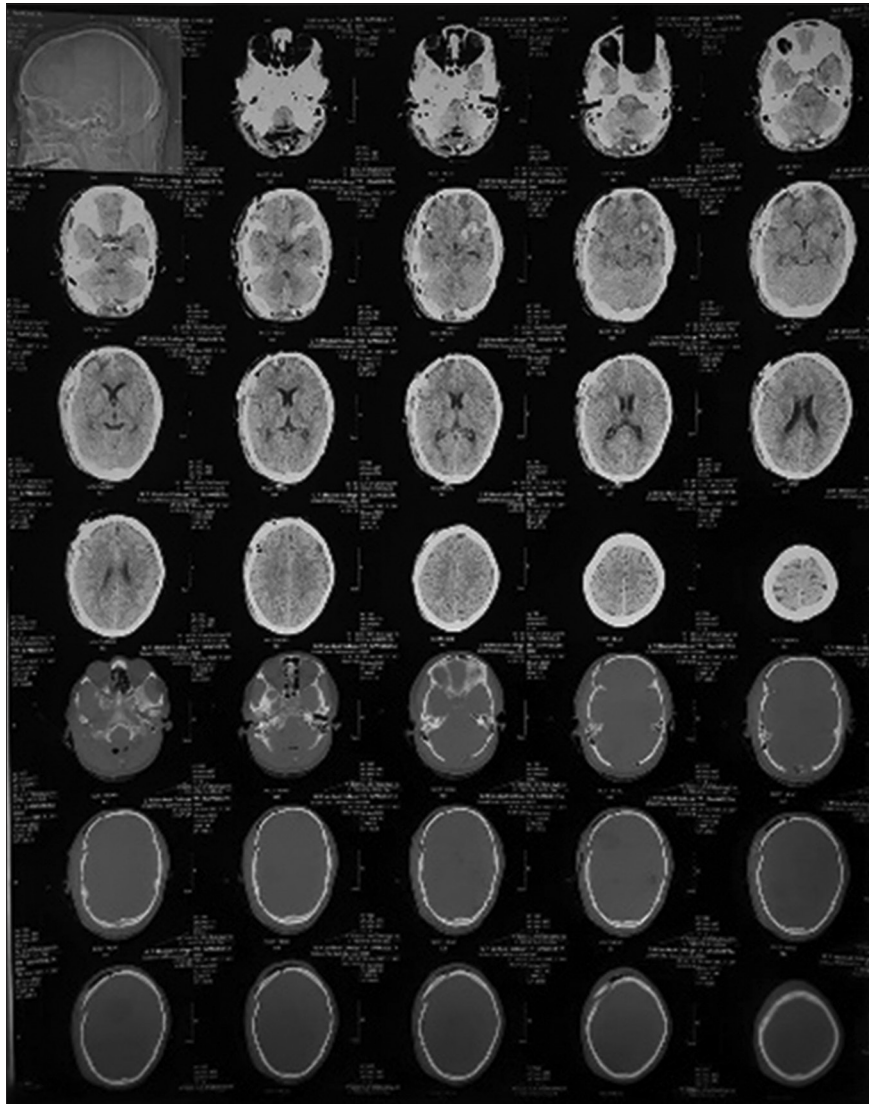


Figure 3: With bony and parenchymal window

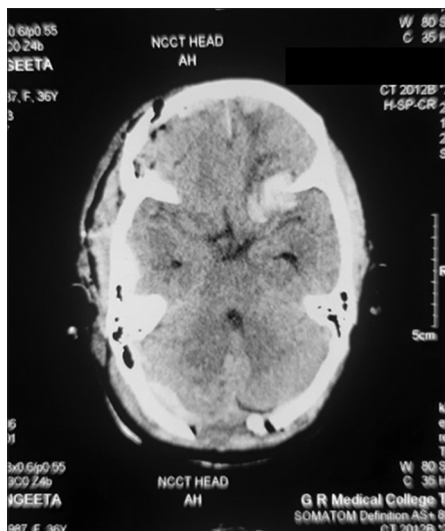


Figure 4: Post-operative scan of the patient showing epidural hematoma removal

DISCUSSION

Cases of triple EDH in a single patient are quite rare. The prognosis of such cases is very poor. It has been suggested that the force of impact on the head can produce such hematomas, particularly when the impact is predominantly more in an anteroposterior direction than from the lateral direction.⁵ Emergency and rapid decompression of the brain is of utmost importance.

According to Malik et al., the factors predicting outcomes are as follows:

- *Good prognostic factors:* Good GCS score, children, midline shift <5 mm, clot thickness <15 mm, and clot volume <10 mL.
- *Bad prognostic factors:* Sudden onset, associated intracranial injuries, acute hydrocephalus (effaced fourth ventricle and posterior cranial fossa cisterns).⁶

In this case, although according to Malik's prognosticating factors, the patient should have had a bad prognosis, due to timely intervention and surgical decompression, the patient had a good recovery in the post-operative period and was discharged successfully with a GCS score of 15/15 with no neurological deficits.

CONCLUSION

TSIEDH is a rare lesion constituting <2% of all EDHs. Clinical progress is silent and slow, but the deterioration is sudden and quick. It can be fatal if not promptly treated. Early diagnosis and timely surgical intervention could reduce the mortality and morbidity in TSIEDH.

REFERENCES

1. Pereira EL, Rodrigues DB, Lima LO, Sawada LA and Hermes MD Jr. Bilateral assymetric epidural hematoma. *Surg Neurol Int.* 2015;6:14. <https://doi.org/10.4103/2152-7806.150458>
2. Benedetto N, Gambacciani C, Montemurro N, Morganti R and Perrini P. Surgical management of acute subdural haematomas in elderly: Report of a single center experience. *Br J Neurosurg.* 2017;31(2):244-248. <https://doi.org/10.1080/02688697.2016.1244249>
3. Huda MF, Mohanty S, Sharma V, Tiwari Y, Choudhary A and Singh VP. Double extradural hematoma: An analysis of 46 cases. *Neurol India.* 2004;52(4):450-452.
4. Montemurro N, Santoro G, Marani W and Petrella G. Posttraumatic synchronous double acute epidural hematomas: Two craniotomies, single skin incision. *Surg Neurol Int.* 2020;11:435. https://doi.org/10.25259/SNI_697_2020
5. Agrawal A. Bilateral symmetrical parietal extradural hematoma. *J Surg Tech Case Rep.* 2011;3(1):34-36. <https://doi.org/10.4103/2006-8808.78469>
6. Malik NK, Makhdoomi R, Indira B, Shankar S and Sastry K. Posterior fossa extradural hematoma: Our experience and review of the literature. *Surg Neurol.* 2007;68(2):155-158. <https://doi.org/10.1016/j.surneu.2006.10.051>

Authors Contribution:

JS- Definition of intellectual content, literature survey, prepared the first draft of the manuscript, implementation of study protocol, data collection, data analysis, manuscript preparation and submission of an article; **VKK-** Concept, design, clinical protocol, manuscript preparation, editing and revision; **ShuA-** Review manuscript; **ShaA-** Coordination and manuscript revision.

Work attributed to:

Department of Neurosurgery, Gajra Raja Medical College, Gwalior, Madhya Pradesh, India.

Orcid ID:

Jolly Sinha- <https://orcid.org/0009-0004-4412-3691>
Vivek Kumar Kankane- <https://orcid.org/0000-0001-9068-7886>
Avdesh Shukla- <https://orcid.org/0000-0003-3583-8332>
Avinash Sharma- <https://orcid.org/0000-0002-2178-3070>
Sutradhar Sridham- <https://orcid.org/0000-0002-6173-4767>

Source of Support: Nil, **Conflicts of Interest:** None declared.