

Hepatosplenic fusion in a cadaver - An extremely rare variation



Anasuya Ghosh¹, Amit Kumar Pal²

¹Associate Professor, ²Assistant Professor, Department of Anatomy, All India Institute of Medical Sciences, Kalyani, West Bengal, India

Submission: 09-07-2022

Revision: 29-08-2023

Publication: 01-10-2023

ABSTRACT

Anatomical variations are observed at times during routine dissection processes or conduction of autopsies or may be found incidentally during radiological investigations. Fusion of the liver and spleen is an extremely rare condition that has been mentioned only a few times in the literature. "Beaver tail liver" is a variation of the liver where the left lobe of the liver is elongated and extends across the midline toward left hypochondrium of abdomen, often touching and encircling the spleen. Some of these cases may mimic hemorrhage and trauma within and around the spleen in ultrasound imaging or computed tomography scan. In certain cases, the liver and the spleen are difficult to distinguish due to their identical sonographic and radiological properties. Prior knowledge of such instances will help to interpret and manage such cases when encountered.

Key words: Liver; Spleen; Anatomic variation; Diagnostic imaging

Access this article online

Website:

<http://nepjol.info/index.php/AJMS>

DOI: 10.3126/ajms.v14i10.56467

E-ISSN: 2091-0576

P-ISSN: 2467-9100

Copyright (c) 2023 Asian Journal of Medical Sciences



This work is licensed under a Creative Commons Attribution-NonCommercial 4.0 International License.

INTRODUCTION

The liver is located mostly in the right hypochondrium of abdomen against the right 7–11 ribs, partly in the upper epigastrium, and small left part extending into the left hypochondrium crossing the midline. The spleen lies in left upper quadrant of abdomen occupying the lateral part of left hypochondrium and resting against the lower part of left ribcage (9–11 ribs).¹ Usually, the liver and spleen are completely separated from each other and there is no contact between them. The evidence of actual hepato-splenic fusion has been extremely rare in the literature.² Very few case reports have mentioned the existence of an elongated left hepatic lobe that either extended toward the left ribcage under the diaphragm and surrounded the spleen or made direct contact with spleen.^{3,4} Such appearance of liver is referred as "Beaver tail liver" due to its resemblance to the tail of a beaver

in a computed tomography (CT) imaging.⁵⁻¹¹ The reason for such fusion whether developmental or acquired is a matter of conjecture, however, in most cases, the asymptomatic presence and incidental uncovering indicates more toward the developmental origin.⁹⁻¹¹ We are presenting here one rare instance of complete hepato-splenic fusion encountered during routine abdomen dissection for the medical students. The main objective is to make the unsuspecting clinicians aware about this possibility.

CASE REPORT

A case of hepato-splenic fusion was found in a male cadaver aged about 78 years at the cadaver dissection laboratory, department of Anatomy, AIIMS, Kalyani during July 2022. It was an incidental finding during routine dissection for the 1st-year medical students. The ethical approval was obtained

Address for Correspondence:

Dr. Anasuya Ghosh, Associate Professor, Department of Anatomy, All India Institute of Medical Sciences, Kalyani - 741 245, West Bengal, India. **Mobile:** +91-6291329015. **E-mail:** anasuyag70@gmail.com

from the Institutional Ethics Committee, AIIMS, Kalyani (Ref no: IEC/AIIMS/Kalyani/Meeting/2023/010).

In the present case, the liver spanned from right to the left rib cage, the elongated left lobe along with the left triangular ligament was located against the left rib cage. The liver appeared normal and healthy. Initially, the spleen could not be located in the usual space as it was occupied by the elongated left lobe of the liver. Later, by tracing the branches of the splenic artery, it was seen that they were entering the lower aspect of the left lobe of the liver. Later, with minute observation, it was found that a small flattened, circumscribed, and relatively darker tissue mass, which resembled the spleen, was merged with the under surface of the elongated left hepatic lobe (Figure 1). They were inseparable from each other. The left triangular ligament was visible along the superior border of spleen. There were no signs of operative or traumatic scarring or pathological abnormalities on the neighboring thoracic wall.

On histological examination, it was seen that the capsules of liver and spleen were completely merged into a single common capsule. Normal histological appearance of liver and spleen was observed on each side of the capsule (Figure 2). The hepato-lienal fusion was also obvious in the macroscopic sagittal section along the line of fusion. No features of trauma, inflammation, or scarring were observed on any side. The appearance of liver and the histological findings support the developmental origin of the variation.

DISCUSSION

We present here a rare case of hepatosplenic fusion detected in a cadaver.

In available literature, only two cases have been reported previously where actual hepatosplenic fusion was validated by histological findings. In other cases, evidences of close approximation and contact were documented between liver and spleen by imaging studies, but whether that resulted actual hepato-splenic fusion, that has not been confirmed.

Cotelingam and Saito reported a case in which a tongue-like extension of hepatic parenchyma was found to be fused with the superolateral portion of the spleen found in an autopsy.³ Another case was reported in a forensic autopsy by Blakaj et al., where spleen completely fused with left lobe of liver.⁴ Our case resembled these cases, especially the second one. In both these cases and present case, blunt dissection was unable to separate this hepato-lienal union. On histological examination, both the hepatic and the splenic capsules were found to be merged completely.

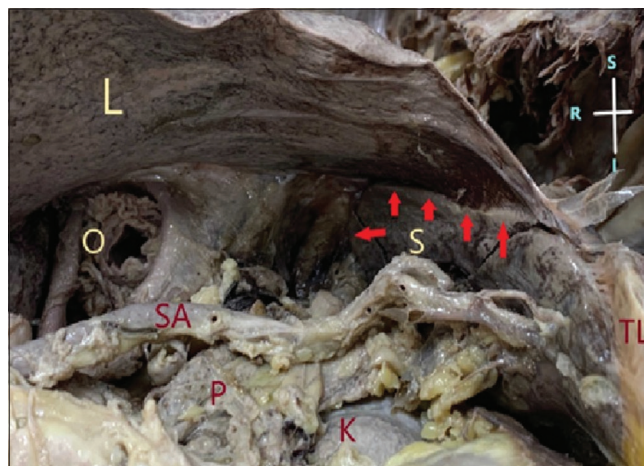


Figure 1: Hepatosplenic fusion along superior margin of spleen and elongated left hepatic lobe. L: Liver, S: Spleen, O: Oesophagus, SA: Splenic artery, P: Pancreas, K: Left kidney, TL: Left triangular ligament of liver. Red arrows – indicate line of fusion between liver and spleen

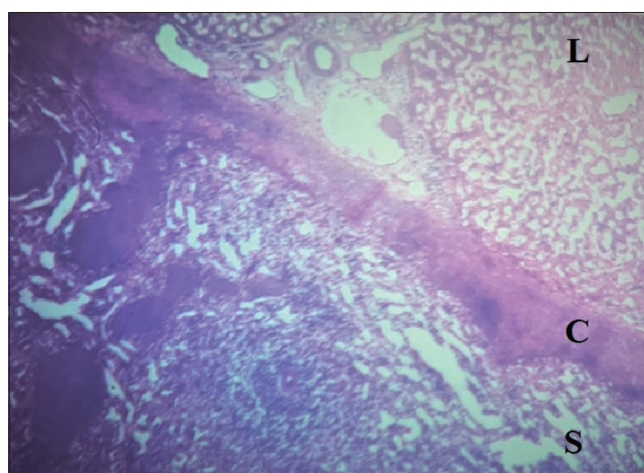


Figure 2: Histological appearance of hepatosplenic fusion. L: Liver, S: Spleen, C: Fused capsule

The tissue on either side of this fused capsule presented normal histological features. In the case reported by Blakaj et al., however, erythrocyte extravasates were detected in hepatic tissue. This could be due to accidental trauma of the patient whose autopsy was reported.

Jones et al.,⁵ presented a case where focused abdominal sonography in trauma imaging had mistaken an extended left lobe of the liver as a case of splenic subcapsular hematoma in a young female with a history of trauma in the left upper quadrant of abdomen. Later, CT scan report negated any acute traumatic injuries and it was found to be an elongated left lobe of the liver.

Some other authors supported the same view that enlarged left hepatic lobe if come in contact with the spleen and encircle it- the so called “Beaver tail Liver” cases – might suffer injury in cases of trauma to the upper left abdomen,

and might be misinterpreted as splenic subcapsular hematoma or peri splenic fluid accumulation.⁶

In situations of abdominal trauma, the liver, and spleen exhibit identical echogenicity on USG and density in CT, leading to difficulty in distinguishing between the two organs.⁷

Cholankeril et al., documented a case series where a CT scan diagnosed three cases as suspected peri splenic density at the initial impression.⁸ In the first case, exploratory laparotomy was done which revealed an elongated left hepatic lobe surrounding the spleen. In other two cases, after careful examination, the peri-splenic density was identified as extended left hepatic lobes.

Khanduri et al., reported a case where CT scan of the abdomen incidentally detected a “beaver tail liver” in a middle-aged man complaining of abdominal pain.⁹ Such incidental detection of “Beaver tail liver” were reported by two other authors in abdominal CT scans of patients presented with urinary complaints.^{10,11}

Hepato-lienal fusion might be of developmental or acquired. The fusion between the developing left hepatic lobe and the spleen can be explained by embryologic facts and events. The liver starts its development from a foregut endodermal diverticulum projecting into septum transversum around 4th week of embryonic life, whereas spleen develops within dorsal mesogastrium in multiple small segments around 5th week.¹² At certain phases, during rotation of stomach, the primordia of liver and spleen remain separated by some delicate connective tissue. The exact process of fusion between liver and spleen is not clear, but mild displacement of their primordia could have resulted fusion and subsequent growth of the organs and lateral rotation of spleen might have resulted the elongation of the left hepatic lobe.^{3,13}

CONCLUSION

Cases such as the present case might lead to mistaken diagnoses in emergency trauma cases – since they might mimic peri splenic hematoma or subcapsular hematoma of spleen – either in ultrasonography or in CT to the unsuspecting investigators. It could cause unforeseen complications if a splenectomy is planned in these cases due to any reason. Physicians need to be aware of these kinds of morphological variations. Knowledge of such kind of variations will help to avoid misdiagnoses, minimize unnecessary investigations and streamline surgical explorations.

ACKNOWLEDGMENT

We sincerely acknowledge all the faculty members and staffs of the department of anatomy, AIIMS, Kalyani for their help and support. Our sincere gratitude is expressed toward the cadaver donors without whom the study could not be possible.

REFERENCES

1. Moore KL, Dalley AF and Agur AM. Clinically Oriented Anatomy. 8th ed. Philadelphia, PA: Lippincott Williams and Wilkins; 2017.
2. Varga I, Galfiova P, Adamkov M, Danisovic L, Polak S, Kubikova E, et al. Congenital anomalies of the spleen from an embryological point of view. *Med Sci Monit.* 2009;15(12):RA269-RA276.
3. Cotelingam JD and Saito R. Hepatolienal fusion: Case report of an unusual lesion. *Hum Pathol.* 1978;9(2):234-236. [https://doi.org/10.1016/s0046-8177\(78\)80116-6](https://doi.org/10.1016/s0046-8177(78)80116-6)
4. Blakaj F, Haliti D, Kotori V and Hyseni V. Hepatolienal fusion combined with Eagle syndrome: A rare case report. *Forensic Sci Int Rep.* 2020;2:100087. <https://doi.org/10.1016/j.fsir.2020.100087>
5. Jones R, Tabbut M and Gramer D. Elongated left lobe of the liver mimicking a subcapsular hematoma of the spleen on the focused assessment with sonography for trauma exam. *Am J Emerg Med.* 2014;32(7):814.e3-e4. <https://doi.org/10.1016/j.ajem.2013.12.050>
6. Atalar MH and Karakus K. Beaver tail liver. *Abdom Radiol (NY).* 2018;43(7):1851-1852. <https://doi.org/10.1007/s00261-017-1395-x>
7. Xiang H, Han J, Ridley WE and Ridley LJ. Beaver tail liver: Anatomic variant. *J Med Imaging Radiat Oncol.* 2018;62 suppl 1:57. https://doi.org/10.1111/1754-9485.05_12784
8. Cholankeril JV, Zamora BO and Ketyer S. Left lobe of the liver draping around the spleen: A pitfall in computed tomography diagnosis of perisplenic hematoma. *J Comput Tomogr.* 1984;8(3):261-267. [https://doi.org/10.1016/0149-936x\(84\)90074-2](https://doi.org/10.1016/0149-936x(84)90074-2)
9. Khanduri S, Malik S, Khan N, Singh H and Rehman M. Beaver tail liver: A hepatic morphology variant. *Cureus.* 2021;13(7):e16327. <https://doi.org/10.7759/cureus.16327>
10. Narra R and Kamaraju SK. Beaver tail liver: A rare anatomical variant. *Indian J Case Rep.* 2020;6(10):604. <https://doi.org/10.32677/ijcr.2020.v06.i10.019>
11. Noh MS and Muhammad SS. Beaver in the liver. *Pan Afr Med J.* 2017;27:138. <https://doi.org/10.11604/pamj.2017.27.138.12227>
12. Moore KL, Persaud TV and Torchia MG. The Developing Human: Clinically Oriented Embryology. 10th ed. Amsterdam: Elsevier, E-book. p. 217-218. Available from: <https://www.academia.edu> [Last accessed on 2023 Mar 27].
13. Hamilton WJ and Mossman HW. Human Embryology. 4th ed. Baltimore: The Williams and Wilkins Company; 1972. p. 338-340.

Authors Contribution:

AG- Concept, literature survey, data collection, manuscript revision, preparation of figures, manuscript revision, and submission of article; **AKP-** Literature survey, first draft of manuscript preparation, and manuscript revision.

Work attributed to:

AIIMS, Kalyani, West Bengal - 741245, India.

Orcid ID:

Anasuya Ghosh - <https://orcid.org/0000-0001-9037-1611>

Amit Kumar Pal - <https://orcid.org/0000-0001-5407-9883>

Source of Support: Nil, **Conflicts of Interest:** None declared.