

Takotsubo cardiomyopathy complicating acute on chronic pancreatitis: A case report



Swaminathan Rajan¹, Sivasankar Amarapathy², Somasekar Durairajan³

¹Professor and Head, ²Senior Consultant and Head, ³Senior Assistant Professor, Department of Surgical Gastroenterology and Gastrointestinal Oncology, Government Mohan Kumaramangalam Medical College Hospital, Salem, Tamil Nadu, India

Submission: 29-05-2023

Revision: 30-08-2023

Publication: 01-10-2023

ABSTRACT

Acute or chronic pancreatitis as a trigger of Takotsubo cardiomyopathy (TCM) has been infrequently described in the literature. Misdiagnosis of this phenomenon can often occur due to overlap in symptomatology, particularly in those outside of the usual. A 50-year-old man with a history of alcohol abuse presented with epigastric and chest pain. Electrocardiography showed ischemic changes, and laboratory workup revealed elevated lipase, amylase, and troponin. He was diagnosed with acute pancreatitis and managed presumptively as acute coronary syndrome, class 4 angina. Patient had no signs of chronic liver disease, his pulmonary system was stable. He was a known case of left upper limb thrombosis and had portal venous thrombosis and was on tablet Rivaraxoban 10 mg. Subsequent coronary angiography was negative for obstructive coronary artery disease, and left ventriculography demonstrated basal hyperkinesis and apical akinesis, characteristic of TCM. TCM is a rare complication of acute pancreatitis. Increased awareness of this phenomenon is required to prevent delays in diagnosis and avoid unnecessary interventions and complications.

Key words: Ethanol related acute on chronic pancreatitis; Takotsubo cardiomyopathy

Access this article online

Website:

<http://nepjol.info/index.php/AJMS>

DOI: 10.3126/ajms.v14i10.55233

E-ISSN: 2091-0576

P-ISSN: 2467-9100

Copyright (c) 2023 Asian Journal of Medical Sciences



This work is licensed under a Creative Commons Attribution-NonCommercial 4.0 International License.

INTRODUCTION

Takotsubo cardiomyopathy (TCM) has increasingly gained international awareness since it was introduced in 1990. While there are many well-documented triggers of TCM, the role of acute pancreatitis has been only sporadically mentioned in the literature. Increasing awareness of this phenomenon particularly in those outside of the usual patient demographic may lead to earlier diagnosis and avoid unnecessary interventions. We present a rare case of TCM complicating ethanol-related acute on chronic pancreatitis.

CASE PRESENTATION

A 50-year-old man, with a history of smoking and chronic alcoholism and no other cardiac risk factors, developed chest pain with radiation to left shoulder,

epigastric pain associated with nausea, vomiting, and diaphoresis, following significant alcohol consumption the night prior. On presentation, he was tachycardic to 112 beats/min, epigastric tenderness was present. Pain was radiating to back and associated with nausea and vomiting. On examination of his abdomen, there was no distention or guarding and rigidity. His laboratory workup showed an elevated lipase of 221 U/L, leukocytosis of 13,300 Cell/Cu.mm, C-reactive protein of 54 mg/L, and liver functions and renal function was normal. Kidney function was maintained with a creatinine of 0.6 mg%. Chest radiography, when performed, showed features of acute pulmonary edema and electrocardiography (ECG) revealed ST elevation in the anterior leads (Figure 1). A provisional diagnosis of anterior ST-elevation myocardial infarction was made. Echocardiogram (Figure 2) was done showed hypokinesia of left ventricle in the distal 2/3rd of

Address for Correspondence:

Dr. Sivasankar Amarapathy, Senior Consultant and Head, Department of Surgical Gastroenterology and Gastrointestinal Oncology, Government Mohan Kumaramangalam Medical College Hospital, Salem, Tamil Nadu, India. **Mobile:** +91-9790018137. **E-mail:** drsivasankar2004@yahoo.com

interventricular septum, anterior wall of left ventricle, ejection fraction was 39% with moderate left ventricular systolic function.

Coronary angiography with ventriculography showed non-obstructive coronary artery disease and basal hyperkinesis with apical akinesis of the left ventricle (Figures 3 and 4). The final diagnosis of TCM was made. Dual antiplatelet therapy was ceased.

Contrast-enhanced computed tomography of the abdomen demonstrated an edematous pancreas with calcification, collection, diffuse peripancreatic fat stranding. The patient underwent USG-guided percutaneous drainage of the collection. Therefore, the patient was concurrently diagnosed with complicated acute on chronic pancreatitis with pancreatic fluid collection. He was managed conservatively with intravenous fluids and gradual diet upgrade. The patient's abdominal pain resolved after 2 weeks.

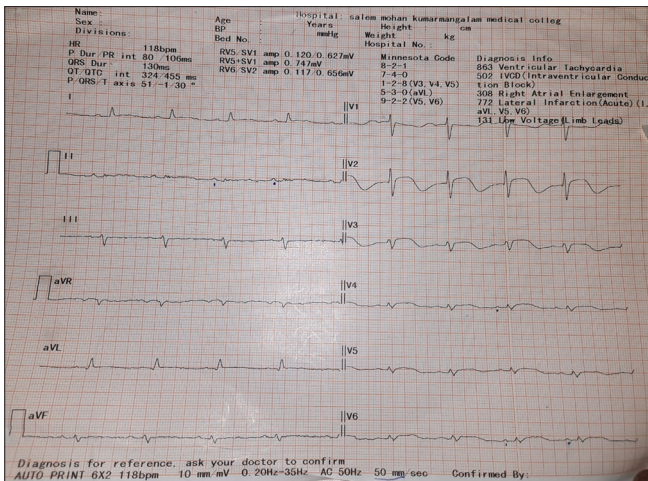


Figure 1: Electrocardiogram

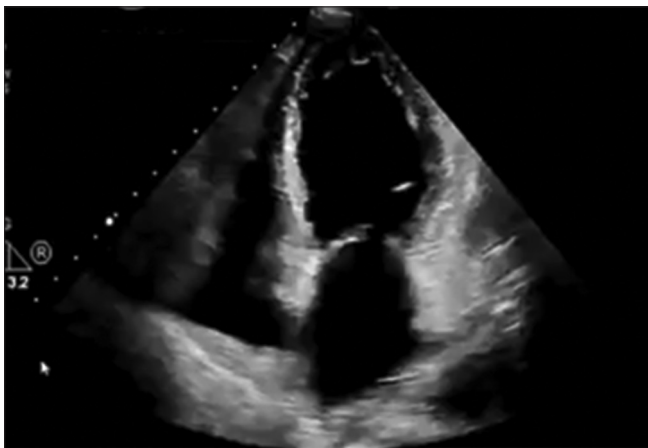


Figure 2: Echocardiography

DISCUSSION

TCM is characterized by transient left ventricular wall abnormality, resulting in apical¹ ballooning resembling an octopus trap, “takotsubo.” Most cases of TCM are associated with a preceding stressor, and¹³ sympathetic stimulation in the setting of increased catecholamines is widely accepted to be central to its pathogenesis. Classically, this association has been with emotional trauma — that is

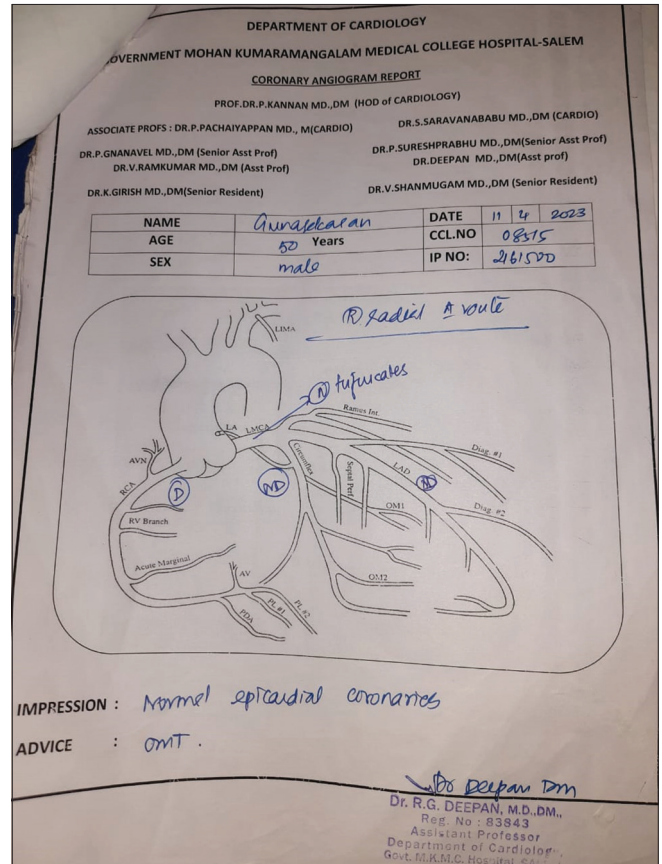


Figure 3: Coronary Angiogram

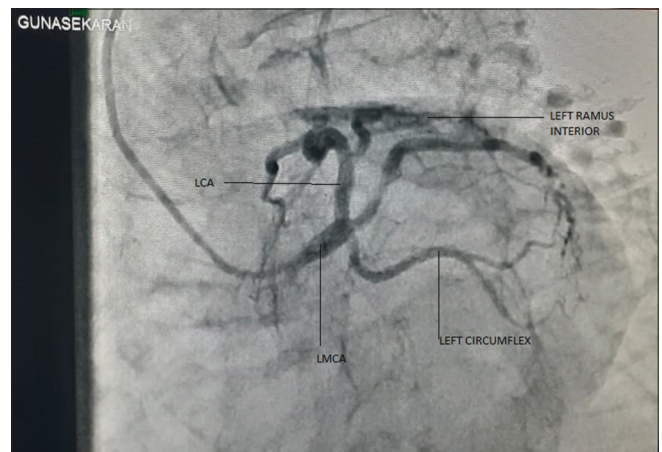


Figure 4: Left oblique anterior view

Table 1: Summary of literature reporting on pancreatitis-induced TCM

Authors	Sankri-Tarbichi et al. ²	Rajani et al. ⁷	Cheezum et al. ⁴	Pednekar and Chandra ⁶	Leubner et al. ⁸	Bruenjes et al. ¹⁰	Boulos ⁹	Garbowska et al. ¹²	Koop et al. ¹⁴	Abe et al. ¹⁵	Ashraf et al. ¹⁶	Current case
Age (years)	56	72	76	70	76	55	47	47	63	57	64	50
Sex	Female	Female	Female	Female	Female	Male	Female	Female	Male	Female	Female	Male
Etiology of pancreatitis	Gallstones	—	Gallstones	—	Gallstones	Alcohol	—	Alcohol	Gallstones	Alcohol	Unknown	Alcohol
Symptoms of pancreatitis	RUQ pain, nausea	Abdominal pain	N+V	RUQ pain	Epigastric pain, N+V	Epigastric pain, N+V	Epigastric pain	Epigastric pain, N+V	Epigastric pain, N+V	Abdominal pain, N+V	Epigastric pain, vomiting 5 days	Epigastric pain, N+V
Time to TCM	3 days	7 days	2 days	Same day	1 day	Same day	—	7 days	3 days	4 days	5 days	Same day
Systemic inflammation	—	—	WCC 23.3×10 ⁹ /L	—	Mild leukocytosis	—	—	WCC 19.52×10 ⁹ /L, CRP 293.8 mg/L	WCC 11.5×10 ⁹ /L	WCC 14.6×10 ⁹ /L	—	WCC 13.2×10 ⁹ /L
Symptoms of TCM	SOB, chest pain, nausea	Chest pain	Tachypnea, hypoxemic	Cardiac arrest	SOB, diaphoresis	Chest pain, diaphoresis, nausea	Nausea	Chest pain, SOB	Oliguria, hypotension, SOB, PEA arrest	SOB, hypoxemic	SOB	Chest pain
Troponin (ng/mL; reference < 0.02)	2.39	0.32	0.67	3.13	9.94	0.66	0.3	9.65	0.02	0.97	Elevated	1019.63
ECG	TWI V2-5	Inferolateral TWI	Lateral ST elevation	Inferior ST elevation, anterior TWI	Anteroseptal ST elevation	Generalised ST depression + TWI	Inferolateral TWI	ST elevation V2	Non-specific inferolateral T-wave changes	Diffuse ischemic TWI	Anterior ST elevation	Anterior ST elevation
Chest radiography	Pulmonary oedema	—	Pulmonary oedema, bilateral pleural effusions	—	Mild pulmonary oedema, bilateral pleural effusions	—	—	Pulmonary congestion	Acute pulmonary oedema	Pulmonary oedema	Pulmonary oedema	—
Echocardiogram or ventriculography	LVEF 25%, severe apical hypokinesia/akinesia of left ventricle, hypercontractile base	Apical akinesia	LVEF 30%, severe apical hypokinesia + hyperdynamic basal contraction	LVEF 30%	LVEF 30–35%, hypokinetic apical left ventricle	LVEF 25%, apical ballooning, hypercontractile basal segments	Akinesia of distal anterior, lateral, inferior walls of left ventricle	LVEF 25%, apical ballooning, hypercontractile basal segments of left ventricle	LVEF 20–25%, new-onset cardiomyopathy, global hypokinesia	LVEF 40%, basal segment hyperkinesia, apical akinesia	LVEF 30–35%, mid-to-apical segments hypokinetic to akinetic	LVEF 39% hypokinesia of left ventricle
Angiography	Normal coronary arteries	Unobstructed coronary arteries	Mild non-obstructive CAD	No obstructive atherosclerotic disease	No CAD	No obstructive CAD	Not done—myocardial nuclear stress test mildly abnormal	Normal coronary arteries	50% LAD stenosis, otherwise no obstructive CAD	Normal coronary arteries	Only luminal irregularities	Normal epicardial arteries
Treatment of TCM	Aspirin, BB, ACEi	BB, ACEi	BB, ACEi	BB, ACEi	—	Aspirin, BB, ACEi, warfarin	—	—	Left ventricular assist device	BB, ACEi	BB, ACEi	BB, ACEi
Recovery of LVEF	Yes	—	Yes	Yes	—	Yes	—	Yes	Yes	No	Yes	—
Time to recovery	10 days	—	2 weeks	6 weeks	—	3 weeks	—	10 days	3 weeks	—	6 weeks	—

TCM: Takotsubo cardiomyopathy; N+V: nausea and vomiting; WCC: White cell count; CRP: C-reactive protein; SOB: Shortness of breath; PEA: Pulseless electrical activity; TWI: T-wave inversion; LVEF: Left ventricle ejection fraction; CAD: Coronary artery disease; LAD: Left anterior descending; BB: Beta-blocker; ACEi: Angiotensin-converting enzyme inhibitor

the “broken heart”; however, physical stressors are in fact more common. These include various physical activities, procedures, drugs, and medical conditions ranging from sepsis to lightning strike. Modified Mayo Criteria is used to identify TCM. Other criteria used are Japanese guidelines 2007, Gothenburg criteria – Sweden 2012, John Hopkins criteria 2012, Madias criteria 2014.

Acute pancreatitis as a trigger of TCM is a rare phenomenon. Since it was first described in 2007, there have been only 11 total cases reported in the literature (Table 1). Of these, 9 were female, with ages ranging between 47 and 76 years and a median of 63 years, and 82% of cases above 50 years. The most common etiology for acute pancreatitis is gall stones and alcohol consumption. The etiology of pancreatitis reflects that typically seen in the community with alcohol and gallstones predominating. The timeframe for onset of pancreatitis symptoms to TCM was quite variable, ranging from hours to 7 days. Similarly, the markers of systemic inflammation were an unreliable predictor of the development of TCM or its complications, with leukocytosis ranging from mild to markedly elevated.

Recognizing TCM in the setting of pancreatitis is clinically difficult, TCM complicating pancreatitis results in considerable overlap in symptomology, and a patient's epigastric pain can easily mask or distract from chest pain. Formal diagnosis of TCM relies heavily on coronary angiography with left ventriculography.^{3,11} While multiple diagnostic criteria have been proposed, the most widely known is the Revised Mayo Clinic Criteria.¹¹ This requires the presence of transient left ventricular dysfunction, the absence of obstructive coronary artery disease, electrocardiographic abnormalities, or troponin elevation.

All previously reported cases of pancreatitis-induced TCM, and our own case, had elevated troponin, and ECG almost always demonstrated ST elevation or T-wave inversion. Chest radiography, when performed, showed features of acute pulmonary edema. Furthermore, almost all cases demonstrated left ventricular apical hypokinesis or akinesis, basal hyperkinesis, reduced ejection fraction, and normal or non-obstructive coronary arteries.¹⁴

Diagnostic challenge lies in the overlap of biochemical and ECG changes of TCM with those of acute coronary syndrome. Our presented case, like several others, was diagnosed presumptively as acute coronary syndrome. The patient underwent coronary angiogram which showed normal epicardial arteries, ruling out acute coronary syndrome.

However, in a center where primary percutaneous coronary intervention was available within 90 min, a diagnosis of

TCM could have been reached sooner, and the potential complications of thrombolysis could have been avoided. Interestingly, there may be a role in the stable patient for early echocardiogram and subsequent computed tomography coronary angiography to reach a diagnosis of TCM, thereby avoiding the vascular complications of cardiac catheterization.

CONCLUSION

The outcomes of TCM as a complication of pancreatitis appear to be good. There have been no reported deaths, even in the severe case of cardiac arrest ultimately requiring left ventricular assist device.

All patients, where treatments were described, were discharged on a beta-blocker and ACEi, and in those whose follow-up was reported, all but one had recovered left ventricular function, ranging from as early as 10 days up to 6 weeks. Abe et al.,¹⁵ reported the case of persistently reduced left ventricular function even at 4 months, which was hypothesized to be due to ongoing alcohol use.

Overall, TCM is a rare, and potentially under-recognized, complication of acute pancreatitis. In a scenario where delays in diagnosis can lead to unnecessary interventions and complications, increasing awareness of this phenomenon by surgeons and physicians alike is imperative.

REFERENCES

1. Sato H. Tako-tsubo-like left ventricular dysfunction due to multivessel coronary spasm. In: Kodama K, Haze K and Hori M, editors. *Clinical Aspect of Myocardial Injury: From Ischemia to Heart Failure*. Tokyo: Kagakuhyoronsha Publishing Co; 1990. p. 56-64.
2. Sankri-Tarbichi AG, Mathew PK, Matos M and His D. Stress-related cardiomyopathy. *Heart Lung*. 2007;36(1):43-46. <https://doi.org/10.1016/j.hrtlng.2006.05.007>
3. Prasad A, Lerman A and Rihal CS. Apical ballooning syndrome (Tako-Tsubo or stress cardiomyopathy): A mimic of acute myocardial infarction. *Am Heart J*. 2008;155(3):408-417. <https://doi.org/10.1016/j.ahj.2007.11.008>
4. Cheezum MK, Willis SL, Dufy SP, Moawad FJ, Horwhat JD, Hufer LL, et al. Broken pancreas, broken heart. *Am J Gastroenterol*. 2010;105(1):327-328. <https://doi.org/10.1038/ajg.2009.520>
5. Madhavan M and Prasad A. Proposed Mayo Clinic Criteria for the diagnosis of Tako-Tsubo cardiomyopathy and long-term prognosis. *Herz*. 2010;35(4):240-243. <https://doi.org/10.1007/s00059-010-3339-x>
6. Pednekar M and Chandra P. Sudden cardiac death from Takotsubo cardiomyopathy triggered by acute pancreatitis. *J Hosp Med*. 2010;5(Suppl 1). Available from: <https://shabstracts.org/abstract/sudden-cardiac-death-from-takotsubo-cardiomyopathy-triggered-by-acute-pancreatitis> [Last accessed on 2023 Jul 17].

7. Rajani R, Przedlacka A, Saha M and de Belder A. Pancreatitis and the broken heart. *Eur J Emerg Med.* 2010;17(1):27-29. <https://doi.org/10.1097/MEJ.0b013e32832cf70d>
8. Leubner JK, Ortiz Z, Wolfrey J and Drake L. Can gallstones break the heart? Pancreatitis-induced Takotsubo cardiomyopathy mimicking acute myocardial infarction. *J Am Geriatr Soc.* 2014;62(9):1814-1815. <https://doi.org/10.1111/jgs.12999>
9. Boulos P. An infamed pancreas and a broken heart: Pancreatitis-induced Takotsubo cardiomyopathy. *J Hosp Med.* 2015;10:A349.
10. Bruenjes JD, Vallabhajosyula S, Vacek CJ and Fixley JE. Acute pancreatitis induced Takotsubo cardiomyopathy in an African American Male. *ACG Case Rep J.* 2015;3(1):53-56. <https://doi.org/10.14309/crj.2015.99>
11. Chew DP, Scott IA, Cullen L, French JK, Brifa TG, Tideman PA, et al. National Heart Foundation of Australia & Cardiac Society of Australia and New Zealand: Australian clinical guidelines for the management of acute coronary syndromes 2016. *Heart Lung Circ.* 2016;25(9):895-951. <https://doi.org/10.1016/j.hlc.2016.06.789>
12. Garbowska M, Kurek K and Sobkowicz B. Takotsubo cardiomyopathy resulting from exacerbation of chronic pancreatitis. *Folia Cardiol* 2016;11(5):473-476.
13. Ghadri JR, Wittstein IS, Prasad A, Sharkey S, Dote K, Akashi YJ, et al. International expert consensus document on takotsubo syndrome (Part I): Clinical characteristics, diagnostic criteria, and pathophysiology. *Eur Heart J.* 2018;39(22):2032-2046. <https://doi.org/10.1093/eurheartj/ehy076>
14. Koop AH, Bailey RE and Lowman PE. Acute pancreatitis-induced Takotsubo cardiomyopathy and cardiogenic shock treated with a percutaneous left ventricular assist device. *BMJ Case Rep.* 2018;2018:bcr2018225877. <https://doi.org/10.1136/bcr-2018-225877>
15. Abe T, Simien M and Dolphurs H. Acute pancreatitis complicated by stress cardiomyopathy with persistent apical akinesis: A case report and literature review. *J Investig Med High Impact Case Rep.* 2019;7. <https://doi.org/10.1177/2324709619893197>
16. Ashraf S, Lam K and Hu G. When your pancreas breaks your heart: A case of pancreatitis induced Takotsubo cardiomyopathy. *Am J Respir Crit Care Med.* 2019;199:A3568.

Author's Contribution:

SR- Manuscript preparation, concept, and design; **SA-** Review of manuscript and treating surgical gastroenterologist, concept design; **SD-** Review of manuscript and treating gastroenterologist.

Work attributed to:

Government Mohan Kumaramanhalam Medical College Hospital, Salem - 636 001, Tamil Nadu, India.

Orcid ID:

Swaminathan Rajan - <https://orcid.org/0009-0009-2117-5719>

Sivasankar Amarapathy - <https://orcid.org/0009-0009-3871-3245>

Somasekar Durairajan - <https://orcid.org/0009-0009-8366-4075>

Source of Support: Nil, **Conflicts of Interest:** None declared.