

Computed tomography versus ultrasonography in the evaluation of periumbilical abdominal pain



Rachna Chaurasia¹, Vishal Gupta², Mohd. Abubakar³

¹Professor, ^{2,3}Junior Resident, Department of Radio-diagnosis, Maharani Laxmi Bai Medical College, Jhansi, Uttar Pradesh, India

Submission: 19-05-2023

Revision: 27-07-2023

Publication: 01-09-2023

ABSTRACT

Background: The objective of this study was to study, assess, and make early diagnosis of periumbilical pain abdomen accurately. **Aims and Objectives:** To study, assess, and diagnose causes of periumbilical abdominal pain accurately so as to minimize the unnecessary exploratory laparotomy and operations and consequently improved patient care and to compare the role of ultrasonography (USG) and computed tomography (CT) in the evaluation of various causes of periumbilical abdominal pain. **Materials and Methods:** This prospective study (CTRI/2023/01/048809) was done on 315 patients with periumbilical pain at M.L.B. Medical College Jhansi, Uttar Pradesh on PHILIPS 16 Slice multi-detector CT SCAN machine and GE Vivid T8 ultrasound machine. These patients were blindly and randomly divided by chit system into two groups irrespective of their age and gender. The first group of patients which included 160 patients undergoes ultrasonographic evaluation and the other group of patients which includes 155 patients undergoes contrast-enhanced computed tomographic evaluation. **Results:** Among 315 patients, the most common cause of periumbilical pain was found to be appendicitis followed by bowel pathologies which include gastrointestinal tuberculosis. **Conclusion:** USG is the initial modality and modality of choice in female and young (3rd and 4th decade) patients presenting with periumbilical pain as it is diagnostic in gynecological causes of periumbilical pain and also minimizes unnecessary radiation exposure to female and young patients. Contrast-enhanced CT is the modality of choice in male and old age patients (5th and 6th decade) as it is diagnostic in vascular causes. Overall plain CT has limited role.

Key words: Ultrasound; Appendicitis; Computed tomography

INTRODUCTION

The periumbilical region is the area that surrounds the umbilicus, and it is one of the nine regions according to the region classification of the abdomen.¹ Periumbilical pain occurs in the area surrounding and including the umbilicus. The causes of periumbilical pain can range from mild discomforts to surgical emergencies. This can be due to a number of reasons, ranging from an insignificant disease to a life-threatening disease. The use of conventional radiography has only a limited role, mainly in the setting of bowel obstruction and bowel perforation. However, ultrasonography (USG)

and computed tomography (CT) are more accurate and informative.

USG is the first investigation of choice in cases of periumbilical pain. It has diagnostic capability in evaluating causes related to the uterus, ovaries, adnexa, gallbladder, and high-resolution USG is helpful in the evaluation of the bowel and appendix if the patient is lean and has a nongaseous abdomen.

Although multidetector CT (MDCT), especially CECT, is the primary modality for vascular causes and a secondary modality in the evaluation of the gut, mesentery, omentum,

Access this article online

Website:

<http://nepjol.info/index.php/AJMS>

DOI: 10.3126/ajms.v14i9.55018

E-ISSN: 2091-0576

P-ISSN: 2467-9100

Copyright (c) 2023 Asian Journal of Medical Sciences



This work is licensed under a Creative Commons Attribution-NonCommercial 4.0 International License.

Address for Correspondence:

Vishal Gupta, Junior Resident, Department of Radio-diagnosis, Maharani Laxmi Bai Medical College, Jhansi - 284 128, Uttar Pradesh, India. **Mobile:** +91-8003825213. **E-mail:** v.gupta2718524@gmail.com

peritoneum, and retroperitoneum, it is unaffected by the presence of bowel gas and fat.

Aims and objectives

The objectives of this study were as follows:

- To study, assess, and diagnose causes of periumbilical abdominal pain accurately so as to minimize the unnecessary exploratory laparotomy and operations and consequently improved patient care
- To compare the role of USG and CT in the evaluation of various causes periumbilical abdominal pain.

MATERIALS AND METHODS

After written permission, certification, and approval from the ethical committee, the study was conducted in the Radiodiagnosis Department of MLB Medical College Jhansi, Uttar Pradesh (Bundelkhand area) on a Philips 16-slice MDCT Scan machine, a MedisonsonoACE 00d78, and a GE Vivid T8 ultrasonic machine.

This prospective study was done on 315 randomly collected patients who were referred to the radiology department with the documentation of periumbilical abdominal pain from the Emergency, Surgery, Medicine, and Gynecology departments for USG and CT.

Inclusion criteria

- All consenting patients between age group of 20–60 years with symptoms and signs of periumbilical abdominal pain.

Exclusion criteria

- Patients not willing to participate in the study
- Patients under the age of 20 and more than 60 years
- Previous abdominal surgery within 4 weeks
- Abdominal trauma
- Allergy to iodinated contrast media
- Severe renal insufficiency
- Pregnancy.

Methods

The total number of patients included in our study was 315, satisfying our inclusion criteria. These patients were blindly and randomly divided by the chit system into two groups, irrespective of their age and gender.

The first group of patients which included 160 patients undergoes.

Ultrasonographic evaluation, and the other group of patients, which includes 155 patients, undergoes contrast-enhanced computed tomographic evaluation.

The patients who are normal or nondiagnostic on one modality are switched to the other modality for further evaluation.

These patients are then followed up to look for their management part, which was either surgical or medical. A few of the patients who were normal on both modalities but had persistent clinical symptoms have finally undergone an invasive diagnostic procedure for a final diagnosis.

RESULTS

Among 315 patients, the most common cause of periumbilical pain was found to be appendicitis followed by bowel pathologies which include gastrointestinal tuberculosis.

There is a significant difference between USG and CECT abdomen according to gender, USG being more diagnostic in female patients, and CECT is more diagnostic in male patients.

USG is more diagnostic in 3rd and 4th decade and CECT abdomen is more diagnostic in 5th and 6th decades.

DISCUSSION

In our study, USG and contrast-enhanced CT were the primary modalities used, and a few patients who were nondiagnostic or normal on one modality switched to other modalities.

Out of the 315 patients satisfying the inclusion criteria recruited into this study, the maximum number of patients with periumbilical pain belong to the 4th decade with a mean age of 37.4, which is similar to the study conducted by Laal and Mardanloo (2009).²

We observed that, out of 315 patients, 158 were males (50.15%) and 157 were females (49.84%), which is consistent with the various similar studies conducted worldwide with a male preponderance, such as Al-Mulhim AA et al., (2006)³ and Asefa (2002).⁴

Furthermore, the majority of patients presenting with periumbilical pain have associated symptoms of nausea and vomiting, constituting statistically significant 38% and fever, 34%, and most common signs were tenderness (43%), followed by guarding and rigidity, constituting 12% and 6%, respectively, which is similar to the study conducted by Ghalige et al. (2021).⁵

In our study, the most common region of pain is the periumbilical region, satisfying our inclusion

criteria, followed by the right iliac fossa region, which is in agreement with the study conducted by Chanana et al. (2015).⁶

Etiology of periumbilical pain

In our study, the main purpose was to evaluate the cases with periumbilical pain on USG or CECT abdomen and to find out the causes of periumbilical pain so as to aid the patient's management as soon as possible. The distribution of causes is listed in Table 1.

The most common cause of periumbilical pain was appendicular pathologies, which included both complicated and uncomplicated pathologies and were found in 129 cases (Figures 1-3), followed by bowel causes in 80 cases (Figure 4) and mesenteric lymphadenitis in 20 cases (Figure 5).

This is consistent with the study by Pickuth et al. (2000)⁷ In the study of 120 patients, 93 patients had appendicitis, the most common cause of periumbilical pain.

The causes of periumbilical pain are divided into appendicular and non-appendicular pathologies, the most common being appendicitis. Non-appendicular pathologies are further divided into bowel and non-bowel pathologies.

Among the bowel causes, the most common single cause in our study is gastrointestinal tuberculosis, which accounts for 21 cases. The non-infective bowel causes are further divided into mechanical or non-mechanical causes.

Among the non-bowel causes of periumbilical pain, most of the cases are inflammatory in nature, with the

Table 1: Pathologies detected according to etiology USG and CECT ABD distribution

Pathology	Total-315	USG-121	CECT to USG-18	USG to CECT- 39	CECT-137
Appendicitis	116	47	2	6	61
Ruptured appendicitis	9	4	0	0	5
Appendicular abscess	3	1	0	0	2
Mucocele of appendix	1	0	0	0	1
Acute edematous pancreatitis	10	4	0	4	2
Acute necrotizing pancreatitis	5	0	0	2	3
Pancreatic pseudocyst	5	3	0	0	2
Distal jejunal obstruction	9	4	0	0	5
Small bowel obstruction due to ileal stricture	05	2	0	0	3
Volvulus	2	1	0	0	1
Ileocolic intussusception	3	1	0	0	2
Diverticulitis	4	0	0	2	2
Duodenal diverticula	1	0	0	1	0
Focal panniculitis	6	1	0	2	3
Gastro-intestinal tuberculosis	23	12	2	0	9
Gut malrotation without obstruction	4	2	0	0	2
Inflammatory bowel disease	6	2	0	1	3
Irritable bowel syndrome	6	0	3	3	
SMA thrombosis with bowel ischemia	3	0	0	2	1
Retroperitoneal collection with omental infarct	1	0	0	0	1
Median arcuate ligament syndrome	3	0	0	2	1
Mesenteric cyst	8	5	0	0	3
Mesenteric lymphadenitis	20	12	3	0	5
Paraumbilical hernia	10	6	0	0	4
Typhlitis	8	4	0	0	4
Neoplastic etiology involving duodenum	2	0	0	0	2
Adenocarcinoma of colon	4	2	0	0	2
GIST of terminal ileum	1	0	0	0	1
Small bowel lymphoma	2	1	0	0	1
Ovarian neoplasm	3	1	0	0	2
Hemorrhagic ovarian cyst	2	2	0	0	0
Ovarian torsion	2	1	0	0	1
Scar endometriosis	4	3	0	0	1
Hiatus hernia	6	0	0	4	2
Gastritis	6	0	3	3	0
Colitis	4	0	0	4	0
Mittelschmerz syndrome	3	0	0	3	0
Cholelithiasis	3	0	3	0	0
Choledocholithiasis	2	0	2	0	0
Total	315	121	18	39	137

USG: Ultrasonography

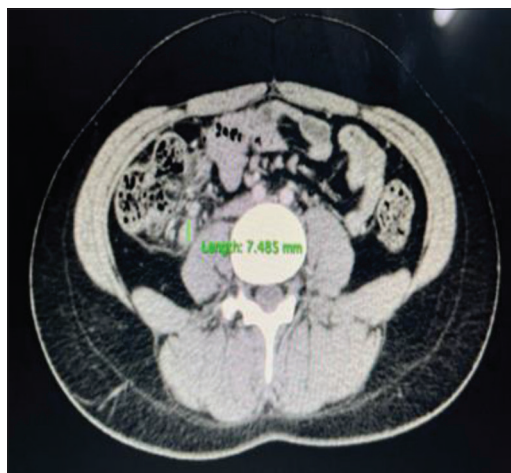


Figure 1: Appendicitis - Axial CECT scan shows a dilated blind-ended tubular structure is noted arising from the base of cecum with mild surrounding fat stranding in patient with periumbilical pain

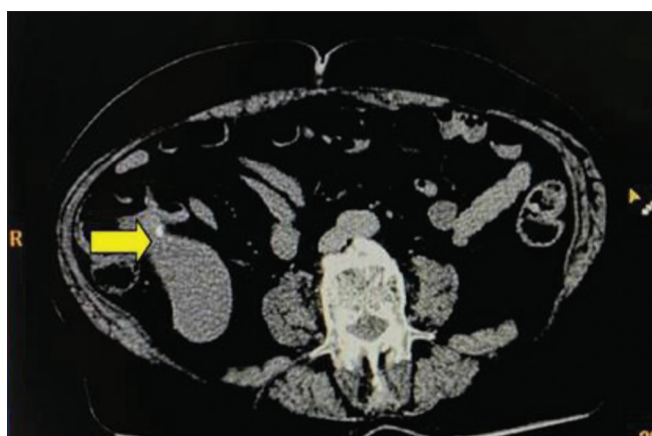


Figure 2: Mucocele of Appendix: Axial CT image showing well-circumscribed, hypodense, dilated, tubular structure in the right iliac fossa, contiguous with the base of the caecum. A calcific focus is seen in its wall. No periappendiceal fluid or fat stranding is evident

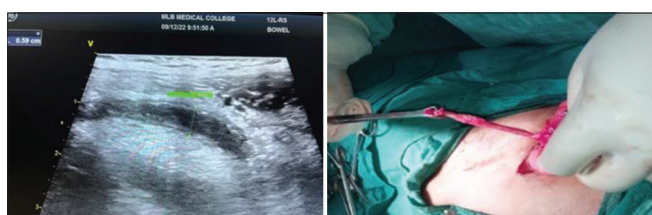


Figure 3: Acute appendicitis: High-resolution ultrasound image of dilated appendix with thickened wall on the right side and intra-operative image of the same patient

most common being pancreatitis and its complications, mesenteric lymphadenitis, and panniculitis.

The non-inflammatory causes are further divided into five subgroups. Parietal wall defect, vascular, chemical, gynecological, and neoplastic causes; out of them, the most common is gynecological causes.

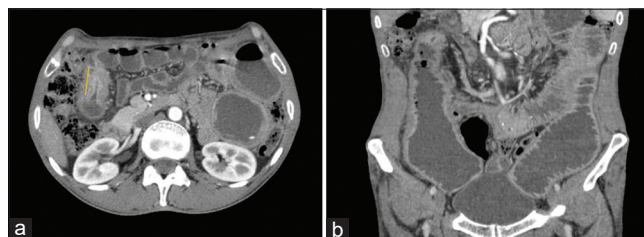


Figure 4: Distal ileal stricture: Axial (a) and coronal (b) CECT images showing a small segment distal ileal stricture causing dilatation of proximal ileal loops with air-fluid levels suggestive of distal ileal stricture with obstruction

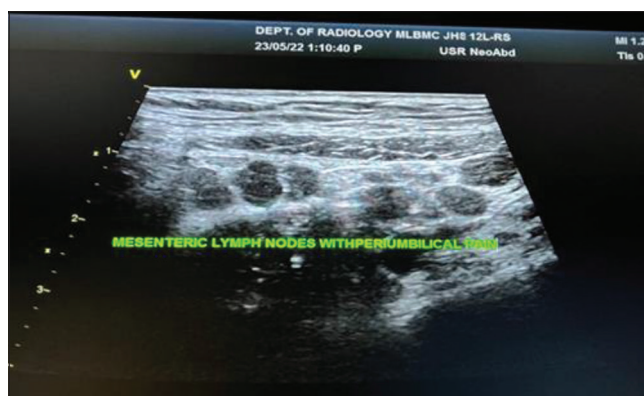

Figure 5: Mesenteric lymphadenitis: High-resolution ultrasound image showing multiple variables sized enlarged mesenteric lymph nodes

Pattern of study and results with age and sex distribution

Out of 315 patients, 160 undergo USG evaluation and 155 undergo CECT abdomen evaluation. Out of which USG was able to make a diagnosis in 121 patients and CECT abdomen was able to make a diagnosis in 137 patients.

The remaining 39 and 18 cases are switched to other modalities for evaluation. Out of 39 patients who were transferred from USG to CECT, CECT was able to make a diagnosis in 26 patients, and out of 18 patients who were transferred from CECT to USG, USG was able to make a diagnosis in 12 patients.

Out of a total of 178 patients undergoing ultrasound evaluation, USG was able to diagnose 133 patients (121 patients primarily and 12 patients switched from CECT), and out of 194 patients undergoing CECT evaluation, CECT was able to make a diagnosis in 163 patients (137 patients primarily and 26 patients switched from USG). The remaining 19 patients are followed up to look for their clinical diagnosis or intervention.

In our study, out of a total of 133 diagnosed cases of periumbilical pain on USG, most of the cases were female (57.14%), and males comprised 42.85%, as shown in Table 2. This signifies that ultrasound is better for female patients presenting with periumbilical pain, as ultrasound

is more helpful in detecting gynecological causes of periumbilical pain.

On the contrary, out of the total 163 patients diagnosed on CECT, most are male (53.9%), and females constitute 46.01%, as shown in Table 2. This signifies that CECT is more diagnostic in male patients presenting with periumbilical pain as it underestimates gynecological causes.

In our study, out of a total of 133 diagnosed cases of periumbilical pain on USG, most of the cases are in the age group of 20–40 years, as shown in Table 3. This signifies that ultrasound is better for young patients presenting with periumbilical pain. This also indicates that young patients do not require unnecessary radiation exposure and also avoid unnecessary burdens on patients because of their cost.

On the contrary, out of the total of 163 patients diagnosed on CECT, most of the cases are of the age group 40–60 years (middle and old age), as shown in Table 3. This signifies that CECT is more diagnostic in higher age groups presenting with periumbilical pain.

Mazzei et al.⁸ (critical ultrasound journal 2013) state that today, surely, integrated imaging, and in particular the use of MDCT, has revolutionized the clinical approach to this condition, simplifying the diagnosis but burdening the radiologists with problems related to the clinical management. However, although CT is emerging as a modality of choice for the evaluation of the acute abdomen, US remains the primary imaging technique in the majority of cases, especially in young and female patients, when the limitation of radiation exposure should be mandatory, limiting the use of CT in cases of non-diagnostic US, and in all cases where there is a discrepancy between the clinical symptoms and negative imaging at US.

In our study, out of 39 cases that were not diagnosed primarily on USG and needed CECT evaluation, CECT diagnoses 26 out of 39 cases, which include vascular causes such as median arcuate ligament syndrome as shown in Figure 6 and SMA thrombosis, inflammatory causes such as panniculitis, pancreatitis, appendicitis, and diverticulitis and chemical causes such as hiatus hernia.

Gunduz et al. (2012)⁹ stated that abdominal CT is the most sensitive modality for detecting mesenteric panniculitis.

Horton et al.¹⁰ stated that CT angiography plays a role in the diagnosis of median arcuate ligament syndrome.

In our study, out of 178 patients undergoing ultrasound for the evaluation of periumbilical pain (160 patients primarily and 18 patients secondarily), ultrasound was diagnostic in 133 patients with a diagnostic accuracy of 74.71% as shown in Table 4.

In our study, out of 194 patients undergoing CECT abdomen for the evaluation of periumbilical pain (155 patients primarily and 39 patients secondarily), CECT abdomen was diagnostic in 163 patients with a diagnostic accuracy of 84.02%, as shown in Table 5.

This implies a significant difference between USG and CECT abdomen in diagnosing cases of periumbilical pain since many factors affect USG evaluation of patients, such as obesity, bowel gases, patient compliance, and the experience of the radiologist, and CECT abdomen also has a lower false negative rate compared to USG.

However, USG is the preferred modality in female and young patients considering the radiation hazards associated with contrast-enhanced CT, and therefore it is the preferred modality in males and middle- and old-age patients. Similar

Table 2: Distribution of patients diagnosed according to gender on diagnostic modality

Modality	Male	Female	Total diagnosed cases (total-296)	P-value (Chi-square)
USG	57	76	133	0.04
CECT	89	74	163	

USG: Ultrasonography

Table 3: Distribution of patients diagnosed according to age on diagnostic modality

Age group (years)	Total-133 patients diagnosed on USG	Total-163 patients diagnosed on CECT abdomen	P-value (Chi-square)
20–30	34	26	0.002
31–40	56	50	
41–50	29	66	
51–60	14	21	
Total = 296	133	163	

Table 4: Summary of total patients diagnosed on USG with diagnostic percentage/sensitivity

Modality used	Total frequency	Diagnosis made	Diagnostic percentage/sensitivity
Ultrasonography	160	121	75.62
CECT-USG	18	12	66.66
Total	178	133	74.71

Table 5: Summary of total patients diagnosed on CECT abdomen with diagnostic percentage/sensitivity

Modality used	Total frequency	Diagnosis made	Diagnostic percentage/sensitivity
CECT	155	137	88.38
USG-CECT	39	26	66.66
Total	194	163	84.02

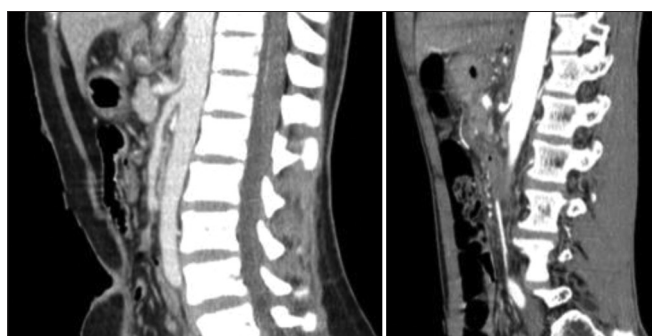


Figure 6: Median arcuate ligament syndrome: Sagittal CECT images in arterial phase show focal narrowing at the celiac trunk ostium by the fibrous band (making up the median arcuate ligament) which is clearly compressing it from above giving a “J-” shaped or “Hooked” configuration with post stenotic dilatation. The rest of the celiac artery and its branches showed good distal opacification and caliber

results were also observed by Mazzei et al.⁸ (Critical Ultrasound Journal 2013) and Pickuth et al.,⁷ (2000).

Limitations of the study

This was a single-centered study.

CONCLUSION

This was a prospective study done to compare the role of “CT Versus USG in Evaluation of Periumbilical Abdominal Pain” patients. The study includes a total of 315 patients from the Bundelkhand region (North India) between 20 and 60 years of age.

In our comparative study, we concluded the following points:

1. USG is the initial modality and modality of choice in female and young (3rd and 4th decade) patients presenting with periumbilical pain, as it is helpful in ruling out gynecological causes of periumbilical pain and also minimizes unnecessary radiation exposure in female and young patients
2. Contrast-enhanced CT is the modality of choice in male and elderly patients (5th and 6th decade)

3. Overall, CECT abdomen is better than USG as it is a cross-sectional modality, has a lower false negative rate, is not affected by bowel gases, is helpful in obese and non-compliant patients, and is also helpful in delineating vascular anatomy in detail
4. In periumbilical pain, non-contrast CT has a fantastic role in the diagnosis of panniculitis, and CECT abdomen is the diagnostic modality of choice for vascular causes of periumbilical abdominal pain
5. Overall, non-contrast CT has a limited role in diagnosing causes of abdominal pain, such as renal and ureteric calculi, trauma, and pneumoperitoneum, and CECT abdomen is the overall investigation of choice.

ACKNOWLEDGMENT

The authors would like to thank the Department of Radiodiagnosis, Maharani Laxmi Bai Medical College, Jhansi, Uttar Pradesh.

REFERENCES

1. Bailey and Love's Short Practice of Surgery. 27th ed. Boca Raton: CRC Press; 2018.
<https://doi.org/10.1201/9781315111087>
2. Laal M and Mardanloo A. Acute abdomen; Pre and post-laparotomy diagnosis. Int J Collab Res Intern Med Public Health. 2009;1(5):157-165.
3. Al-Mulhim AA. Emergency general surgical admissions. Prospective institutional experience in non-traumatic acute abdomen: Implications for education, training and service. Saudi Med J. 2006;27(11):1674-1679.
4. Asefa Z. Acute appendicitis in Yirgalem hospital, Southern Ethiopia. Ethiop Med J. 2002;40(2):155-162.
5. Ghalige HS, Karthik K, Vinay HD, Santhosh R. A study of non traumatic acute abdomen in ESIC. Int J Health Clin Res. 2021;4(8):81-86.
6. Chanana L, Jegaraj MA, Kalyaniwala K, Yadav B and Abilash K. Clinical profile of non-traumatic acute abdominal pain presenting to an adult emergency department. J Family Med Prim Care. 2015;4(3):422-425.
<https://doi.org/10.4103/2249-4863.161344>

7. Pickuth D, Heywang-Köbrunner SH and Spielmann RP. Suspected acute appendicitis: Is ultrasonography or computed tomography the preferred imaging technique? *Eur J Surg.* 2000;166(4):315-319.
<https://doi.org/10.1080/110241500750009177>
8. Mazzei MA, Guerrini S, Squitieri NC, Cagini L, Macarini L, Coppolino F, et al. The role of US examination in the management of acute abdomen. *Crit Ultrasound J.* 2013; 5 Suppl 1(Suppl 1):S6.
9. Gunduz Y, Tatli AP and Kara RO. Mesenteric panniculitis: A case report and review of the literature. *Maedica (Bucur).* 2012;7(4):344-347.
<https://doi.org/10.1186/2036-7902-5-S1-S6>
10. Horton KM, Talamini MA and Fishman EK. Median arcuate ligament syndrome: Evaluation with CT angiography. *Radiographics.* 2005;25(5):1177-1182.
<https://doi.org/10.1148/rg.255055001>

Authors' Contributions:

RC, VG, MA- Definition of intellectual content, literature survey, prepared first draft of manuscript, implementation of study protocol, data collection, data analysis, manuscript preparation, and submission of article, concept, design, clinical protocol, editing, and manuscript revision, design of study, statistical analysis and interpretation, review manuscript, literature survey, and coordination.

Work attributed to:

Department of Radio-diagnosis, Maharani Laxmi Bai Medical College, Jhansi - 284 128, Uttar Pradesh, India.

Orcid ID:

Rachna Chaurasia - <https://orcid.org/0000-0003-4261-6324>

Vishal Gupta - <https://orcid.org/0009-0000-7207-1746>

Mohd. Abubakar - <https://orcid.org/0009-0009-7655-4652>

Source of Support: Nil, **Conflicts of Interest:** None declared.