

# Clinical, radiological, and functional evaluation of surgical treatment in degenerative lumbar canal stenosis



Mayank Jeswani<sup>1</sup>, Vivek Kumar Kankane<sup>2</sup>, Avdhesh Shukla<sup>3</sup>, Avinash Kumar<sup>4</sup>, Avinash Sharma<sup>5</sup>

<sup>1,4</sup>Senior Resident, <sup>2</sup>Associate Professor, <sup>3</sup>Professor, <sup>5</sup>Professor and Head, Department of Neurosurgery, Gajra Raja Medical College, Gwalior, Madhya Pradesh, India

Submission: 28-03-2023

Revision: 02-06-2023

Publication: 01-07-2023

## ABSTRACT

**Background:** Low-back pain (LBP) is extremely prevalent and is the one of the most common causes for people to seek medical attention. As life expectancy continue to increase, prevalence of symptomatic spinal stenosis will increase. Although lumbar stenosis is not life-threatening, it can cause chronic and sustained pain and can limit activity severely. Early, accurate diagnosis, and treatment of lumbar stenosis is important in preserving activity in elderly population. **Aims and Objectives:** The study was conducted to find the incidence of degenerative lumbar canal stenosis (LCS) among patients of LBP, to evaluate clinicoradiological profile and to evaluate the outcome and complications in the surgically treated patients of degenerative LCS. **Materials and Methods:** This prospective study included all patients admitted with LCS under department of neurosurgery, GR medical college and associated J.A. group of Hospitals from December 2021 to December 2022 who underwent surgery. No randomization done. **Results:** Out of total 48 patients, 58% were males while 42% were females, 62.5% of patients were of more than 40 years of age, all patients were having LBP and 64.5% of patients were having LBP for the past 1 year. After surgical management, 87.5% of patients shows improvement in symptoms in Oswestry disability index and Visual analog scale scales. **Conclusion:** Overall good surgical outcome is obtained and better surgical results in degenerative LCS compared to other studies. Patients with degenerative LCS presenting with back pain and associated neurological deficit are successfully managed with surgical treatment in this study.

**Key words:** Lumbar canal stenosis; Laminectomy; Oswestry disability index; Visual analog scale

## INTRODUCTION

Descriptions of treatment for low back pain (LBP) date to Hippocrates (460–370 BCE), who reported joint manipulation and use of traction. Onset of LBP often is associated with bipedal ambulation. Lumbar canal stenosis (LCS) is a continuum of pathology and one of the most useful definitions of LCS is that described by Verbiest in 1954 as “a disproportion in the spinal canal between the size of the neural elements and the space available.”

LBP is extremely prevalent and is the one of the most common cause for people to seek medical attention.

As life expectancy continue to increase, prevalence of symptomatic spinal stenosis will increase. Although lumbar stenosis is not life threatening it can cause chronic and sustained pain and can limit activity severely. Early, accurate diagnosis, and treatment of lumbar stenosis is important in preserving activity in elderly population.<sup>1</sup>

Lumbar spinal stenosis is a progressive and degenerative process that causes narrowing of spinal canal, lateral recess, or neural foramina and is divided into two groups, that is, congenital and acquired. The narrowing results in the compression of lumbosacral roots by bony canal or soft tissues including the intervertebral disc, facet joints,

### Access this article online

#### Website:

<http://nepjol.info/index.php/AJMS>

DOI: 10.3126/ajms.v14i7.53634

E-ISSN: 2091-0576

P-ISSN: 2467-9100

Copyright (c) 2023 Asian Journal of Medical Sciences



This work is licensed under a Creative Commons Attribution-NonCommercial 4.0 International License.

### Address for Correspondence:

Dr. Avinash Sharma, Professor and Head, Department of Neurosurgery, Gajra Raja Medical College, Gwalior, Madhya Pradesh, India.

Mobile: +91-9039965510. E-mail: [mj\\_mgmmc@yahoo.com](mailto:mj_mgmmc@yahoo.com)

and flavum. This narrowing causes axial lumbar pain, radicular pain, and cauda equina syndrome when thecal sac and nerve roots are compressed.<sup>2,3</sup> Surgery is indicated in patients who have progressive neurological decline or when non-operative maneuvers have failed adequately to address the symptoms.

The present dissertation is going to be a prospective study of 48 cases of LCS to be treated for a period of 1 year (2021–2022) by conservative treatment and operative modalities such as decompressive laminectomy, discectomy, foraminotomy/medial facetectomy, or excision of hypertrophied ligamentum flavum.

### Aims and objectives

1. To study the incidence of degenerative lumbar canal stenosis among patients of low back pain.
2. To evaluate clinico-radiological profile of patients with degenerative lumbar canal stenosis.
3. To evaluate the outcome and complications in the surgically treated patients of degenerative lumbar canal stenosis.

### Criteria

- Normal AP diameter of lumbar canal is 13–27 mm.

LCS is defined as narrowing of AP diameter of lumbar canal. It can be –

1. Relative stenosis – When the AP diameter is 10–13 mm
2. Absolute/Critical stenosis – When the AP diameter is <10 mm.

### Visual analog scale (VAS)

A VAS is a (Figure 1) measurement instrument that tries to measure a characteristic or attitude that is believed to range across a continuum of values and cannot easily be directly measured. It is often used in epidemiological and clinical research to measure the intensity or frequency of various symptoms.

### Oswestry disability index (ODI)

The self-completed questionnaire contains ten topics concerning intensity of pain, lifting, ability to care for oneself, ability to walk, ability to sit, sexual function, ability to stand, social life, sleep quality, and ability to travel.

The patient then checks the statement which most closely resembles their situation.

The scores for all questions answered are summed, then multiplied by two to obtain the index (range 0–100).

Zero is equated with no disability and 100 is the maximum disability possible.

- 0–20%: Minimal disability
- 21–40%: Moderate disability
- 41–60%: Severe disability
- 61–80%: Crippling back pain
- 81–100%: These patients are either bed-bound or have an exaggeration of their symptoms.

## MATERIALS AND METHODS

The approval of institutional ethical board was obtained from Gajra Raja Medical College Institutional Review Board under the letter number 1004, dated July 16, 2021. This was a prospective study of patients who were admitted with LCS under department of neurosurgery, GR medical college (GRMC) and associated J.A. group of Hospitals from December 2021 to December 2022 who underwent surgery and analyzing the patient's reports to assess the results.

After the admission of patients, they underwent clinical and radiological examination like X-ray lumbosacral spine in flexion and extension views, MRI of the lumbosacral spine. Preoperatively, all the patients were asked to fill the ODI and VAS forms following which after assessment of all the patients, they underwent surgical procedure. Intraoperative findings were noted and in the follow-up patients were reviewed to fill ODI and VAS. Data were analyzed with SPSS 21, paired samples t-test for parametric VAS and ODI were conducted. The correlation was investigated using regression analysis, where the significance was determined as  $P < 0.05$ .

### Inclusion criteria

All the patients with radiological evidence of degenerative lumbar canal stenosis after failure of adequate conservative treatment for 3 months were included in the study.

### Exclusion criteria

Patients with primary canal stenosis who do not have any prior history of lumbar or lower extremity surgery, trauma, tumor, and those not willing for participation were excluded from the study.

## RESULTS

A non-randomized, prospective, and single institute study was conducted between December 2021 and December 2022, in GRMC and JA group of hospitals, Gwalior over a period of 1 year in the department of Neurosurgery on 48 patients diagnosed with degenerative LCS. Based on the data, collected and data analyses following observations were made.

**Table 1: MRI LS spine parameters**

MRI parameters	At L1-L2 level (n)	At L2-L3 level (n)	At L3-L4 level (n)	At L4-L5 level (n)	At L5-S1 level (n)
Disc bulge	1	4	11	38	37
Disc dehydration	3	14	31	36	29
Facetal hypertrophy	1	9	17	29	24
Ligamentum flavum hypertrophy	3	9	20	30	27
End plate changes	0	3	15	22	19

Majority of the patients with LCS were males (58%) as compared to females (42%), were adults with age more than 40 years (62.5%) and remaining (37.5%) were of age <40 years among which by occupation, they were laborers (31%), farmers (23%), and household workers (19%). About 41.6% of patients has no history of heavy weight lifting while 31.2% of patients has history of heavy weight lifting for 5–10 years.

Out of 48 patient, majority of patients (100%) presented with low back ache, followed by complaint of dermatomal sensory loss in 25% of patients. About 58% of patients had paraparesis. About 16% of patient had history of bowel and bladder involvement at the time of admission. Patients (64.5%) in this study who had LCS were having back pain for 1 year while 20.8% patients had back pain for >2 years, majority of patients (54.1%) had claudication for <6 months duration while 45.9% of patients had claudication for >6 months duration.

Most of the patients in this study had reduced disc space at L4-L5 level (35 patients) and it was seen that most patients had canal stenosis starting from L3 to S1 levels due to various pathologies while least involvement was seen at L1-L2 level. On MRI, most of the patients in this study had disc bulge at L4-L5 level (38 patients) and it was seen that most patients had canal stenosis starting from L3 to S1 levels due to various pathologies while least involvement was seen at L1-L2 level, 34 patients had diffuse disc bulge causing compression of bilateral nerve roots and causing stenosis of bilateral neural foramina while only 14 patients had right or left nerve root compression depending on the site of disc bulge (Table 1).

In surgical management of LCS, decompressive laminectomy was done to decrease the pressure on thecal sac, out of 48 patients, 64.6% of patients underwent multiple levels laminectomy while 35.4% of patients underwent single level laminectomy at the site of maximum compression and intraoperatively, it was found that ligamentum flavum hypertrophy and intervertebral foraminal narrowing was seen in 100% of patients while 95.8% of patients have disc bulge causing foraminal stenosis and lateral recess narrowing at one or multiple levels and are having prolapsed intervertebral disc at

**Table 2: Intraoperative findings**

Intraoperative findings	Number of cases (n)	In %
Ligamentum flavum hypertrophy	48	100
Facetal hypertrophy	34	70.8
Disc bulge	46	95.8
Intervertebral foramen narrowing	48	100

shoulder region while the rest had disc at axilla (Table 2).

Majority of the patients (89.5%) in this study who had LCS were not having any post-operative complications while 10.5% of patients had local complications like wound infections or cerebrospinal fluid leak. After surgical management, significant number of patients (87.5%) had improvement in pain and claudication after 1 month of surgery while no patient shown improvement in sensory symptoms.

After surgical treatment of LCS, patient improved symptomatically in VAS and ODI scales in follow-up (Table 3).

## DISCUSSION

A study of 48 cases was made of patients with LCS. The diagnosis of LCS was based on clinical findings and supported by radiological investigations.

In the present study, it was seen that most of the patients presented with clinical deformity among which loss of lordosis being commonest,<sup>4,5</sup> all the patients had ligamentum flavum hypertrophy intraoperatively at one or multiple levels while most of the patients had disc bulge or/and facetal hypertrophy at one or various levels of lumbar canal. These results obtained after this study were comparable to the study conducted by Fatigba et al.,<sup>6</sup> in 2015 and they found that 51% of patients had ligamentum flavum hypertrophy and is a major contributor in pathogenesis of LCS while Ivanov et al.,<sup>7</sup> found that 95% of patients had facetal hypertrophy, 92% of patients had disc bulge while 95% of patients had ligamentum flavum hypertrophy.

After comparison of sex distribution of various studies like Deer et al.<sup>8</sup> in 2019, Hopp et al.<sup>14</sup>, Caputy et al.<sup>12</sup> and

**Table 3: Improvement in VAS and ODI in follow-up patients**

Follow-up improvement in VAS	Pre-operative VAS	Post-operative VAS	Follow-up improvement in ODI	Pre-operative ODI	Post-operative ODI
Up to 2	0	15	Minimal disability	0	14
3-4	4	29	Moderate disability	5	30
5-6	22	4	Severe disability	29	4
7-8	17	0	Crippling pain	13	0
9-10	5	0	Bed ridden	2	0

VAS: Visual analog scale, ODI: Oswestry disability index

**Table 4: Comparison of surgical outcome with various studies<sup>2</sup>**

	Berger et al.	Silvers et al.	Kats et al.	Dean et al.	Bernst et al.	Present study
Overall improvement	80%	75%	75%	-	65-85%	89.5%
Bladder improvement	-	-	-	60%	-	10.4%

**Table 5: Comparison with Iverson et al., study<sup>15</sup>**

Parameters	Iverson et al.	Present study
Female %	65%	58%
Mean duration of low back pain	24 months	11 months
Motor deficit	51%	58%
Sensory deficit	81%	25%
Claudication pain	66%	100%
Previous spine surgery	16%	0
Back pain	65%	100%
Spine tenderness	26%	18.75%

In the present study, overall improvement was assessed using VAS and ODI and it was found that 89.5% of patients had overall improvement in symptoms which was comparable to studies like Katz et al.<sup>10</sup>, and Johnsson et al.<sup>11</sup>. (Table 4).

In the present study, it was found that most of the patients of LCS were females who presented with complaints of back pain with a mean duration of 11 months. Most of these patients had motor deficits in the form of paraparesis or paraplegia while 25% of patients presented with sensory symptoms. These findings are comparable with Iverson et al., study<sup>15</sup> in which there is female preponderance and most of the patients presented with motor symptoms (Table 5).

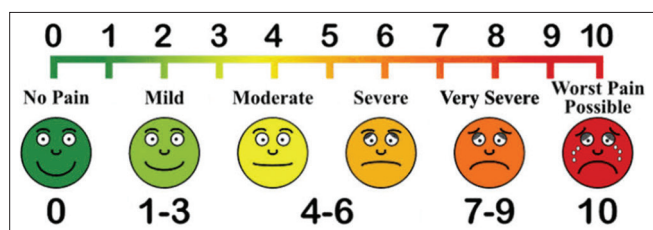


Figure 1: Diagrammatic presentation of VAS

**Limitations of the study**

Patients requiring instrumentation during surgery are not included in the study.

Katz et al.<sup>3</sup>, with our present study. It was seen that lumbar canal stenosis is seen mostly in females compared to male population. However, the results obtained by Johnsson et al.<sup>11</sup> study, most of the patients of LCS were males which is contrary to result obtained in present study.

**CONCLUSION**

Overall good surgical outcome is obtained and better surgical results in degenerative LCS compared to other studies. Patients with degenerative LCS presenting with back pain and associated neurological deficit are successfully managed with surgical treatment in this study.

In the present study, it was found that all patients had back pain from some point of time in which most of the patients had symptoms like back pain for <1 year for which they were taking symptomatic treatment. Katz<sup>10</sup> in 2022 conducted a study and found that back pain is the main presenting complaint and after taking conservative treatment for 1 year one-third patients were relieved symptomatically and results of present study is compared with various studies like Caputy<sup>12</sup> and Lussenehop; Ciric et al.<sup>13</sup> and Johnsson et al.<sup>11</sup>. It was found that mean duration of pain of patients taken in the present study was 11 months

Similar to other studies, there is a female preponderance and factors such as smoking, alcoholism, hypertension, and diabetes mellitus have no significant influence in the outcome of treatment of degenerative LCS.

**ACKNOWLEDGMENT**

The authors are acknowledged to present part of this paper in the form of paper Presentation at MP chapter NSICON 2022.



## REFERENCES

1. Yong-Hing K, Kirkaldy-Willis WH, Wedge JH and Reilly J. Pathology and pathogenesis of lumbar spondylosis and stenosis. *Spine (Phila Pa 1976)*. 1978;3(4):319-328. <https://doi.org/10.1097/00007632-197812000-00004>
2. Spivak JM. Degenerative lumbar spinal stenosis. *J Bone Joint Surg Am*. 1998;80(7):1053-1066. <https://doi.org/10.2106/00004623-199807000-00015>
3. Katz JN and Harris MB. Lumbar spinal stenosis. *N Engl J Med*. 2008;358(8):818-825. <https://doi.org/10.1056/NEJMcp0708097>
4. Weiner BK, Patel NM and Walker MA. Outcomes of decompression for lumbar spinal canal stenosis based upon preoperative radiographic severity. *J Orthop Surg Res*. 2007;2:3. <https://doi.org/10.1186/1749-799X-2-3>
5. Alexander E. Significance of small lumbar canal: Cauda equina compression syndrome due to spondylosis part 4. *J Neurosurg*. 2019;31(5):513-519.
6. Fatigba HO, Hans-Moevi AA, Belo M, de Tové S, Pape AG and Mijiyawa M. Aetiology of the lumbar spinal stenosis in black Africans: Intraoperative observations. *Iran J Neurosurg*. 2015;1(1):35-38.
7. Ivanov I, Milenković Z, Stefanović I and Babić M. Lumbar spinal stenosis. Symptomatology and methods of treatment. *Srp Arh Celok Lek*. 1998;126(11-12):450-456.
8. Deer T, Sayed D, Michels J, Josephson Y, Li S and Calodney AK. A review of lumbar spinal stenosis with intermittent neurogenic claudication: Disease and diagnosis. *Pain Med*. 2019;20(Suppl 2):S32-S44. <https://doi.org/10.1093/pm/pnz161>
9. Hansraj KK, Cammisa FP Jr., Patrick F, O'leary PF, Crockett HC, Fras CI, et al. Decompressive surgery for typical lumbar spinal stenosis. *Clin Orthop Relat Res*. 2001;384:10-17. <https://doi.org/10.1097/00003086-200103000-00003>
10. Katz JN, Zimmerman ZE, Mass H and Makhni MC. Diagnosis and management of lumbar spinal stenosis: A review. *JAMA*. 2022;327(17):1688-1699. <https://doi.org/10.1001/jama.2022.5921>
11. Johnsson KE, Rosén I and Udén A. The natural course of lumbar spinal stenosis. 1992;279:82-86.
12. Caputy AJ and Lussenehop AJ. Long-term evaluation of decompressive surgery for degenerative lumbar stenosis. *J Neurosurg*. 1992;77(5):669-676. <https://doi.org/10.3171/jns.1992.77.5.0669>
13. Ciric I, Mikhael MA, Tarkington JA and Vick NA. The lateral recess syndrome. A variant of spinal stenosis. *J Neurosurg*. 1980;53(4):433-443. <https://doi.org/10.3171/jns.1980.53.4.0433>
14. Hopp E and Tsou PM. Post decompression lumbar instability. *Clin Orthop Relat Res*. 1988;227:143-51.
15. Iversen MD and Katz JN. Examination findings and self-reported walking capacity in patients with lumbar spinal stenosis. *Phys Ther*. 2001;81(7):1296-1306.

### Authors Contribution:

**MJ**- Definition of intellectual content, literature survey, prepared first draft of manuscript, implementation of study protocol, data collection, data analysis, manuscript preparation, and submission of article; **VKK**- Concept, design, clinical protocol, manuscript preparation, editing and revision, and statistical analysis; **AS**- Review manuscript and preparation of tables; **AK**- Coordination and manuscript revision; **AS**- Manuscript preparation, editing and revision.

### Work attributed to:

Department of Neurosurgery, Gajra Raja Medical College, Gwalior, Madhya Pradesh, India.

### Orcid ID:

Mayank Jeswani - <https://orcid.org/0009-0001-6460-4036>  
 Vivek Kumar Kankane - <https://orcid.org/0000-0001-9068-7886>  
 Avdhesh Shukla - <https://orcid.org/0000-0003-3583-8332>  
 Avinash Kumar - <https://orcid.org/0000-0003-2621-5686>  
 Avinash Sharma - <https://orcid.org/0000-0002-2178-3070>

**Source of Funding:** None, **Conflicts of Interest:** None.