

The diagnostic and therapeutic evaluation of Idiopathic granulomatous mastitis. A case series



Amalesh Barman¹, Ayanti Barman², Miraj Ali Khan³, Ranajit Bari⁴

¹Associate Professor, Department of General Surgery, ⁴Assistant Professor, Department of General Medicine, Tamralipto Government Medical College, Tamluk, ²3rd year Postgraduate Resident, Department of Dental Surgery, Haldia Institute of Dental Science and Research, Haldia, ³Senior Resident, Department of Surgery, Midnapore Medical College, Midnapore, West Bengal, India

Submission: 07-02-2023

Revision: 23-05-2023

Publication: 01-07-2023

ABSTRACT

Idiopathic granulomatous mastitis (IGM) is a rare chronic inflammatory condition of the breast that is commonly found in young women of childbearing age with a history of recent breastfeeding. In our study, we aimed to present the detailed clinical and morphological features of IGM cases, diagnostic clues, and treatment. The most common clinical presentation is a unilateral, breast induration, nipple retraction, and even a multiple sinus formation often associated with an inflammation of the overlying skin. It usually mimics with breast abscess, rarely inflammatory breast cancer. Although etiology is still unknown. Many factors, including autoimmunity, infection, chemical agent, lactation, and hormonal imbalance, are supposed to play a role for etiology. Therefore, thorough history taking, examination, imaging, and histopathology make a proper diagnosis that determines the optimal management to be administered. We are presenting three cases of granulomatous mastitis from our clinical practice with varying clinical features. After the necessary investigation, we diagnose it as IGM. There is no definitive treatment guideline still now. In literature, many therapeutic operations, including conservative treatment, surgery, steroid, and immunotherapy, have been shown. However, we successfully treated this patient by conservative treatment, by incision and drainage, surgical debridement, or by in a combination of both, followed by regular dressing, antibiotics, and other supportive measures with no use of the steroid.

Key words: Idiopathic granulomatous mastitis; Etiology; Breast abscess; Surgical debridement; Steroid

Access this article online

Website:

<http://nepjol.info/index.php/AJMS>

DOI: 10.3126/ajms.v14i7.52167

E-ISSN: 2091-0576

P-ISSN: 2467-9100

Copyright (c) 2023 Asian Journal of Medical Sciences



This work is licensed under a Creative Commons Attribution-NonCommercial 4.0 International License.

INTRODUCTION

Idiopathic granulomatous mastitis (IGM) was first described in 1972. The disease is characterized by chronic and relapsing inflammation, resulting in scarring and discharging sinuses.¹ Many factors, including autoimmunity, infection, chemical agent, lactation, and hormonal imbalance, are supposed to play a role for etiology.² Clinical features are overlapping with bacterial mastitis and abscess. Empirical antibiotics are commonly used. Careful examination, investigation, and pre-occupied knowledge can avoid delays in the diagnosis. Definite etiopathogenesis are yet to be identified; some studies suggested damage to the ductal epithelium that causes extravasation of glandular secretions into the connective

tissue of the lobule, creating local inflammatory lesions.³ Others have also proposed immunological disorders.

Because of its uncommon etiology, and rareness, diagnosis and treatment is still a challenge. Diagnosis is made by exclusion. Other than bacterial mastitis and inflammatory carcinoma, tuberculosis, sarcoidosis, periductal mastitis, Corynebacterial infection, hyperprolactinemia, fat necrosis, trauma, and other autoimmune-related features joint pain, skin rash, erythema nodosum should be kept in mind during evaluation. Definitive diagnosis was made by histopathology. Histopathology shows a non-caseating granulomatous formation in combination with a localized infiltration of multi-nucleated giant cells, epithelioid histiocytes, and plasma cells.² Ultrasonography has an

Address for Correspondence:

Dr. Ranajit Bari, Assistant Professor, Department of General Medicine, Tamralipto Government Medical College, Tamluk, West Bengal, India. **Mobile:** +91-9433360027, **E-mail:** dr.ranajit@gmail.com

important role to grade the severity of the breast pathology and to exclude other pathology.

CASE PRESENTATION

Case 1

27-years-old female presented with tender indurated lumpiness in the outer quadrant of her right breast for 7 days. It was associated with mild local inflammatory signs, and mobile, axillary lymphadenopathy. She had no history of fever, joint pain, trauma, or weight loss, with no prior history of tuberculosis disease or tuberculous contact and no familial neoplasia history. She had one 5 years children and has not taken oral contraceptive. Her bowel and bladder habits were normal. She had a history of breast abscess in her opposite breast 2 years ago and it was taken about 5 months to heal.

She had no comorbidity. Her vital signs were normal and her BMI of 27 kg/m². She was advised a course of oral antibiotics, and analgesics along with a basic blood test and ultrasound. After 1 week on her second visit, she became better and her USG revealed small hypoechoic lesions with collection in the outer quadrant of the breast. Laboratory evaluation was within normal limits, including blood sugar and prolactin with mild leukocytosis. After about 3 weeks from her first visit, she attended 3rd time with a localized abscess, with underlying induration in the same area of her breast along with nipple retraction. We did incision and drainage with debridement for indurated tissue. Incisional biopsy was taken and pus sent for bacterial culture and for acid-fast bacilli. She was advised to do regular dressing, oral antibiotics, and other supportive measures. Histopathology showed non-caseating granulomatous lesions (Figure 1). Pus culture was sterile and had no acid-fast bacilli. After regular dressing, it was taken about 4 months to heal.

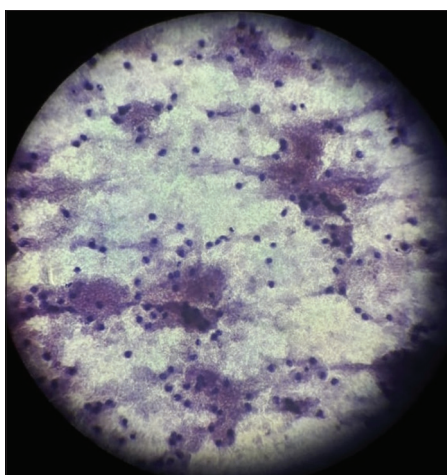


Figure 1: Histopathology showing non-caseating granulomatous lesions

Case 2

A 30-year-old female presented with post-operative nonhealing ulcer with discharging sinus in the outer quadrant of her right breast. She was operated for breast abscess about 1 month back by another surgeon. Pre-operative ultrasonography of the breast revealed a hypoechoic lesion with a collection suggesting abscess (Figure 2). She had a child of 3 years old. She was taking oral contraceptives and had no comorbidity. She had normal vital signs and a BMI of 26.9 kg/m². The breast examination showed a two-centimeter ulcer with underlying induration and one adjacent sinus. The nipple was retracted toward the lesion. Axillary nodes were not palpable. Left breast was normal. Her blood sugar and prolactin were within normal limits. Pus for acid-fast bacilli and CBNAAT was negative. Postoperative histopathology showed noncaseating granulomatous lesion. We advised regular dressing, oral antibiotics, and other supportive measures. After regular dressing, her symptoms started to resolve and it was taken 6 months to heal completely.

Case 3

A 25-year-old female attended with pain and swelling in inner quadrant of her left breast along with mild respiratory discomfort. She had a child of 3 years and was not lactating. She had no history of fever and tuberculosis. She was advised of empirical oral antibiotics, paracetamol, basic blood test, ultrasound of the breast and referred to a physician for distress. She was admitted and diagnosed with rheumatic heart disease by the physician and treated accordingly. She attended our clinic after 3 weeks with a resolving breast abscess along with two discharging sinuses. On examination, her vital were normal and BMI of 26 kg/m². Breast examination showed tender, soft, cystic lump of 3 cm×3 cm, adjacent two sinus with underlying induration. Overlying skin was erythematous. The nipple was retracted toward lesion. Her axilla was free. Laboratory evaluation revealed hemoglobin of 9.2 g%, raised anti-streptolysin O titer, and normal blood sugar and prolactin level. Ultrasonography

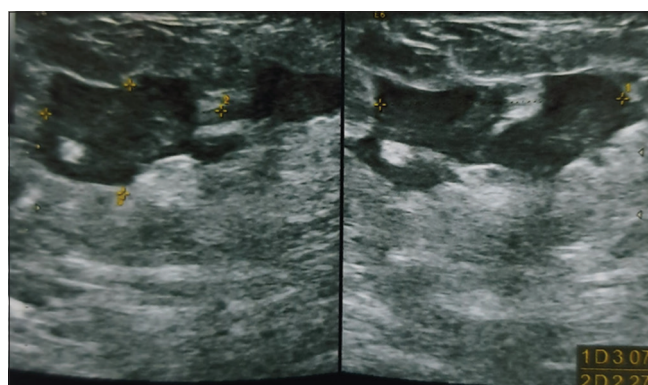


Figure 2: Ultrasonography of breast revealed hypoechoic lesion with collection suggestive of abscess

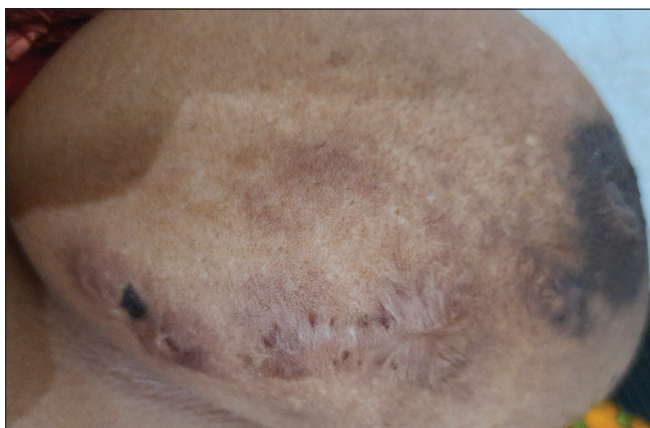

Figure 3: After treatment of idiopathic granulomatous mastitis

showed resolving abscess with sinuses. Pus culture ruled out tuberculosis. Tru-cut biopsy confirmed diagnosis of IGM. She advised broad-spectrum oral antibiotics, analgesic, regular dressing, and other supportive measures. The patient was explained regarding the disease process.

After a regular follow-up of 4 months, she had no features of breast pathology (Figure 3).

DISCUSSION

Our study revealed clinical presentation with painful indurated diffuse breast mass with nipple retraction in first case, post-operative nonhealing ulcer with sinus formation in second case and breast abscess in third case. Other studies showed similar presentations.^{2,4} Many literature highlighted the disease association with childbearing age and postlactation period.⁵ Our study showed similar results that all three patients were 20–30 years of age, and within 5 years of childbirth. All patients were obese and one patient was taking oral contraceptive pills. Ultrasonography showed hypoechoic lesions, sinus, skin thickening, area involvement and excluded neoplastic lesions.⁶ Mammogram was not performed due to the presence of pain and discharge. Pus culture was done for superadded bacterial infection and acid-fast bacilli to rule out tuberculosis. Along with other studies, our case series emphasized that histopathology was required to confirm the diagnosis. We did incisional biopsy or tru-cut biopsy for confirmation of diagnosis. Histopathology showed non-caseating epithelioid granuloma. Sometimes ductal pathology may be related to the IGM for that it is manifested after the lactational period. Treatment mainly depends on its etiopathogenesis. Autoimmunity is the cornerstone of the disease. Therefore, the steroid is the most common therapeutic choice.⁶ As our patients had supportive features, and considering long-term side effects, we did not use steroid. In our first case, We did conservative treatment initially with oral antibiotics and analgesic followed by incision and

drainage when it became localized. It took about 4 months to heal with regular dressing. The second case was postoperative; therefore, regular dressing with antibiotics helped to heal within 6 months. Last case presented with abscess; we offered conservative treatment and dressing. Methotrexate is another option, but it has limited evidence.⁷ Our study showed many of the IGM cases can be safely treated by conservative treatment or by surgical procedures, or by in a combination of both followed by regular follow-up with dressing, antibiotics, and others supportive measures for 4–6 months.

CONCLUSION

IGM is a rare disease. It may mimic breast abscess or carcinoma. The diagnosis is made by the method of exclusion by proper examination and imaging test. The histopathological examination remains the main element for diagnosis. The treatment may vary from conservative to surgery, depending on the extent of breast pathology. Sometimes, steroid therapy may be helpful.

ACKNOWLEDGMENT

Authors would like to acknowledge the patients who participated in this research study.

REFERENCES

1. Coombe RF and Hamed H. An update on granulomatous mastitis: A rare and complex condition. *Br J Hosp Med (Lond)*. 2021;82(5):1-7. <https://doi.org/10.12968/hmed.2020.0718>
2. Wolfrum A, Kümmel S, Theuerkauf I, Pelz E and Reinisch M. Granulomatous mastitis: A therapeutic and diagnostic challenge. *Breast Care (Basel)*. 2018;13(6):413-418. <https://doi.org/10.1159/000495146>
3. Sarkar DK, Banerjee R, Gupta S, Singhal AK and Halder A. Management of idiopathic granulomatous mastitis: A prospective study. *Ann R Coll Surg Engl*. 2022;105(3):218-224. <https://doi.org/10.1308/rcsann.2022.0017>
4. Hashmi MU, Masood A, Yaseen S and Azam H. Idiopathic granulomatous mastitis: A rare confrontation. *Cureus*. 2021;13(11):e19420. <https://doi.org/10.7759/cureus.19420>
5. Altintoprak F, Kivilcim T and Ozkan OV. Aetiology of idiopathic granulomatous mastitis. *World J Clin Cases*. 2014;2(12):852-858. <https://doi.org/10.12998/wjcc.v2.i12.852>
6. Pala EE, Ekmekci S, Kilic M, Dursun A, Colakoglu G, Karaali C, et al. Granulomatous mastitis: A clinical and diagnostic dilemma. *Turk Patoloji Derg*. 2022;38(1):40-45. <https://doi.org/10.5146/tjpath.2021.01554>
7. Postolova A, Troxell ML, Wapnir IL and Genovese MC. Methotrexate in the treatment of idiopathic granulomatous mastitis. *J Rheumatol*. 2020;47(6):924-927. <https://doi.org/10.3899/jrheum.181205>

Authors' Contributions:

AmB- Concept design, manuscript preparation, manuscript review, treating surgeon; **AyB**- Prepared first draft of manuscript, literature review; **MAK**- Resident in-charge; **RB**- Manuscript review, manuscript editing, treating physician.

Work attributed to:

Tamralipto Government Medical College, West Bengal, India.

Orcid ID:

Dr. Ranajit Bari - <https://orcid.org/0000-0002-8488-9286>

Dr. Amallesh Barman - <https://orcid.org/0000-0001-6237-2676>

Ayanti Barman - <https://orcid.org/0000-0001-8651-4456>

Dr. Miraj Ali Khan - <https://orcid.org/0009-0002-5158-0757>

Source of Support: Nil, **Conflicts of Interest:** None declared.