

# Changes in central macular thickness before and after cataract surgery evaluated by optical coherence tomography in non-diabetic patient



Nilesh J Paraskar<sup>1</sup>, Vipul K Prajapati<sup>2</sup>, Jigna R Patel<sup>3</sup>, Sipra S Engineer<sup>4</sup>, Farhad Mansuri<sup>5</sup>

<sup>1,5</sup>Senior Resident, <sup>2</sup>Assistant Professor, <sup>4</sup>Resident Doctor, Department of Ophthalmology, M and J Regional Institute of Ophthalmology, B J Medical College and Civil Hospital, Ahmedabad, <sup>3</sup>Assistant Professor, Department of Ophthalmology, Surat Municipal Institute of Medical Education and Research, Surat, Gujarat, India

Submission: 31-01-2023

Revision: 28-05-2023

Publication: 01-07-2023

## ABSTRACT

**Background:** Optical coherence tomography (OCT) has been useful for objectively observing central macular thickness (CMT) changes in pre-operative and post-operative uneventful cataract surgery. **Aims and Objectives:** This study was done to compare changes in CMT in small incision cataract surgery (SICS) and phacoemulsification surgery and to illuminate the OCT features of CMT after uneventful cataract surgery. **Materials and Methods:** A prospective observational study was done at the tertiary eye care center from December 2019 to November 2020, a total of 60 patients underwent SICS and Phacoemulsification cataract surgery, were followed and examined postoperatively at day 1, 1 week, 1 month, and 6 months for whole ocular examination and OCT. **Results:** Comparison analysis was performed using Friedman's analysis of variance test. In SICS and Phacoemulsification group, statistical analysis differences between the mean CMT at pre-operative, post-operative 1 week, 1 month, and 6 months were found statistically significant ( $P > 0.001$ ), subclinical macular edema (increase CMT without affecting visual acuity) was noted at 1 week and 1 month reviews. **Conclusion:** The changes in CMT after cataract surgery are reversible, since the maximum measured increase in macular thickness at 1 month after surgery then gradually decreased at 6 months follow-up. This increase remained subclinical, and no evidence of clinical cystoid macular edema was seen on OCT.

**Key words:** Optical coherence tomography; Central macular thickness; Cataract; Cystoid macular edema

### Access this article online

**Website:**

<http://nepjol.info/index.php/AJMS>

**DOI:** 10.3126/ajms.v14i7.51980

**E-ISSN:** 2091-0576

**P-ISSN:** 2467-9100

Copyright (c) 2023 Asian Journal of Medical Sciences



This work is licensed under a Creative Commons Attribution-NonCommercial 4.0 International License.

## INTRODUCTION

Cataract extraction is one of the most commonly performed ophthalmic surgeries. Recent evolutions in instrumentation, lens design, and surgical technique have enhanced the outcome of cataract surgery.<sup>1</sup> An efficient procedure and uneventful cataract surgery are associated with good visual results.<sup>2</sup> The development of cystoid macular edema (CME) can lead to suboptimal post-operative diminution of vision.<sup>3</sup> This can occur in patients with ocular diseases, such as uveitis and diabetic retinopathy, and even after uncomplicated cataract surgery.<sup>4</sup> CME following cataract surgery was initially reported by Irvine in 1953 and demonstrated angiographically by

Gass and Norto in 1966, so it is known as Irvine Gass syndrome (pseudophakic cystoid macula edema).<sup>5-7</sup> Post-operative CME is recognized as the most common cause of the diminution of vision in patients following cataract surgery with or without the implantation of an intraocular lens (IOL).<sup>8</sup> This syndrome is accountable for a greater and frequent loss of vision than the more commonly discussed post-operative complications, including retinal detachment and endophthalmitis.<sup>8</sup> Incidence of clinical CME with visual loss has been reported to be between 1% and 6% after cataract surgery.<sup>9</sup> It is due to the release of inflammatory mediators that affect the blood-retinal barrier that leads to results in increased permeability of the parafoveal and perifoveal capillaries with fluid

### Address for Correspondence:

Dr. Nilesh J Paraskar, Senior Resident, Department of Ophthalmology, M and J Regional Institute of Ophthalmology, B J Medical College and Civil Hospital, Ahmedabad, Gujarat, India. **Mobile:** +91-9974744846. **E-mail:** njparaskar@gmail.com

accumulation in the retina that leads to CME.<sup>10</sup> The CME can be detected by clinically, angiographically, and optical coherence tomography (OCT). OCT is an objective, noninvasive, comfortable, noncontact method for quantitative measurements, with a high degree of reproducibility and repeatability, and with 10 mm resolution that helps to detect subtle changes in retinal thickness that cannot be seen at clinical examination.<sup>11</sup> OCT is the most sensitive way to detect CME, followed by angiography and then clinical examination.

### Aims and objectives

1. To compare changes in central macular thickness (CMT) in small incision cataract surgery (SICS) and phacoemulsification surgery
2. To illuminate the OCT features of CMT after uneventful cataract surgery.

## MATERIALS AND METHODS

A prospective and observational study was done at the tertiary eye care center from December 2019 to November 2020, with prior approval from the institutional ethics committee. There were a total of 60 patients included in the study after taking an informed and written consent.

### Inclusion criteria

Senile immature cataract underwent uneventful cataract surgery without any retinal, macular and other ocular pathology.

### Exclusion criteria

Mature cataract, traumatic cataract, complicated cataract, amblyopia, and squint. Intraoperative surgical complications such as vitreous loss, iris trauma, and posterior capsule rupture. Systemic diseases such as diabetes, hypertension, or cardiovascular disease. Patients using topical medication such as prostaglandins, pilocarpine, steroid, or systemic steroid.

### Study technique

A detailed history and ocular examination was made in all patients, which included pre- and post-operative visual acuity, which was recorded with the Snellen visual acuity chart and converted into LogMAR visual acuity, slit-lamp biomicroscopy of the anterior segment, and retinal biomicroscopy using +90D, +20D and OCT. The macular status of each eye was evaluated by Spectral Domain OCT (Topcon 3 DOCT-2000). All patients were followed and examined postoperatively at day 1, week, 1 month, and 6 months for best-corrected visual acuity (BCVA), tonometry, slit-lamp biomicroscopy of the anterior segment, and retinal biomicroscopy using +90D,+20D and OCT. Each eye was dilated with 1%

tropicamide and 5%phenylephrine hydrochloride before recording the image. During OCT examinations, six radial-line scans, 6.00 mm each in length and raster scan with the length of 5 mm in the horizontal and vertical axis, centered on the foveola, were performed and a topographical map of the macula was produced and CMT was measured.

### Surgical steps

All the patients were randomly divided into two groups and operated by the same surgeon using a standard technique. In phacoemulsification, 2.8 to 3.2 mm clear corneal incision, anterior capsulorrhexis, nuclear fragmentation using low to high ultrasound power and implantation of foldable acrylic hydrophobic IOL in the bag. In SICS, 5.5 to 6.5 mm superior sclerocorneal tunnel, anterior capsulorrhexis, the nucleus was delivered out of the anterior chamber. A 6.0 mm non-foldable polymethyl methacrylate single-piece rigid IOL was implanted in the bag at the end of surgery. The post-operative regimen included moxifloxacin (0.5%) and dexamethasone (0.1%) eye drops 6 times a day for the 1<sup>st</sup> week, followed by a tapering dose of it for weekly over 6 weeks. All patients were followed and examined postoperatively at day 1, week, 1 month, and 6 months for BCVA, slit-lamp examination of the anterior segment and retinal biomicroscopy using +90D, +20D, and OCT.

## RESULTS

This study was conducted at a tertiary eye care center from December 2019 to November 2020. Based on the defined inclusion and exclusion criteria, 60 individuals were enrolled in the study. The age of the patients ranged from 35 to 75 years (mean age 59.63±8.256 years). Of these, 31 (51% of the total) underwent SICS, 29 (49% of the total) underwent phacoemulsification. The mean age of SICS group was 58.71±9.648 (95% C.I.=45–75) years and phacoemulsification group was 60.39±6.477 (95% C.I.=35–74) years. In our study out of the total 60 patients, 28 (46%) patients were male and 32 patients (54%) were female. In SICS group, 12 (20%) were male and 19 (32%) were female, while in Phacoemulsification group, 16 (26%) were male and 13 (54%) female.

The mean pre-operative BCVA was 0.59±0.25 (95% C.I.=0.50–0.68) in Phacoemulsification and 0.67±0.32 (95% C.I.=0.55–0.79) in SICS; this difference was statistically significant ( $P<0.001$ ). The mean post-operative BCVA was 0.05±0.10 (95% C.I.= 0.01-0.09) in phacoemulsification and 0.06±0.11 (95% C.I.=0.02-0.10) in SICS, this difference was not statistically significant.

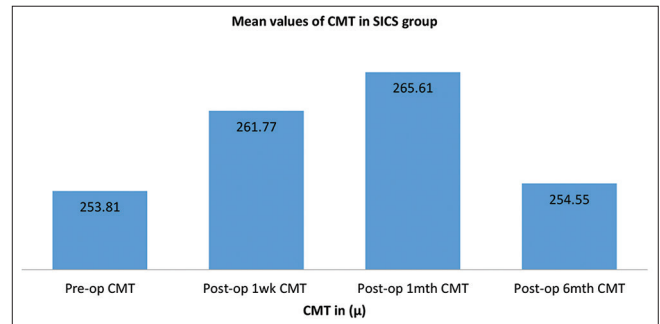
## CMT

The 60 patients who underwent cataract surgery, mean preoperatively CMT was  $255.30 \pm 15.757 \mu$  (95% C.I.=251.313–259.287  $\mu$ ). Postoperatively, at the 1<sup>st</sup> week, the mean CMT was  $262.50 \pm 17.083 \mu$  (95% C.I.=258.17–266.823  $\mu$ ); at the 1-month review, the mean CMT was  $265.15 \pm 17.219 \mu$  (95% C.I.=260.793–269.507  $\mu$ ); at the 6 months review, the mean CMT was  $255.50 \pm 15.655 \mu$  (95% C.I.=251.53–259.461  $\mu$ ); Statistical analysis of the differences between the four mean values of pre-operative, post-operative 1 week, 1 month, and 6 months) was done using Freidman's analysis of variance (ANOVA) test, the differences were found to be statistically significant ( $P < 0.001$ ). In the 60 patients who underwent cataract surgery, subclinical macular edema was noted at the 1<sup>st</sup> week and 1 month reviews; the peak subclinical macular edema was noted at the 1 month review. However, at the 6 months review, the CMT had reduced the baseline (pre-operative values).

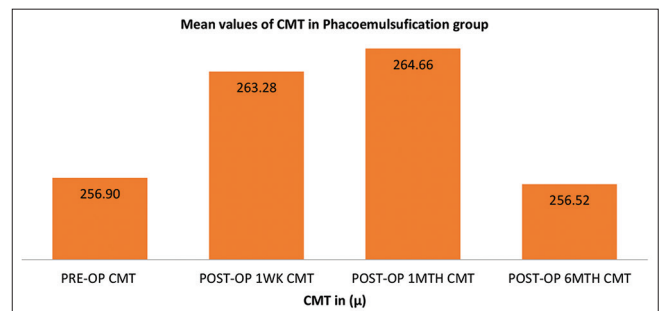
In SICS group, preoperatively, the mean CMT was  $253.81 \pm 18.48 \mu$  (95% C.I.=247.03–260.59  $\mu$ ). Postoperatively, the following readings were noted: at the 1<sup>st</sup> week, the mean CMT was  $261.71 \pm 19.104 \mu$  (95% C.I.=254.77–268.78  $\mu$ ); at 1-month review, the mean CMT was  $265.61 \pm 18.72 \mu$  (95% C.I.=258.74–272.48  $\mu$ ); at the 6 months review, mean CMT was  $254.55 \pm 18.01 \mu$  (95% C.I.=247.99–261.16  $\mu$ ); statistical analysis differences between the four mean values of CMT Pre-operative, Postoperative 1 week, 1 month and 6 months and was done using Friedman's ANOVA test; the differences were found statistically significant ( $P < 0.001$ ). In SICS group, subclinical macular edema was noted at the 1<sup>st</sup> week and 1 month reviews without visual acuity being affected (Figure 1).

In phacoemulsification group, preoperatively, the mean CMT value was  $256.90 \pm 12.32 \mu$  (95% C.I.=252.21–261.58  $\mu$ ). Postoperatively, the following readings were noted: At the 1<sup>st</sup>-week review, the mean CMT was  $263.28 \pm 14.921 \mu$  (95% C.I.=257.60–268.95  $\mu$ ); At the 1 month review, the mean CMT was  $264.66 \pm 15.767 \mu$  (95% C.I.=258.66–270.65  $\mu$ ); at the 6 months review the mean CMT was  $256.52 \pm 12.911 \mu$  (95% C.I.=251.61–261.43  $\mu$ ); statistical analysis differences between the four mean values of CMT Pre-operative, Post-operative 1 week, 1 month, and 6 months was made using Friedman's ANOVA test; the differences were found to be statistically significant ( $P < 0.001$ ) In Phacoemulsification group, there was a significant subclinical change in the macula, subclinical macular edema at the 1<sup>st</sup> week and 1 month follow-up without, the visual acuity being affected (Figure 2).

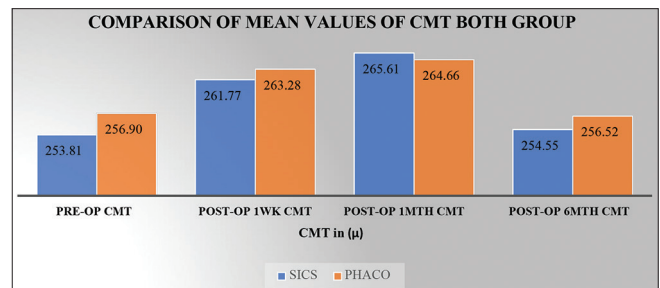
When both the group SICS and phacoemulsification cataract surgeries were compared, a subclinical macular edema was noted up to the 1 month review (Figure 3). CME was not noted in any of the patients in the current study.



**Figure 1:** Pre- and post-operative mean central macular thickness ( $\mu$ ) in 31 patients underwent small incision cataract surgery



**Figure 2:** Pre and post operative mean central macular thickness ( $\mu$ ) in 29 patients underwent phacoemulsification surgery



**Figure 3:** Comparison of pre and post-operative mean central macular thickness ( $\mu$ ) in patients underwent small incision cataract surgery and Phacoemulsification surgeries

## DISCUSSION

OCT is a method for high-resolution cross-sectional imaging of the retina that directly measures changes in the z-plane (depth of the retina).<sup>11-13</sup> There were total 60 patients divided into two group SICS and Phacoemulsification. The mean age of patients in this study was  $58.71 \pm 9.64$  in SICS group and  $60.39 \pm 6.4$  in the phacoemulsification group and this is similar to Ghosh et al.,<sup>14</sup> Where the mean age of patients was  $62 \pm 6$  in and  $61 \pm 6$  in SICS and Phacoemulsification group, respectively and is less compared to findings Biroetal<sup>15</sup> where average was  $68.8 \pm 8.8$  years. In the present study, female patients (54%) were more than males (46%) in contrast to Perente et al.,<sup>16</sup> and Agarwal et al.,<sup>17</sup> where male patients were frequently seen.

In the present study, we compared pre-operative and post-operative CMT in OCT scans at 1 week, 1 months and 6 months, similar to Perente et al.,<sup>16</sup> and Vukicevic et al.,<sup>18</sup> We had taken pre-operative CMT value as a control group increases the accuracy of our study as it overcomes the variability present in the normal population. In contrast to Ghosh et al.,<sup>14</sup> Biro et al.,<sup>15</sup> have taken the first post-operative day as the baseline value. While in another study done by Vonjagowetal<sup>19</sup> found that retina thickness was significantly increased on the first post-operative day may due to surgery-induced inflammation, so in the present study, we have considered pre-operative OCT scan as the baseline value.

In this study, CMT continued to increase on the first post-operative week in SICS and in phacoemulsification group, with a significance  $P < 0.001$ . At the 1 month of post-operative CMT in SICS and in phacoemulsification group at the 1-month review, the CMT was a significance  $P < 0.001$  and returned to Pre-operative value in SICS and phacoemulsification group, at the 6 month review. The present study is supported by Ghosh et al.,<sup>14</sup> Cagini et al.,<sup>20</sup> and Vukicevic et al.<sup>18</sup>

The study done by Lobo et al.,<sup>21</sup> showed increase in macular thickness maximum at post-op 6 week, which was conducted only in 32 patients; post-op examination was done at 3, 6, 12 and 30 week by OCT, while present study conducted in 60 patients and OCT was done at Pre-op, 1 week, 1 month and 6 months post-op examination. They noted at 30 weeks, all eyes had good visual acuity, but 7 (22%) eyes still had macular edema while in our study we did not find macular edema in any patient still 6 months of follow-up. In this study, CMT was assessed by OCT preoperatively, at 1 week, 1 month, and 6 month postoperatively, and a statistically significant increase in CMT started from 1 week till 1 month and a peak was seen at 1 month following uneventful cataract surgery in both groups, but this increase remained subclinical and no evidence of clinical CME was seen. There was no impact of increased CMT on the final visual outcome with either of the surgeries. Hence, both Phacoemulsification and SICS are comparable to each other in our study. This study shows that even after an uneventful SICS and phacoemulsification cataract surgery significant alterations occur in the macular thickness.

#### Limitations of the study

It was the relatively short post-operative duration over which patients came for review. It is possible that if follow-up period had been longer, the results may have been different. Another limitation of the study is that the number of patients ultimately enrolled in the two study groups was less due to the COVID-19 pandemic. Future studies

are required to confirm the initial results of the present investigation. In these future studies, a larger number of patients should be enrolled, and the study period should be extended.

## CONCLUSION

OCT is rapid, non-invasive and beneficial in detecting and monitoring CME in post-cataract surgery patients. There is an increase in CMT with respect to pre-operative values after uncomplicated cataract surgery on OCT. The changes in CMT after cataract surgery are reversible since the maximum measured increase in macular thickness at 1 month after surgery. The measured values of CMT then gradually decreased over the 6-month follow-up. The Subclinical macular edema after uncomplicated cataract surgery from 1 week after surgery and can last up to 1 month. This increase remained subclinical and no evidence of clinical CME was seen on OCT. There was no effect of increased macular thickness found on the final visual outcome with any of the surgeries. Hence, both the SICS and phacoemulsification surgeries are comparable to each other.

## ACKNOWLEDGMENT

We would like to acknowledge the department of ophthalmology of B.J. medical college Ahmedabad, and all the patients and staff included in this study.

## REFERENCES

1. DeCroos FC and Afshari NA. Perioperative antibiotics and anti-inflammatory agents in cataract surgery. *Curr Opin Ophthalmol.* 2008;19(1):22-26. <https://doi.org/10.1097/ICU.0b013e3282f30577>
2. Linebarger EJ, Hardten DR, Shah GK and Lindstrom RL. Phacoemulsification and modern cataract surgery. *Surv Ophthalmol.* 1999;44(2):123-147. [https://doi.org/10.1016/S0039-6257\(99\)00085-5](https://doi.org/10.1016/S0039-6257(99)00085-5)
3. O'Brien TP. Emerging guidelines for use of NSAID therapy to optimize cataract surgery patient care. *Curr Med Res Opin.* 2005;21(7):1131-1137. Review Erratum in: *Curr Med Res Opin.* 2005;21(7):1431-1432. <https://doi.org/10.1185/030079905X50651>
4. Nelson ML and Martidis A. Managing cystoid macular edema after cataract surgery. *Curr Opin Ophthalmol.* 2003;14(1):39-43. <https://doi.org/10.1097/00055735-200302000-00007>
5. Irvine AR. A newly defined vitreous syndrome following cataract surgery. *Am J Ophthalmol.* 1953;36(5):599-619. [https://doi.org/10.1016/0002-9394\(53\)90302-x](https://doi.org/10.1016/0002-9394(53)90302-x)
6. Gass JD and Norto EW. Cystoid Macular edema and papilledema following cataract extraction. A fluorescein fundoscopic and angiographic study. *Arch Ophthalmol.* 1966;76(5):646-661. <https://doi.org/10.1001/archophth.1966.03850010648005>

7. Irvine AR. Cystoid maculopathy. *Surv Ophthalmol.* 1976;21(1): 1-17.  
[https://doi.org/10.1016/0039-6257\(76\)90045-x](https://doi.org/10.1016/0039-6257(76)90045-x)
8. Flach AJ. The incidence, pathogenesis and treatment of cystoid macular edema following cataract surgery. *Trans Am Ophthalmol Soc.* 1998;96:557-634.  
<https://doi.org/10.1001/archophth.1989.01070010172003>
9. HariPriya A, Chang DF, Reena M and Shekhar M. Complication rates of phacoemulsification and manual small-incision cataract surgery at Aravind Eye Hospital. *J Cataract Refract Surg.* 2012;38(8):1360-1369.  
<https://doi.org/10.1016/j.jcrs.2012.04.025>
10. Ferrari TM, Cavallo M, Durante G and Mininno L. Cardascia uneventful and complicated cataract surgery. *Clin Ophthalmol.* 2012;6:1507-1511.  
<https://doi.org/10.2147/ophth.s34644>
11. Hee MR, Izatt JA, Swanson EA, Huang D, Schuman JS, Lin CP, et al. Optical coherence tomography of the human retina. *Arch Ophthalmol.* 1995;113(3):325-332.  
<https://doi.org/10.1001/archophth.1995.01100030081025>
12. Huang D, Swanson EA, Lin CP, Schuman JS, Stinson WG, Chang W, et al. Optical coherence tomography. *Science.* 1991;254(5035):1178-1181.  
<https://doi.org/10.1126/science.1957169>
13. Puliafito CA, Hee MR, Lin CP, Reichel E, Schuman JS, Duker JS, et al. Imaging of macular diseases with optical coherence tomography. *Ophthalmology.* 1995;102(2):217-229.  
[https://doi.org/10.1016/s0161-6420\(95\)31032-9](https://doi.org/10.1016/s0161-6420(95)31032-9)
14. Ghosh S, Roy I, Biswas PN, Maji D, Mondal LK, Mukhopadhyay S, et al. Prospective randomized comparative study of macular thickness following phacoemulsification and manual small incision cataract surgery. *Acta Ophthalmol.* 2010;88(4):e102-e106.  
<https://doi.org/10.1111/j.1755-3768.2010.01896.x>
15. Biro Z, Balla Z and Kovacs B. Change of foveal and perifoveal thickness measured by OCT after phacoemulsification and IOL implantation. *Eye (Lond).* 2008;22(1):8-12.  
<https://doi.org/10.1038/sj.eye.6702460>
16. Perente I, Utine CA, Ozturker C, Cakir M, Kaya V, Eren H, et al. Evaluation of macular changes after uncomplicated phacoemulsification surgery by optical coherence tomography. *Curr Eye Res.* 2007;32(3):241-247.  
<https://doi.org/10.1080/02713680601160610>
17. Agarwal R, Gupta PK and Gupta K. Macular edema after uncomplicated phacoemulsification in Type 2 diabetics with NPDR. *Int J Health Clin Res.* 2020;3(5):142-147.
18. Vukicevic M, Gin T and Al-Qureshi S. Prevalence of optical coherence tomography-diagnosed postoperative cystoid macular oedema in patients following uncomplicated phacoemulsification cataract surgery. *Clin Exp Ophthalmol.* 2012;40(3):282-287.  
<https://doi.org/10.1111/j.1442-9071.2011.02638.x>
19. Von Jagow B, Ohrloff C and Kohnen T. Macular thickness after uneventful cataract surgery determined by optical coherence tomography. *Graefes Arch Clin Exp Ophthalmol.* 2007;45(12):1765-1771.  
<https://doi.org/10.1007/s00417-007-0605-6>
20. Cagini C, Fiore T, Iaccheri B, Piccinelli F, Ricci MA and Fruttini D. Macular thickness measured by optical coherence tomography in a healthy population before and after uncomplicated cataract phacoemulsification surgery. *Curr Eye Res.* 2009;34(12): 1036-1041.  
<https://doi.org/10.3109/02713680903288937>
21. Lobo CL, Faria PM, Soares MA, Bernardes RC and Cunha-Vaz JG. Macular alterations after small-incision cataract surgery. *J Cataract Refract Surg.* 2004;30(4):752-760.  
[https://doi.org/10.1016/S0886-3350\(03\)00582-0](https://doi.org/10.1016/S0886-3350(03)00582-0)

**Authors' Contributions:**

**NJP**- Literature survey, prepared first draft of manuscript, data collection, data analysis, manuscript preparation and submission of article; **VKP**- Concept, design, clinical protocol, manuscript preparation, editing and manuscript revision; **JRP**- Design of study, statistical analysis, interpretation, manuscript preparation and editing; **SSE**- Review manuscript, literature survey; **FM**- Preparation of figures, coordination and manuscript revision.

**Work Attributed to**

M and J Regional Institute of Ophthalmology, B J Medical College and Civil Hospital, Ahmedabad, Gujarat, India.

**Orcid ID:**

Nilesh J Paraskar - <https://orcid.org/0009-0001-2601-2902>  
 Vipul K Prajapati - <https://orcid.org/0009-0008-6141-1301>  
 Jigna R Patel - <https://orcid.org/0009-0003-3628-8261>  
 Sipra S Engineer - <https://orcid.org/0009-0005-6526-6939>

**Source of Support:** Nil, **Conflict of Interest:** None declared.