

Incidence of renal artery stenosis and its hemodynamic significance in patients subjected to angiography for suspected coronary artery disease



Deepak Arun Khore¹, Sushilkumar Dharamraj Navsare²

^{1,2}Assistant Professor, Department of Medicine, ACPM Medical College, Dhule, Maharashtra, India

Submission: 20-07-2022

Revision: 23-10-2022

Publication: 01-12-2022

ABSTRACT

Background: Renal artery stenosis (RAS) may occur alone (isolated anatomical RAS) or in combination with hypertension (renovascular or essential hypertension), renal insufficiency (ischemic nephropathy), or both. Renal artery stenting can be performed safely with nearly uniform technical success without exposing them to significant incremental risk. **Aims and Objectives:** The objectives of the study are as follows: (A) To study the incidence of RAS in suspected coronary artery disease patients. (B) To study the hemodynamic significance of RAS in patients diagnosed having RAS. (C) Should patients undergoing coronary angiography be subjected to routine renal angiography during the procedure? **Materials and Methods:** We prospectively did renal angiography of consecutive 100 patients, who underwent coronary angiography for their suspected coronary artery disease. Data regarding risk factors were recorded for every patient. **Results:** Out of 12 patients with RAS, 10 had significant stenosis (>50%) out of which seven patients showed hemodynamically significant RAS on captopril renogram. These were the patients having stenosis of 70% or more on renal angiography. Three patients having RAS 50–70% on renal angiography were not having hemodynamically significant lesion on captopril renograms. **Conclusion:** Renal angiography should be performed in patients undergoing coronary angiography. Femoral artery should be the preferred access site for coronary angiography to approach renal arteries. The patients with RAS should undergo captopril renography to evaluate the hemodynamic significance of the stenosis.

Key words: Angiography; Captopril; Hemodynamically; Renograms; Stenosis

INTRODUCTION

Renal artery stenosis (RAS) is a narrowing of the arteries supplying one or both of the kidneys that can cause hypertension (high blood pressure) and, sometimes, reduced kidney function, and size (atrophy).¹ The common cause in middle-age and elderly is an atheromatous plaque at the origin of the renal artery. Bilateral involvement is present in half of the affected cases. In younger women (15–50 years), stenosis is due to intrinsic structural abnormalities of the arterial wall caused by fibromuscular dysplasia.² RAS may occur alone (isolated anatomical RAS) or in combination with hypertension (renovascular or essential hypertension), renal

insufficiency (ischemic nephropathy), or both.³ The patients with atherosclerotic renovascular disease are more likely to suffer from stroke, heart failure, or myocardial infarction.² In renovascular disease, revascularization preserves renal function but the effect on blood pressure control is limited. Renal insufficiency should be treated according to the etiology.^{4,5} Improvement in renal function after renal artery stenting is associated with increased survival.⁶ Both the putative risk of progressive disease and benefits of endovascular intervention justify routine screening of patients referred for cardiac catheterization.⁷ Renal artery stenting can be performed safely with nearly uniform technical success without exposing them to significant incremental risk.⁸

Access this article online

Website:

<http://nepjol.info/index.php/AJMS>

DOI: 10.3126/ajms.v13i12.46855

E-ISSN: 2091-0576

P-ISSN: 2467-9100

Copyright (c) 2022 Asian Journal of Medical Sciences



This work is licensed under a Creative Commons Attribution-NonCommercial 4.0 International License.

Address for Correspondence:

Dr. Deepak Arun Khore, Assistant Professor, Department of Medicine, ACPM Medical College, Dhule, Maharashtra, India.

Mobile: 9422236182. E-mail: deep31k@gmail.com

Aims and objectives

The objectives of the study are as follows:

- A) To study the incidence of RAS in suspected coronary artery disease patients.
- B) To study the hemodynamic significance of RAS in patients diagnosed having RAS.
- C) Should patients undergoing coronary angiography be subjected to routine renal angiography during the procedure?

MATERIALS AND METHODS

Type of study

This was a prospective and cross-sectional study.

Sample size

The sample size was 100.

Inclusion criteria

Patients subjected to coronary angiography for suspected coronary artery disease in the sequence they present to the hospital.

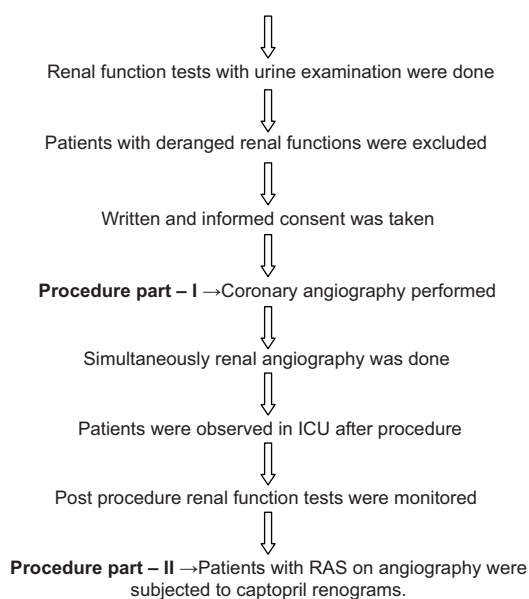
Exclusion criteria

Patients subjected to angiography for causes other than coronary artery disease.

Patients with serum creatinine level greater than 2.0 mg/dl were excluded from consideration because of potential safety concerns about contrast volume administration.

Procedure

Patients with suspected coronary artery disease, that is, patients with angina, acute or old myocardial infarction with E.C.G. or 2D-ECHO cardiography or stress test evidences were admitted



RESULTS

Total 300 patients underwent coronary angiography, out of those 100 met the inclusion. Renal angiography was performed immediately following coronary angiography.

In 100 patients, 84 were males and 16 were females. Out of 84 male patients, 11 patients were found having RAS. Out of 16 female patients, only one was detected with RAS.

Unilateral RAS was seen in 83.33% cases while bilateral RAS was seen in 16.67% cases. More than 70% unilateral RAS was most common.

Significant RAS was seen more commonly in patients with coronary artery disease, hypercholesterolemia, and hypertension. Males were more affected than females.

However, doing renal angiography along with coronary angiography helped to detect 12 patients having RAS, in study population, who were not suspected clinically having renal disease as renal function tests and abdominal sonography were normal in these patients. In our study, there is no statistical significance between occurrences of CAD and RAS.

P=0.97 by Fisher’s exact test

P=0.22 by Chi-square test.

In our study, 8 patients showed three vessel involvement (significant RAS) while only two showed three vessel involvement (insignificant RAS). Two vessel involvement was not seen in any of them.

Out of 12 patients with RAS, ten had significant stenosis (>50%) but on captopril renograms, seven patients showed hemodynamically significant RAS. These were the patients having stenosis of 70% or more on renal angiography. Three patients having 50%–70% RAS on renal angiography were not having hemodynamically significant lesion on captopril renograms. As shown in Table 1, 33.33% patients had 50-75% unilateral RAS and 41.67% had >70% unilateral RAS.

Table 1: Type and percentage of renal artery stenosis

Percentage of RAS	Unilateral RAS	Bilateral RAS	Total
<50% RAS	01	01	02
50–70% RAS	04	00	04
>70% RAS	05	01	06
Total	10	02	12

But, it has no statistical significance as P = 0.87 (i.e. P > 0.05) by Fisher’s exact test, RAS: Renal artery stenosis

Table 2: Association of renal artery stenosis with clinical and angiographic parameters

Parameters	Significant RAS	Insignificant RAS	Without RAS	Total
Males	06	05	73	84
Females	01	00	15	16
Hypertension	06	05	53	64
Diabetes mellitus	05	02	19	26
Smoking	05	05	40	50
Hypercholesterolemia	06	04	36	46
Coronary Artery Disease	06	05	67	78

RAS: Renal artery stenosis

As per Table 2, males outnumbered females in significant RAS. Hypertension, Hypercholesterolemia and smoking was present in 6 patients each of significant RAS.

DISCUSSION

Atherosclerosis is the primary cause of RAS.² As atherosclerosis is diffuse in nature, patients with coronary artery disease are expected to have increased risk of renal artery disease.^{9,10}

The incidence of RAS in patients undergoing coronary angiogram in different studies varies from 3% to 30% and incidence of severe RAS varies from 4% to 15%.¹¹ In our renography procedures, all lesions found were focal and were occurring within proximal third of the renal arteries hence were identified as atherosclerotic in etiology.

In our study, RAS was seen in 12% patients and significant RAS (i.e., stenosis >50%) was found in 10% cases. The mean age of our population was 57±8 years which is a decade lower than Western population.

A study in China, by Shen et al., showed that RAS is frequent finding in patients of CAD, especially with triple vessel disease patients and hypertension being closely related to RAS.¹² Our study shows that RAS is common in patients with triple vessel disease. Hypertension is closely related to it, as statistically significant relation exists between HTN and RAS.

Another study in Germany, by Gross et al., showed that triple vessel disease was more common than single or double vessel disease in patients with RAS and was associated with common atherosclerotic risk factors. They concluded that RAS of any grade of severity was strongly associated with triple vessel disease.¹³

In a study done at Duke University, Durham, by Harding and Smith showed significant RAS in 15% of patients undergoing cardiac catheterization and risk factors found were age and severity of CAD.¹⁴

Table 3: CAD (no. of vessels) and RAS

S. No.	CAD	No. of Patients	Significant RAS	Insignificant RAS
A	Normal Coronary Arteries	22	01	00
B	One Vessel	21	01	00
C	Two Vessel	22	00	00
D	Three Vessel	35	08	02
E	Left Main	13	04	01

RAS: Renal artery stenosis

Our study showed association of RAS with triple vessel disease and common atherosclerotic risk factors.

The observed incidence of RAS was 12% in our study. A study done by Vetrovec et al., on patients with HTN or renal insufficiency (or both) undergoing coronary angiography, the incidence of significant RAS (i.e., stenosis >50%) was 23%.¹¹ The higher rate in this study may reflect the inclusion of patients with serum creatinine levels more than 2.0 mg/dl while our study was restricted to the patients with serum creatinine levels <2.0 mg/dl.

Inclusion of renal angiography added no incremental hazard to coronary angiography in our study. No episode of contrast nephrotoxicity occurred.

The incidence of RAS is lower as compared to the Western data. This discrepancy may be as a result of our population in study being younger (mean age 57 years) than that in Western studies (mean age 65 years). Another reason for higher incidence of RAS in other studies is use of non-selective angiography or selectively studying patients with hypertension and renal failure.^{14,15}

Captopril renogram proved useful test for detection of hemodynamically significant RAS in patients with CAD, though it is not an established method for predicting the result of revascularization. Elliott et al., compared captopril challenge test (plasma renin activity following administration of captopril) with captopril renography and concluded that the latter is more accurate screening test.¹⁶

Table 4: Captopril renography in patients with renal artery stenosis

S. No.	Renal artery stenosis		Captopril renograms	
	Right Side	Left Side	Qualitative Assessment	Quantitative Assessment
1.	40%	30%	Normal uptake bilateral	Normal GFR
2.	No stenosis	80%	Reduced uptake on left side	Low GFR on left side
3.	No stenosis	90%	Reduced uptake on left side	Low GFR on left side
4.	No stenosis	90%	Reduced uptake on left side	Low GFR on left side
5.	80%	No stenosis	Reduced uptake on right side	Low GFR on right side
6.	20%	No stenosis	Normal uptake bilateral	Normal GFR
7.	60%	No stenosis	Normal uptake bilateral	Normal GFR
8.	80%	No stenosis	Reduced uptake on right side	Low GFR on right side
9.	60%	No stenosis	Normal uptake bilateral	Normal GFR
10.	No stenosis	70%	Reduced uptake on left side	Low GFR on left side
11.	60%	No stenosis	Normal uptake bilateral	Normal GFR
12.	60%	75%	Reduced uptake on left side.	Low GFR on left side

We tried to correlate the severity of RAS with risk factors such as age, sex, hypertension, smoking, diabetes mellitus, and hyperlipidemia. We divided the whole study group into two subgroups, one with RAS and the other without RAS and we tried to correlate the risk factors. However there was a trend towards increased incidence of RAS in patients with two or more than two pre-existing risk factors. The correlation of RAS with severity of CAD is shown in Table 3. Some studies show no correlation between severities of CAD with RAS. However, others correlated the presence of CAD.¹⁴ We also found the linear relationship between the severity of RAS and the severity of CAD. In Western studies, there is a strong correlation between RAS and peripheral vascular disease,¹⁷ but peripheral angiography was not a part of our study. Table 4 shows details of 12 patients with RAS. Low Glomerular Filtration Rate was present in 7 out of 12 patients.

According to Richard Stack, routine performance of an aortogram on the “way out” is not an unreasonable option.^{18,19} Hansen and Edward in their study over renovascular disease in elderly, using renal duplex sonography, argued that all of the risk factors were higher in those not screened; hence, introducing a potential “healthy recruit” bias that possibly underestimated the true prevalence of disease.²⁰ Further, in 2003, Khosla and Kunjummen suggested that both the putative risks of progressive disease and benefits of endovascular intervention justify routine screening with renal angiography while doing cardiac catheterization in such patients, with the prospect of stent revascularization when such lesion is identified.⁷

There are no hard national level data about the incidence of renovascular disease in India. The only data available are from referral centers and it varies with the interest of the centre.²¹ In one study carried in Kolkata, Panja and Kumar reported renal pathology incidence of 26.4 % in young (18–30 years of age) hypertensives.²² However, coronary artery disease was not in consideration. In another hospital-based investigation at Chandigarh, renovascular etiology was confirmed angiographically in 3.8% of young hypertensives.²³

Yet, several studies world over have established the potential of this screening for knowing long-term vascular disease progression.^{24,25} We believe a more likely situation is that, the patients with high-grade RAS will benefit from vascular intervention. Having information about the presence, severity, and bilaterality of renovascular disease obtained during angiography for other reasons, such as coronary angiography, offers a promising method for further investigating this disease.

The incremental direct costs of contrast agent and image interpretation are small, especially when compared with the cost of performing additional diagnostic studies, such as magnetic resonance angiography.

Limitations of the study

Intrinsic renal diseases like glomeronephritis, acute tubular necrosis etc was not taken into consideration.

CONCLUSION

Renal angiography should be performed in patients undergoing coronary angiography. Femoral artery should be the preferred access site for coronary angiography to approach renal arteries. The patients with RAS should undergo captopril renography to evaluate the hemodynamic significance of the stenosis.

ACKNOWLEDGMENT

We are thankful to our nurses, ward boys, and juniors who has helped me in carrying out the study.

REFERENCES

1. Hildreth CJ, Lynn C and Glass RM. Blood pressure. JAMA. 2008;300(17):2084.
2. Badr KF and Brenner BM. Renal artery stenosis and ischemic nephropathy: In: 2008 Harrison's Principles of Internal Medicine.

- 17th ed., Vol. 2. USA: The McGraw-Hill Companies. p. 1811.
3. Safian RD and Textor SC. Renal artery stenosis. *N Engl J Med*. 2001;344:431-442.
<https://doi.org/10.1056/NEJM200102083440607>
 4. Olin JW, Topol EJ. Renal Artery Disease: 2002 Textbook of Cardiovascular Medicine. Vol. 2. Philadelphia, USA: Lippincott William and Wilkins; 2002. p. 2140.
 5. Banerjee PS and Das M. In: Parashar SK, editor. Evaluation and Management of Refractory Hypertension, Cardiology. New Delhi: Metro Heart Institute, Lajpat Nagar; 2006. p. 463.
 6. Kennedy DJ, Colyer WR, Brewster PS, Ankenbrandt M, Burket MW, Nemeth NS, et al. Renal insufficiency as a predictor of adverse events and mortality after renal artery stent placement. *Am J Kidney Dis*. 2003;42(5):926-935.
<https://doi.org/10.1016/j.ajkd.2003.06.004>
 7. Khosla S, Kunjummen B, Manda R, Khaleel R, Kular R, Gladson M, et al. Prevalence of renal artery stenosis requiring revascularization in patients initially referred for coronary angiography. *Catheter Cardiovasc Interv*. 2003;58(3):400-403.
<https://doi.org/10.1002/ccd.10387>
 8. Lederman RJ, Mendelsohn FO, Santos R, Phillips HR, Stack RS and Crowley JJ. Primary renal artery stenting: Characteristics and outcomes after 363 procedures. *Am Heart J*. 2001;142(2):314-323.
<https://doi.org/10.1067/mhj.2001.116958>
 9. Frederick JS. Atherosclerosis, Robbins and Cotran Pathologic Basis of Disease. 7th ed., Vol. 2. Philadelphia, Pennsylvania: Saunders, An Imprint Of Elsevier, The Curtis Centre; 2004. p. 520-521.
 10. Rath PC, Agarwala MK, Dhar PK, Ahsan SA, Das NK and Patil N. Renal artery involvement in patients of coronary artery disease undergoing coronary angiography--a prospective study. *J Assoc Physicians India*. 2002;50:523-526.
 11. Vetrovec GW, Landwehr DM and Edverds VL. Incidence of renal artery stenosis in hypertensive patients undergoing coronary angiography. *J Interv Cardiol*. 1989;2(2):69-76.
<https://doi.org/10.1111/j.1540-8183.1989.tb00758.x>
 12. Shen Z, Shang Y and Zhu W. The prevalence of renal artery stenosis in patients with coronary artery disease. *Zhonghua Nei Ke Za Zhi*. 2001;40(8):521-524.
 13. Gross CM, Kramer J, Waigand J, Uhlich F and Dietz R. Renovascular illness: Prevalence and therapy in patients with coronary heart disease, *Z Kardiol*. 2000;89(9):747-753.
<https://doi.org/10.1007/s003920070177s>
 14. Harding MB, Smith LR, Himmelstein SI, Harrison K, Phillips HR, Schwab SJ, et al. Renal artery stenosis: Prevalence and associated risk factors in patients undergoing routine cardiac catheterization. *J Am Soc Nephrol*. 1992;2:1608-1616.
<https://doi.org/10.1681/ASN.V2111608>
 15. Ramirez G, Bugni W, Farber SM and Curry AJ. Incidence of renal artery stenosis in a population having cardiac catheterization. *South Med J*. 1987;80(6):734-737.
<https://doi.org/10.1097/00007611-198706000-00017>
 16. Elliott WJ, Martin WB and Murphy MB. Comparison of two noninvasive screening tests for renovascular hypertension. *Arch Intern Med*. 1993;153(6):755-764.
<https://doi.org/10.1001/archinte.1993.00410060061010>
 17. Iglesias JI, Hamburger RJ, Feldman L and Kaufman JS. The natural history of incidental renal artery stenosis in patients with aortoiliac vascular disease. *Am J Med*. 2000;109(8):642-647.
[https://doi.org/10.1016/s0002-9343\(00\)00605-7](https://doi.org/10.1016/s0002-9343(00)00605-7)
 18. Topol EJ, Calif RM, Isner JM and Prystowsky EN. Textbook of Cardiovascular Medicine. Vol. 2. Philadelphia, USA: Lippincott William and Wilkins; 2002. p. 2146.
 19. Stack R. Renal artery stenosis: Under-diagnosed and under-treated in cardiac patient? *J Invasive Cardiol*. 1999;11(2):103-105; discussion 105-6.
 20. Hansen KJ, Edwards MS, Craven TE, Cherr GS, Jackson SA, Appel RG, et al. Prevalence of renovascular disease in the elderly: A population based-study. *J Vasc Surg*. 2002;36:443-451.
<https://doi.org/10.1067/mva.2002.127351>
 21. Anand MP. Secondary Hypertension Tropical Heart Disease in India. 1st ed. Mumbai: Indian College of Physicians Monogram, Association of Physicians of India; 2005. p. 103.
 22. Panja M, Kumar S Sarkar CN, Sinha DP, Ray S, Chatterjee A, et al. Hypertension in the young in Eastern India. *Indian Heart J*. 1996;48(6):663-666.
 23. Sharma BK, Sagar S, Chugh KS, Sakhuja V, Rajachandran A and Malik N. Spectrum of renovascular hypertension in young in north India: A hospital based study on occurrence and clinical features. *Angiology*. 1985;36(6):370-378.
<https://doi.org/10.1177/0003319785033600606>
 24. Schreiber MJ, Novick AC and Pohl MA. The natural history of atherosclerotic and fibrous renal artery disease. *Urol Clin North Am*. 1984;11(3):383-392.
[https://doi.org/10.1016/S0094-0143\(21\)00203-2](https://doi.org/10.1016/S0094-0143(21)00203-2)
 25. Tollefson DF and Ernst CB. Natural history of atherosclerotic renal artery stenosis associated with aortic disease. *J Vasc Surg*. 1991;14(3):327-331.
[https://doi.org/10.1016/0741-5214\(91\)90084-8](https://doi.org/10.1016/0741-5214(91)90084-8)

Authors Contribution:

DAK- Concept and design of the study, prepared first draft of manuscript, and interpretation and **SDN-** Interpreted the results, reviewed the literature, and manuscript preparation.

Work attributed to:

Department of Medicine, JMFs ACPM Medical College, Dhule - 424 001, Maharashtra, India.

Orcid ID:

Dr. Deepak Arun Khore - <https://orcid.org/0000-0001-6605-1415>
Dr. Sushilkumar Dharamraj Navsare - <https://orcid.org/0000-0002-2054-7017>

Source of Funding: None, **Conflicts of Interest:** None.