

Placenta percreta with bladder invasion – a novel approach for management: A case report



Sushila Kharkwal¹, Divya Jain², Manish Jain³, Shitangsu Kakoti⁴, Divya Pandey⁵

¹Professor and Head, ²Associate Professor, ³Senior Resident, Department of Obstetrics and Gynaecology, ⁴Assistant Professor, Department of Urology, M. L. B. Medical College, Jhansi, Uttar Pradesh, India, ⁵Professor and Head, Department of Urology, SAIMS, Indore, Madhya Pradesh, India

Submission: 11-07-2022

Revision: 03-09-2022

Publication: 01-10-2022

ABSTRACT

Placenta percreta is an obstetric emergency often associated with massive hemorrhage, emergency cesarean section, and peripartum hysterectomy. We present a case of a 30-year-old woman, G4P1L1A2 with placenta percreta managed by an alternative approach. The placenta was left *in situ* along with B/L internal iliac artery ligation during cesarean section and later on delayed subtotal hysterectomy with bladder repair was successfully performed. Placenta percreta spectrum is an obstetrician's dilemma associated with massive hemorrhage and is a potential life-threatening condition for both mother and the baby. Cesarean section with B/L internal iliac artery ligation and delayed hysterectomy may be a reasonable strategy in the most severe cases.

Key words: Placenta accreta spectrum; Placenta percreta; Internal iliac artery ligation

Access this article online

Website:

<http://nepjol.info/index.php/AJMS>

DOI: 10.3126/ajms.v13i10.46640

E-ISSN: 2091-0576

P-ISSN: 2467-9100

Copyright (c) 2022 Asian Journal of Medical Sciences



This work is licensed under a Creative Commons Attribution-NonCommercial 4.0 International License.

INTRODUCTION

Placenta accreta refers to a placenta that is abnormally adherent to the uterus. There are three main entities defined by histological degree of placental invasion into the myometrium, collectively known as placenta accreta spectrum (PAS) disorders. Placenta accreta is defined as superficial invasion, placenta increta as middle layer invasion, and placenta percreta as deep invasion, which is the most severe form of PAS with an incidence of one in 7000. In the accrete syndromes abnormal placental adherence to the myometrium stems in part from partial or total absence of Nitabuch layer. Substantiated data now suggest that accrete syndromes are not solely caused by this anatomical layer deficiency¹. Indeed, the cytotrophoblasts may control decidual invasion through factors such as angiogenesis². Although rare, PAS is one of the most severe pregnancy complications. The incidence of PAS has

dramatically increased due to increasing caesarean section rates. Rising caesarean section rates are a global public health problem³. Studies suggest that antenatal diagnosis may reduce obstetric haemorrhage-related morbidity. Furthermore, in some cases, a morbidly adherent PA can be left *in situ*. Such conservative management may allow delayed removal of the placenta to avoid massive hemorrhage during an attempted forced removal of the adherent placenta. We describe a case, in which placenta percreta was left *in situ* during caesarean section with bilateral internal iliac artery ligation followed later by delayed subtotal hysterectomy and bladder repair.

CASE REPORT

Our patient was a 30-year-old woman, G4P1L1A2 admitted in Emergency, M. L. B. Medical College, Jhansi, Uttar Pradesh, India on May 10, 2022 at 26 weeks

Address for Correspondence:

Dr. Divya Pandey, Senior Resident, Department of Obstetrics and Gynaecology, M. L. B. Medical College, Jhansi - 284 128, Uttar Pradesh, India. **Mobile:** +91-7987174053. **E-mail:** dpandey89338@gmail.com

gestation with the previous one cesarean section 8 years back with history of bleeding per vaginum. She was managed conservatively and ultrasound revealed normal fetal anatomy and placenta previa reaching up to os. She got readmitted at 30 weeks gestation with placenta previa grade 4 with placenta percreta with bladder invasion. Blood workup was done which revealed Hb-9 g/dL, TLC-11700 cells/mm³, platelets – 1.75 lac cells/mm³, pt-35.6 s, and INR-2.54. Intra-muscular dexamethasone was administered using four standard doses of 6 mg 12 h apart. One unit PRBC was transfused and four units FFP and three units PRBC arranged. An emergency cesarean section was performed 2 days later for fetal distress and placenta was left *in situ* and bilateral internal iliac artery ligation was done. The weight of the newborn was 1.2 kg. The cesarean section was performed under general anesthesia. A classical uterine incision was used for extraction of the fetus to avoid the morbidly adherent low placenta. The internal iliac arteries were ligated. The placenta was left *in situ* due to placenta previa with severe placenta percreta with bladder invasion and there was no spontaneous separation of placenta. Two units of PRBC and two units of FFP was transfused. On 3rd post-operative day, she developed acute respiratory distress syndrome. Her D-dimer was found more than 10 with deranged liver function and coagulation profile. She was managed in ICU, recovered uneventfully. MRI Pelvis at 8th day showed the placenta left *in situ* with placenta percreta and bladder invasion. She was managed by multidisciplinary team of obstetricians, urologist, surgeons, and radiologists. She was planned for elective subtotal hysterectomy. Pre-operative cystoscopy guided ureteric catheterization was done. On 15th post-operative day, subtotal hysterectomy was performed. Her uterus was still relatively large with prominent and bulging isthmic portion and deep myometrial and bladder invasion, there was profuse bleeding intraoperatively. During separation of placenta, bladder was thinned out, which was repaired by urologist. Intraoperatively, two units of packed red blood cells transfusion were done and she was kept on vasopressors, broad spectrum antibiotics and two units of blood were transfused postoperatively. She was kept on sustained catheterization for 14 days. Our patient recovered and she was discharged on the ninth post-operative day with her newborn weighing 1.6 kg in good condition (Figures 1 and 2).

DISCUSSION

PAS causes considerable maternal morbidity and mortality and is the major indication for emergency peri-partum hysterectomy. Risk factors associated with

placenta percreta are previous cesarean section, multiple pregnancies, advanced maternal age, placenta praevia, dilatation and curettage, endometritis, and repetitive abortions. The greater risk conveyed by previous surgical uterine trauma may be partially explained by enhanced vulnerability to trophoblast invasion.⁴ Indeed, accruing evidence suggests that cesarean scar pregnancy (CSP) and accrete syndromes lie on a spectrum and that CSP is a precursor, as both share the same histopathology.⁵ Maternal morbidity and mortality associated with PAS are mainly caused by massive obstetric hemorrhage or emergency hysterectomy, and PAS is often diagnosed during delivery or immediately postpartum, leading to an obstetric emergency.

Antenatal confirmation of PA diagnosis is often difficult. Some studies suggest that sonography might detect only around 33% of cases of placenta accrete/increta. Placental lacunae (which appear as intra-placental sonolucent spaces) and disruption of the interface between the bladder wall-uterine serosa (bladder

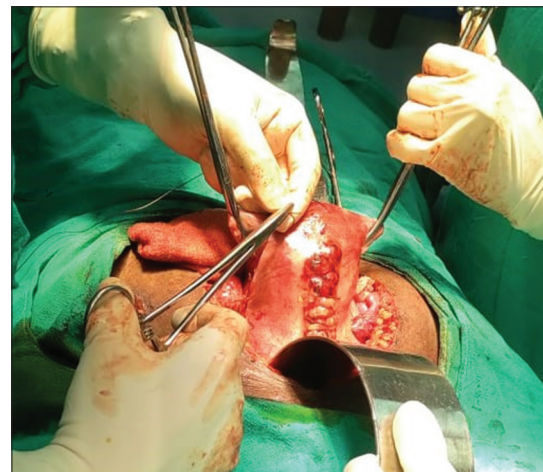


Figure 1: Subtotal hysterectomy being performed

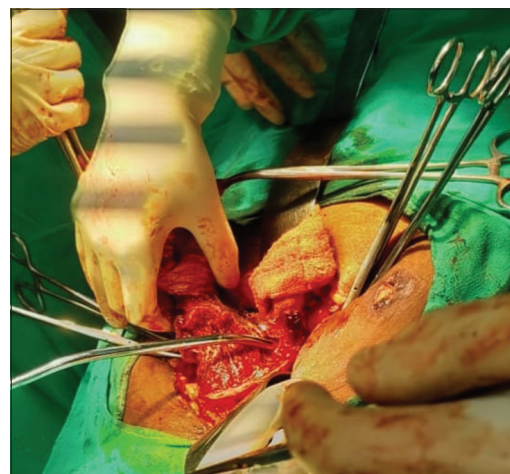


Figure 2: The deep placental invasion into the posterior bladder wall

line) are the most reliable diagnostic sonographic findings. Color flow Doppler demonstrating turbulent (“chaotic”) flow and/or bridging vessels are valuable confirmatory findings. Magnetic resonance imaging may be performed to clarify the diagnosis. Although, gadolinium is usually not added during pregnancy, this contrast may enhance images.⁶ Diagnosis is confirmed by histopathology.

The management is usually an elective cesarean delivery and hysterectomy, but this approach often causes massive hemorrhage and may cause injury of adjacent organs due to the morbidly adherent placenta. Women in whom hysterectomy is avoided have an estimated 20% incidence of recurrence.⁷ Some studies suggest that leaving placenta *in situ* lowers the risk for subsequent hysterectomy and may hence be an option in cases when emergency hysterectomy is considered too risky or fertility needs to be preserved.⁸ Delayed transvaginal removal of the placenta has also been described.⁹ Conservative management is exclusively used in rare setting of the adjacent organ involvement such as bowel or bladder. Chemotherapeutic agents, especially Methotrexate, have been used with success in several patients. Furthermore, transcatheter embolization has been utilized. In a case series of seven patients, conservative management in two cases failed and one case required delayed hysterectomy while bleeding continued per vaginally in the other case and it emphasizes to check for PV bleed intraoperatively if the placenta is left *in situ*.¹⁰

We describe a severe case of placenta percreta, in which the placenta was left *in situ* during cesarean section and a classical uterine incision was used for extraction of the fetus to avoid the morbidly adherent low placenta with bilateral internal iliac artery ligation. The placenta was left *in situ*, because spontaneous separation of placenta did not take place. Methotrexate could not be given to this patient as her liver function tests and coagulation profile were deranged. Furthermore, she developed pneumonia post first surgery. She was planned for subtotal hysterectomy after she recovered after 2 weeks to avoid any emergency situation later. This case suggests that in some cases with placenta accreta and percreta, leaving placenta *in situ* may be an alternative approach allowing delayed hysterectomy as this management option may be safer than primary hysterectomy since delayed hysterectomy may be easier to perform than emergency peripartum hysterectomy due to placental involution and decreased uterine vascularity. Further, B/L internal iliac artery ligation along with cesarean section may prevent catastrophic hemorrhage in case placenta starts separating in post-operative period.

CONCLUSION

Placenta percreta is an obstetric emergency often associated with massive hemorrhage and is a potential life-threatening condition for both mother and the baby. This case highlights need of detailed antenatal placental evaluation as this would enable prenatal screening, diagnosis and an appropriate plan for delivery can be developed. Pre-operative preparation, including availability of blood components for transfusion and surgical and radiological expertise will improve the maternal and neonatal outcome. Classical cesarean section with B/L internal iliac artery ligation followed by delayed hysterectomy may be a reasonable management strategy in the most severe cases.

CONSENT

Written informed consent was taken from the patient for publication of the case report and any accompanying images. Ethical clearance was approved by the Ethical Committee.

REFERENCES

- Duzyj CM, Barishansky S, Khan S, Chekmareva M, Wang B, Rosen T, et al. Evidence of active wound remodelling at the site of trophoblast invasion in placenta accrete. *Am J Obstet Gynecol.* 2017;216(1):S99-S100. <https://doi.org/10.1016/j.ajog.2016.11.051>
- Goh WA and Zalud I. Placenta accreta: Diagnosis, management and the molecular biology of the morbidly adherent placenta. *J Matern Fetal Neonatal Med.* 2016;29(11):1795-800. <https://doi.org/10.3109/14767058.2015.1064103>
- Dhakal-Rai S, van Teijlingen E, Regmi PR, Wood J, Dangal G and Dhakal KB. Factors contributing to rising cesarean section rates in South Asian countries: A systematic review. *Asian J Med Sci.* 2022;13(2):143-174. <https://doi.org/10.3126/ajms.v13i2.40904>
- Jauniaux E, Collins S and Burton GJ. Placenta accreta spectrum: Pathophysiology and evidence based anatomy for prenatal ultrasound imaging. *Am J Obstet Gynecol.* 2018;218(1):75-87. <https://doi.org/10.1016/j.ajog.2017.05.067>
- Happe SK, Rac MW, Moschos E, Wells CE, Wells JS, McIntire DD, et al. Prospective Assessment of Morbidly Adherent Placenta with First Trimester Ultrasound. Presented at Annual Meeting of the Society of Maternal Fetal Medicine; 2018.
- Millischer AE, Solomon LJ, Porcher R, Brasseur-Daudry M, Gourdiere AL, Hornoy P, et al. Magnetic resonance imaging for abnormally invasive placenta: The added value of intravenous gadolinium injection. *BJOG.* 2017;124(1):88-95. <https://doi.org/10.1111/1471-0528.14164>
- Roeca C, Little SE and Carusi D. Pathologically diagnosed accrete and haemorrhagic morbidity in a subsequent pregnancy. *Obstet Gynecol.* 2017;129(2):321-326. <https://doi.org/10.1177/1093526617741071>
- Sentilhes L, Kayem G, Ambroselli C, Provansal M, Fernandez H, Perrotin F, et al. Fertility and pregnancy outcomes following

- conservative treatment for placenta accreta. *Hum Reprod.* 2010;25(11):2803-2810.
<https://doi.org/10.1093/humrep/deq239>
9. Descargues G, Clavier E, Lemerrier E and Sibert L. Placenta percreta with bladder invasion managed by arterial embolization and manual removal after cesarean. *Obstet Gynecol.* 2000;96(5 Pt 2):840.
[https://doi.org/10.1016/s0029-7844\(00\)00985-6](https://doi.org/10.1016/s0029-7844(00)00985-6)
10. Choudhary D, Nigam A, Yadav R, Choudhary S and Raghunandan C. Placenta accrete: Obstetricians nightmare, a case series of seven patients. *NJOG.* 2012;7(3):56-58.
<https://www.dx.doi.org/10.3126/njog.v7i1.8839>

Authors Contribution:

SK- concept and design of the study, prepared first draft of manuscript; **DJ-** Interpreted the results; reviewed the literature and manuscript preparation; **MJ, SK, DP-** Concept, coordination, preparation of manuscript and revision of the manuscript.

Work attributed to:

M. L. B. Medical College, Jhansi - 284 128, Uttar Pradesh, India.

ORCID ID:

Dr. Sushila Kharkwal - <https://orcid.org/0000-0001-8753-4635>

Dr. Divya Jain - <https://orcid.org/0000-0002-2500-3422>

Dr. Manish Jain - <https://orcid.org/0000-0002-8547-2116>

Dr. Shitangsu Kakoti - <https://orcid.org/0000-0003-4862-1642>

Dr. Divya Pandey - <https://orcid.org/0000-0002-0657-1707>

Source of Support: Nil, **Conflict of Interest:** None declared.