

# Neonatal versus postneonatal presentation of intestinal malrotation: A retrospective cross-sectional study in a tertiary care hospital at Hyderabad, India



Srinivas Srirampur<sup>1</sup>, Kavimozhy Ilakkiya Poyyamozy<sup>2</sup>, Suresh Kumar Thanneeru<sup>3</sup>, Nagarjuna Kumbha<sup>4</sup>

<sup>1</sup>Associate Professor, <sup>2</sup>Senior Resident, <sup>4</sup>Professor, Department of Paediatric Surgery, Gandhi Medical College and Hospital, Secunderabad, Telangana, <sup>3</sup>Assistant Professor, Department of Paediatric Surgery, AIIMS, Bhopal, Madhya Pradesh, India

Submission: 06-07-2022

Revision: 26-10-2022

Publication: 01-12-2022

## ABSTRACT

**Background:** Malrotation commonly presents in neonates with bilious vomiting. It may also present in post neonatal age group with vague symptoms such as chronic abdominal pain, vomiting, and failure to thrive. These indistinct symptoms also result in delay of diagnosis. **Aims and Objectives:** This study is done with an objective to know whether age of presentation in malrotation determines morbidity and mortality. **Materials and Methods:** This is a retrospective study conducted in Gandhi medical college and Hospital, Hyderabad, from 2017 to 2020, based on the records of 50 patients who were diagnosed to have malrotation. The differences in clinical presentations, diagnosis, management, and outcomes were analyzed with respect to age. **Results:** Children who presented in neonatal period had classical symptoms ( $P < 0.00001$ ) and early diagnosis ( $P < 0.0239$ ). Children who presented later ( $> 1$  month of age) had higher incidence of atypical symptoms ( $P < 0.00001$ ) and delay in diagnosis ( $P < 0.0239$ ) compared to neonatal age group. Plain X-ray abdomen is readily diagnostic in neonatal age group ( $P < 0.0004$ ) and diagnosis was confirmed by contrast study, whereas in older children, plain abdomen X-ray findings were not always distinct and most of them needed contrast series to reach definitive diagnosis. The incidence of bowel gangrene and mortality was not statistically significant ( $P$  value of 1) between neonatal and post neonatal groups. **Conclusion:** In post neonatal age group, lack of classical presentation may lead to difficulty in diagnosing malrotation, but may not have significant difference in terms of morbidity and mortality. Considering malrotation early in differential diagnosis leads to timely intervention even in older age group children.

**Key words:** Bilious vomiting; Intestinal malrotation; Ladd's procedure

## INTRODUCTION

Malrotation with volvulus is an important neonatal surgical emergency.<sup>1</sup> The prompt and timely diagnosis can be made in neonates due to classical symptoms and signs and confirmed with relevant radiological investigations. However, vague presentation in older children makes it not only difficult for the physician to consider the diagnosis of this rotational abnormality, but also causes delay in diagnosis

of the same. Neonatal presentation is usually acute with bilious emesis and also with less frequent symptoms such as gastrointestinal (GI) hemorrhage and distension, whereas post neonatal children have indistinct symptoms<sup>1,2</sup> such as chronic abdominal pain or abdominal migraine, recurrent vomiting, weight loss, failure to thrive, and other non-specific gastrointestinal complaints. Irrespective of the age of presentation, surgery is the treatment of choice<sup>2</sup> that involves derotation of volvulus if present, release

### Access this article online

#### Website:

<http://nepjol.info/index.php/AJMS>

DOI: 10.3126/ajms.v13i12.46460

E-ISSN: 2091-0576

P-ISSN: 2467-9100

Copyright (c) 2022 Asian Journal of Medical Sciences



This work is licensed under a Creative Commons Attribution-NonCommercial 4.0 International License.

### Address for Correspondence:

Dr. Kavimozhy Ilakkiya Poyyamozy, Senior Resident, Department of Paediatric Surgery, Gandhi Medical College and Hospital, Secunderabad - 500 025, Telangana, India. **Mobile:** +91-8828499660. **E-mail:** kavimozhy86@gmail.com

of Ladd's bands, straightening of duodenum, widening of mesentery, appendicectomy, and placing the bowel in position of non-rotation.

There are very few studies which compare clinical presentation, diagnosis, treatment and outcomes of malrotation in neonatal and post neonatal age groups. In this study, malrotation is analyzed for its clinical presentation, radiological diagnosis, operative procedures, morbidity, and mortality with respect to the age at the time of the diagnosis

### Aims and objectives

The study is done to know whether age of presentation in malrotation determines morbidity and mortality in pediatric patients.

## MATERIALS AND METHODS

Fifty children with diagnosis of malrotation treated for 4 years from January 2016 to December 2019 were reviewed retrospectively of the case records treated at Gandhi Hospital, Hyderabad. The study was conducted after the Institutional Ethical Committee approval. Patient data were taken from the department archives and medical record department. Patients were divided into two groups as neonatal age group (comprised of patients who were less than 30 days of age, n=38) and post neonatal age group (comprised those who were above 30 days, n=12). Their symptoms and signs, modalities used to diagnose, management, and outcomes with respect their age were studied. Patients who presented with bilious vomiting, scaphoid abdomen, and intolerance to feeds with normal passage of meconium at birth were considered to have typical symptoms. Patients who presented with other symptoms such as non-bilious vomiting, failure to thrive, weight loss, and early satiety with abdominal bloating were considered to have atypical symptoms. Most of these children who presented in the post neonatal age group came to pediatric surgery outpatient department late after seeking consultation from other specialties. All patients were subjected to Plain X-ray abdomen. The presence of single or double bubble air shadow with paucity of gas downward or small bowel gas shadows predominantly on the right side of the abdomen was considered diagnostic. Upper GI contrast series was performed in all cases to confirm the diagnosis which showed findings of malrotation, that is, duodenojejunal (DJ) flexure on the right side (Figure 1). Positive findings suggestive of malrotation were seen in all cases irrespective of age.

Patients were managed surgically with right transverse supraumbilical muscle cutting incision – derotation of volvulus if present, release of Ladd's bands, straightening

of duodenum, widening of mesentery, prophylactic appendicectomy, and placing the bowel in position of non-rotation (Figure 2).

We noticed significant mesenteric lymphadenopathy in some of the patients who presented late in childhood. In case bowel, resection and anastomosis was performed. In cases of short gut syndrome, total parenteral nutrition was considered. Post-operative feeds were gradually initiated after 72 h generally. Patients were discharged on 9<sup>th</sup>–14<sup>th</sup> post-operative day. Follow-up of these patients was done over telephonic conversation to know the readmissions, reoperations, or recurrent obstructions, if any. Patients beyond 12 years, life-threatening congenital anomalies, and patients who were not in follow-up were excluded from the study.

### Statistical analysis

The categorical variable data were reviewed in terms of their analysis in SPSS using Fischer Exact test in 2×2 contingency tables. P value of <0.05 was considered significant. Data were analyzed through IBM SPSS version 26, 64 bit, and release 26.0.0.0

## RESULTS

Of the 50 cases, 38 patients were in neonatal age group and 12 patients were in post neonatal age group. In the neonatal age group, 21 (55%) were males and in post neonatal age group, 7 (58%) were males. All neonates had presented with classical described symptoms (100%), whereas in post neonatal group, 3 (25%) presented with classical symptoms and 9 (75%) presented with indistinct symptoms (Figure 3). The mean delay in diagnosis after seeking pediatric surgical consultation and with the above clinical features at presentation was 2 days in neonatal age group and 4 days in post neonatal age group.

Plain X-ray abdomen was diagnostic in 100% of the cases in neonatal age group and 76.6% in post neonatal age group. Intraoperative findings in these patients included midgut volvulus in 26 (68.4%) of neonatal age group and 4 (33.3%) of post neonatal age group patients (Figure 4). Obstruction only due to Ladd's bands was noted in 12 (31.6%) of neonatal age group and no Ladd's bands [0%] were seen in post neonatal age group. Features of chronic small bowel obstruction such as presence of lacteals, thickened bowel wall, and mesenteric nodes were not noted in neonatal age group and were seen in 8 (66.6%) in post neonatal age group. Gangrene of the small bowel was noted in 3 (7.8%) of the neonatal age group and 1 (8.3%) of older age group patients.

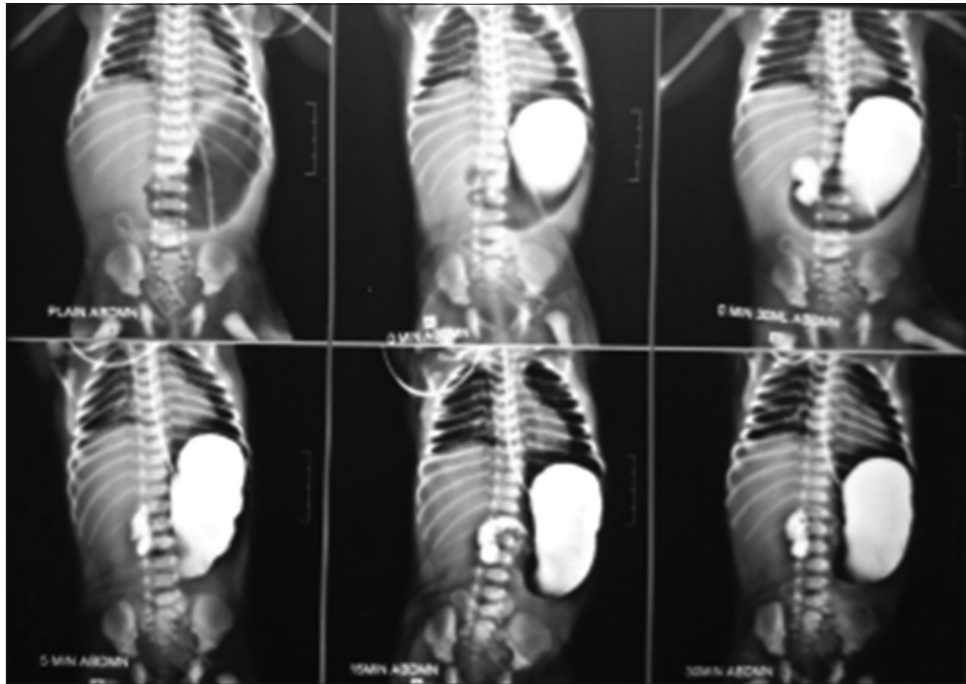


Figure 1: Upper GI contrast series depicting the abnormal positioning of the DJ flexure

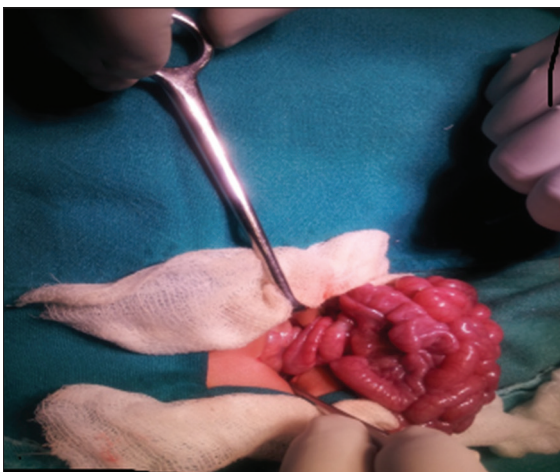


Figure 2: Neonate presented malrotation with volvulus

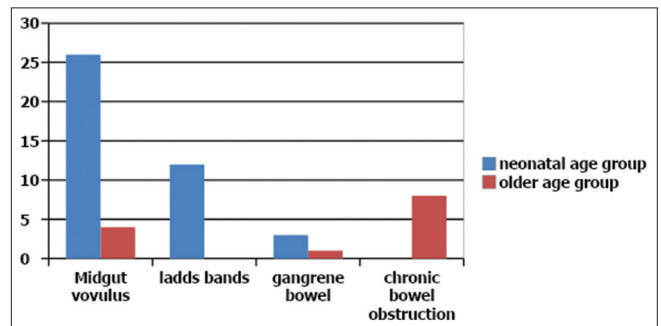


Figure 4: Operative findings. X-Axis – operative findings, Y-Axis – number of cases

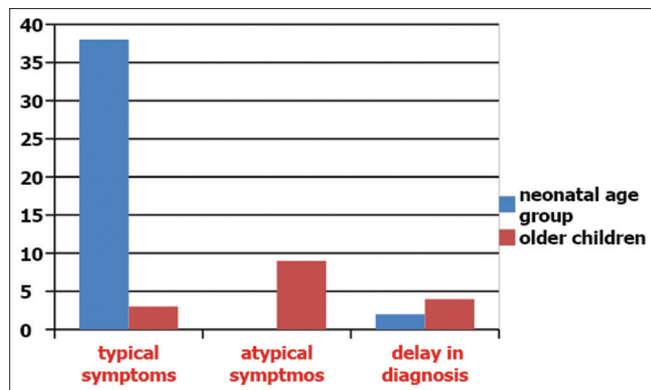


Figure 3: Clinical presentation in the study group. X-Axis – clinical presentation, Y-Axis – number of cases

Post-operative mortality seen in neonatal age group was 4 (10.5%) and single (8.3%) mortality in post neonatal age group. On follow-up, seven cases were readmitted for recurrent intestinal obstruction in neonatal age group and two of them were reoperated. In older age group, there were no readmissions and reoperations within the study period.

Post-operative complications and in hospital mortality have been considered as adverse surgical outcomes to fit into the multiple logistic regression analysis (Table 1). In four cases (two neonates, one infant, and one child of 3 years of age) who presented with shock, there was midgut gangrene due to complete volvulus. Ladd's procedure was done, but gangrenous gut was not resected and was returned back to abdomen and abdomen closed. However, all four cases expired during post-operative period due to sepsis. Hence,

**Table 1: Comparison of variables in the study group**

Features	Variables	Neonatal age group	Post neonatal age group	Fischer exact test with significance level of <0.05
Demographics	No of patients	38 (76%)	12 (24%)	
	Male	21 (55%)	7 (58%)	1
	Female	17 (45%)	5 (42%)	
Clinical Presentation	Typical Symptoms	38 (100%)	3 (25%)	<0.00001
	Atypical symptoms	0	9 (75%)	<0.00001
	Mean delay in diagnosis	2 days	4 days	
Radiological investigations	Plain X-ray abdomen			
	Features of partial duodenal obstruction	38 (100%)	7 (58.3%)	<0.00004
	Multiple air fluid levels	-	1 (8.3%)	
Contrast series	Inconclusive	0	4 (33.3%)	<0.0021
	Number of cases contrast series ordered	38 (100%)	12 (100%)	1
	Number of cases diagnosed with contrast study	38 (100%)	12 (100%)	1
Intraoperative findings	Midgut volvulus	26 (68.4%)	4 (33.3%)	0.044
	Obstruction due to Ladd's bands alone	12 (31.6%)	0	0.047
	Gangrene bowel	3 (7.8%)	1 (8.3%)	1
Post op outcome and follow-up	Features of chronic bowel obstruction	0	8 (66.7%)	<0.00001
	Readmissions	5	0	0.3192
	Reoperation for intestinal obstruction	2	0	1
	Death	4 (10.5%)	1 (8.3%)	1

in our study, the incidence of midgut volvulus with gangrene was 6%. During post-operative period, patients were allowed oral feeds after 72 hours once they started passing stool. Patients were discharged on 9<sup>th</sup>-14<sup>th</sup> post-operative day. Wound infection as seen in two patients was managed by daily dressing. On follow-up, patients were reported to be doing well and gaining weight. Post-operative adhesive obstruction was seen in two cases which was managed conservatively.

## DISCUSSION

Classically, malrotation presents in a neonate with sudden onset of bilious vomiting, with or without abdominal distension and mandates evaluation for the same.<sup>1</sup> Diagnosis is confirmed with upper GI contrast radiograph that demonstrates DJ flexure on the right side. When the same rotational abnormality occurs in post neonatal children, it presents with chronic symptoms of reiterative pain abdomen, non-bilious vomiting with failure to thrive, and other non-specific abdominal symptoms. The obscured presentations delay the diagnosis in the post neonatal age group and belated presentation to the pediatric surgeon. Regardless of the age of presentation, surgery is the treatment of choice<sup>2</sup> that involves derotation of volvulus if present, release of Ladd's bands, straightening of duodenum, widening of mesentery, appendectomy, and placing the bowel in position of non-rotation.

As noted by Ladd in 1932, malrotation is a "condition rare enough that it is likely to escape the mind, and it is common enough to be important".<sup>2</sup> This advice is especially true in older patients. The subtle presentation may lead to unnecessary or ineffective treatment. A high index of

suspicion is required to prevent a delay in diagnosis, counsel patients effectively, and improve outcomes.

In our study, all neonatal cases presented with typical symptoms and most of post neonatal cases presented with atypical symptoms (75%). This is in correlation with other similar studies such as Anand et al., (70%)<sup>3</sup>, Yanez and Spitz (81%),<sup>4</sup> and Durkin et al., (70%).<sup>5</sup> Diagnosis of malrotation is confirmed with UGI contrast X-ray.<sup>6,7</sup> The risk of contrast aspiration in a high intestinal obstruction has been over emphasized, and in our study, aspiration was not noted. The added advantage of upper GI contrast is, it can rule out intrinsic duodenal obstruction. Plain X-ray abdomen may not be confirmatory. Ultrasound abdomen can be helpful in demonstrating Whirlpool sign<sup>7,8</sup> and useful to confirm volvulus with intestinal malrotation which is more obvious on color Doppler.<sup>8</sup> Contrast-enhanced computed tomography (CECT) can also demonstrate whirlpool sign and dilated duodenum. In our study, most of the neonates had classical plain X-ray findings and plain X-ray was not so conclusive in post neonatal age group. UGI contrast was done to prove the diagnosis in both the groups. This is in comparison with other studies.<sup>6</sup> In a study done by Anand *et.al.*,<sup>3</sup> neonates were mainly diagnosed with USG abdomen and older children with contrast study. In a study done by Yanez and Spitz,<sup>4</sup> most of the patients were diagnosed with contrast study and few patients were diagnosed on plain X-ray abdomen alone.

Durkin et al.,<sup>5</sup> used CECT abdomen for older patients and UGI contrast study in younger ones.

Older children were evaluated with unrelated investigations due to their vague complaints<sup>9,10</sup> most of the time, in



reiterate manner and are procrastinated before reaching out a pediatric surgeon with further delay in diagnosis. Mean delay in diagnosis in our study was 2 days in neonatal age group and 4 days in older age group. Our observation again highlights the intuitiveness needed in evaluating such patients.<sup>10</sup>

All our patients underwent Ladd's procedure that also involves appendectomy as they can cause diagnostic dilemma during appendicitis which can arise in future. However, many recent studies advocated preservation of appendix.<sup>11</sup>

There is significantly high incidence of midgut volvulus (68%) and Ladd's bands (33%) causing obstruction in neonatal age group compared to post neonatal age group, but the incidence of bowel gangrene was not significant in our study. In a study done by Yanez and Spitz,<sup>4</sup> midgut volvulus was seen in 14% of children in older group with no incidence of bowel gangrene. Study done by Rattan *et al.*,<sup>12</sup> showed 6% of neonates and 6% of older children had bowel gangrene. Ladd's procedure can be performed laparoscopically<sup>13</sup> even in neonates and older children safely after careful selected patient selection if anatomy is definable in the case series of Reddy *et al.*<sup>14</sup> More prospective studies need to be performed to compare open and laparoscopic Ladd's procedure in young children and in our series, all underwent open procedure.

The risk of intestinal obstruction due to adhesions as with any other laparotomy is 4%. Readmission and reoperation were found only in neonatal group in our study with rates of 5% and 2%, respectively. Anand *et al.*,<sup>3</sup> had 36% readmission rates and 10% re-exploration rate in older patients, but no mention was done on neonates. Raitio *et al.*,<sup>15</sup> reported significantly higher emergency reoperation rate in older children. Zhu *et al.*,<sup>13</sup> in their study, noted that most of the reoperations were due to adhesions or recurrent volvulus and recurrent volvulus was more common after laparoscopic approach. Mortality rate in neonates and post neonatal group is 10% and 8%, respectively, in our study in comparison to Raitio *et al.*,<sup>15</sup> who had reported 2.5% mortality in the neonates and none in older age.

### Limitations of the study

Limitations, in our study, were small sample size of patient and brief period of follow-up.

## CONCLUSION

The obscure presentation in post neonatal children can cause difficulty and delay in diagnosing malrotation, but

older age may not have significant difference in terms of morbidity and mortality. Considering malrotation early in differential diagnosis and timely intervention can show prompt results even in older age group children.

## ACKNOWLEDGMENT

We would like to thank the medical records department and nursing staff for their help in data collection.

## REFERENCES

1. Kimura K and Loening-Baucke V. Biliary vomiting in the newborn: Rapid diagnosis of intestinal obstruction. *Am Fam Physician*. 2000;61(9):2791-2798.
2. Ashcraft KW, Holcomb GW, Murphy J and Ostlie DJ. *Ashcraft's Pediatric Surgery*. 5<sup>th</sup> ed. 2010. p 416-424. <https://doi.org/10.1016/B978-1-4160-6127-4.00032-X>
3. Anand U, Kumar R, Priyadarshi RN, Kumar B, Kumar S and Singh VP. Comparative study of intestinal malrotation in infant, children, and adult in a tertiary care center in India. *Indian J Gastroenterol*. 2018;37(6):545-549. <https://doi.org/10.1007/s12664-018-0914-1>
4. Yanez R and Spitz L. Intestinal malrotation presenting outside the neonatal period. *Arch Dis Child*. 1986;61(7):682-685. <https://dx.doi.org/10.1136/adc.61.7.682>
5. Durkin ET, Lund DP, Shaaban AF, Schurr MJ and Weber SM. Age-related differences in diagnosis and morbidity of intestinal malrotation. *J Am Coll Surg*. 2008;206(4):658-663. <https://doi.org/10.1016/j.jamcollsurg.2007.11.020>
6. Nagdeve NG, Qureshi AM, Bhingare PD and Shinde SK. Malrotation beyond infancy. *J Paediatr Surg*. 2012;47(11):2026-2032. <https://dx.doi.org/10.1016/j.jpedsurg.2012.06.013>
7. Strouse PJ. Disorders of intestinal rotation and fixation ("malrotation"). *Pediatr Radiol*. 2004;34(11):837-851. <https://doi.org/10.1007/s00247-004-1279-4>
8. Zhang W, Sun H and Luo F. The efficiency of sonography in diagnosing volvulus in neonates with suspected intestinal malrotation. *Medicine (Baltimore)*. 2017;96(42):e8287. <https://doi.org/10.1097/MD.00000000000008287>
9. Maxson RT, Franklin PA and Wagner CW. Malrotation in the older child: Surgical management, treatment, and outcome. *Am Surg*. 1995;61(2):135-138.
10. Miller AJ, Rode H and Cywes S. Malrotation and volvulus in infancy and childhood. *Semin Pediatr Surg*. 2003;12(4):229-236. <https://doi.org/10.1053/j.sempedsurg.2003.08.003>
11. Davidson JR, Eaton S and De Coppi P. Let sleeping dogs lie: To leave the appendix at the time of ladd's procedure. *J Pediatr Surg*. 2018;53(1):205-207. <https://doi.org/10.1016/j.jpedsurg.2017.09.003>
12. Rattan KN, Bhardwaj H, Singh J and Bansal S. Intestinal malrotation in childhood-10 years experience at a tertiary centre. *Trop Gastroenterol*. 2017;38(3):167-170. <https://dx.doi.org/10.7869/tg.424>
13. Zhu H, Zheng S, Alganabi M, Peng X, Dong K, Pierro A, *et al.* Reoperation after Ladd's procedure in the neonatal period.

- Pediatr Surg Int. 2019;35(1):117-120.  
<https://doi.org/10.1007/s00383-018-4382-6>
14. Reddy AS, Shah RS and Kulkarni DR. Laproscopic Ladd's procedure in children: Challenges, results and problems. J Indian Assoc Pediatr Surg. 2018;23(2):61-65.  
[https://doi.org/10.4103/jiaps.JIAPS\\_126\\_17](https://doi.org/10.4103/jiaps.JIAPS_126_17)
15. Raitio A, Green P, Fawcner-Corbett D, Wilkinson D and Baillie C. Malrotation: Age-related differences in reoperation rate. Eur J Pediatr Surg. 2016;26(01):34-37.  
<https://doi.org/10.1055/s-0035-1563677>

**Authors Contribution:**

**SS-** Concept and study design, coordination, and prepared first draft of manuscript, **KIP-** Interpretation results; reviewed the literature; and manuscript preparation; **SKT-** statistical analysis, and interpretation; and **KN-** Concept, Revision of manuscript.

**Work attributed to:**

Gandhi Medical College and Hospital, Secunderabad - 500 025, Telangana, India.

**Orcid ID:**

Dr. Srinivas Srirampur - <https://orcid.org/0000-0003-1581-9679>

Dr. Kavimozhy Ilakkiya Poyyamozhy - <https://orcid.org/0000-0001-6978-2993>

Dr. Suresh Kumar Thanneeru - <https://orcid.org/0000-0002-0897-4518>

Dr. Nagarjuna Kumbha - <https://orcid.org/0000-0001-5912-6132>

**Source of Funding:** None, **Conflicting Interest:** None