

Comparative evaluation of “in-the-bag” intraocular lens implantation with cionni ring versus pars plana lensectomy–vitrectomy with anterior chamber IOL implantation in subluxated lenses in pediatric eyes



Sweta Singh¹, Anju Rastogi², Jaidrath Kumar³, Vartika Srivastava⁴

¹Assistant Professor, Department of Ophthalmology, AL-Falah School of Medical Science and Research Center, Faridabad, Haryana, India, ²Director Professor, Department of Ophthalmology, Guru Nanak Eye Center, New Delhi, India, ³Senior Consultant, Department of Ophthalmology, Sarvodaya Hospital and Research Center, Faridabad, Haryana, India, ⁴Senior Optometrist, Sarvodaya Hospital and Research Center, Faridabad, Haryana, India

Submission: 19-06-2022

Revision: 29-08-2022

Publication: 01-10-2022

ABSTRACT

Background: Subluxation of the crystalline lens has various surgical management options. In moderate zonular dialysis, the capsular bag may be preserved and used for intraocular lens (IOL) implantation using a capsular tension ring or Cionni ring or Capsular tension segment. It is technically demanding and associated with high incidence of complications such as IOL decentration, dislocation, and posterior capsular opacification (PCO). Advantages of the combined pars plana lensectomy–vitrectomy (PPL/PPV) with anterior chamber IOL (ACIOL) approach include a closed ocular surgical system, minimal corneal trauma, limited iris trauma, and good vitreous control. Therefore, in this study, we aim to study the outcomes of in-the-bag IOL implantation with Cionni ring versus PPL/PPV with ACIOL in subluxated lenses in children. **Aims and Objectives:** The aims of this study were to compare “in-the-bag” IOL implantation with Cionni ring versus PPL/PPV with ACIOL implantation in subluxated lenses in children. **Materials and Methods:** In this prospective, comparative, and interventional case series, 20 eyes (18 children, 8–18 years) with 90–210° subluxation were randomly allocated into two groups (ten eyes each). Group A underwent single eyelet Cionni Ring with in-the-bag PCIOL implantation and Group B underwent PPL/PPV with ACIOL. Outcome measures included best-corrected visual acuity (BCVA), endothelial cell count (ECC), intraocular pressure, fundus evaluation, and intraoperative/post-operative complications. **Results:** The etiology of subluxation included trauma (40%), Marfan’s syndrome (20%), myopia (20%), and others (20%). In Group A, intraoperative difficulties were encountered in capsulorrhexis, irrigation-aspiration, and increased duration of surgery. Two eyes in Group B had intraoperative lens fragment drop in vitreous. At 3 months, no statistically significant difference in BCVA was noted. About 90% eyes in Group A and 80% eyes in Group B had final BCVA of $\geq 6/18$. ECC and PCO were significantly higher in Group A at 3 months. **Conclusion:** : Implantation of planned open-loop ACIOL is a viable surgical option in large subluxation and good pre-operative ECC.

Key words: Anterior chamber intraocular lens; Cionni ring; Pars plana lensectomy; Subluxation

INTRODUCTION

Subluxated crystalline lenses are commonly encountered, and they often create management problems. Lens

displacement may be traumatic, hereditary, and spontaneous. Subluxation of the lens occurs in various disorders, including Marfan’s syndrome (MFS), homocystinuria, sulfite oxidase deficiency, and Weill-Marchesani syndrome.

Access this article online

Website:

<http://nepjol.info/index.php/AJMS>

DOI: 10.3126/ajms.v13i10.45937

E-ISSN: 2091-0576

P-ISSN: 2467-9100

Copyright (c) 2022 Asian Journal of Medical Sciences



This work is licensed under a Creative Commons Attribution-NonCommercial 4.0 International License.

Address for Correspondence:

Dr. Sweta Singh, Assistant Professor, Department of Ophthalmology, AL-Falah School of Medical Science and Research Center, Faridabad - 121 004, Haryana, India. **Mobile:** +91-9968700295. **E-mail:** dr.swetasingh@outlook.com

Management initially involves optical refraction,¹ but may require lens removal in cases of unstable refractive error and significant or progressive subluxation which is uncorrectable by conventional means.

This study was done to assess and compare the advantages and disadvantages, post-operative visual outcome, and post-operative complications of Cionni ring with posterior chamber intraocular lens (PCIOL) versus pars plana lensectomy-vitrectomy (PPL/PPV) with anterior chamber intraocular lens (ACIOL) in subluxated lenses in children.

Aims and objectives

To compare “in-the-bag” IOL implantation with Cionni ring versus PPL/PPV with ACIOL implantation in subluxated lenses in children.

MATERIALS AND METHODS

A prospective comparative study was done in 20 eyes (18 children) in the age group 8–18 years, randomly allocated by chit system into two groups comprising ten eyes each. The study was conducted in the Department of Ophthalmology, Guru Nanak Eye Center and the study design was approved by the ethical committee.

- Group A: Comprised ten eyes, this underwent surgery with single eyelet Cionni Ring with “in-the-bag” PCIOL
- Group B: Comprised ten eyes which underwent PPL/PPV with ACIOL.

Children of age group 8–18 years with 90–210° subluxation (3–7 clock h) were included in the study. Children with best-corrected visual acuity (BCVA) better than 20/40, posterior segment pathology, gross anterior segment anomaly, traumatic mydriasis, glaucoma, and uveitis were excluded from the study.

A detailed history regarding the ocular and systemic complaints was obtained. Ophthalmological examination included BCVA, specular microscopy, anterior chamber depth, intraocular pressure (IOP) using non-contact tonometer, slit lamp examination (to note the degree of subluxation and presence or absence of vitreous in anterior chamber), and dilated fundus examination. OCT was done to assess the macular status wherever possible. In subluxation with heritable disease, proper systemic workup was done.

Surgical technique

Group A: All eyes were operated by the same surgeon (AR). A localized conjunctival peritomy was performed. A partial thickness scleral flap was made 1.5 mm behind the limbus in the area of maximum zonular weakness. A 3.0 mm clear corneal incision and two side ports were made.

A 26-gauge cystitome was used to initiate the capsular tear, and the capsulorhexis was performed with Utrata forceps. Multiquadrant hydrodissection was performed. Lens aspiration was done using irrigation-aspiration with low aspiration flow rate, low vacuum, and low bottle height. Anterior vitrectomy was performed in cases with vitreous prolapse in anterior chamber. 9–0 prolene suture was threaded to the fixation eyelet on the Cionni ring, after which Cionni ring was passed in the main incision and sutures were brought out beneath the scleral flap with ab externo approach, using railroading with 26-gauge needle. The Cionni ring was dialed so that the eyelet was in position of maximum subluxation. PCIOL was implanted in-the-bag. The main incision, side port, and conjunctiva were sutured with 10–0 Vicryl. Figure 1 (a) shows a well centered IOL in one of the eyes operated by this technique.

Group B: 180° conjunctival peritomy was done. Two sclerotomies were made 3 mm posterior to the limbus. A 6 mm tunneled incision was made at the superior limbus. Subluxated lens removal was done by PPL/PPV. Scleral depression was performed to ensure that no residual peripheral lens matter remained. Pupil was constricted with pilocarpine. Kelman Multiflex open loop ACIOL was implanted through the superior incision. Peripheral iridectomy was done and wound was closed with 10–0 Vicryl. Sclerotomies were sutured with 6–0 Vicryl. Figure 1 (b) shows well placed ACIOL in one of the eyes operated by above technique.

Postoperatively, all patients were given systemic antibiotic for 5 days and a short course of systemic steroids (1–2 mg/kg body weight) tapered for 4–6 weeks whenever required. All patients were prescribed topical antibiotics 4 hourly, topical steroid 4 hourly. Oral and topical antiglaucoma medications were prescribed in cases of raised IOP.

Outcome measures

Patients were followed on day 1, 1 week, 1 month, and then at 3 months for BCVA, endothelial cell count, IOP, lens centration, fundus evaluation, and any intraoperative and post-operative complications.

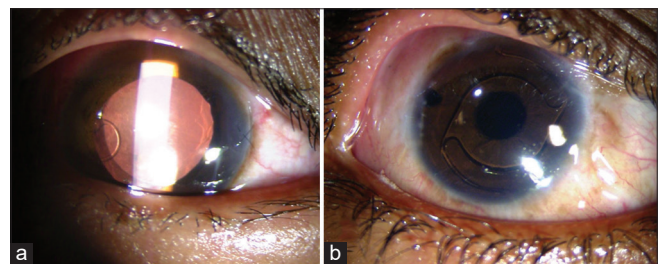


Figure 1: (a) Single eyelet Cionni ring fixated posterior chamber intraocular lens after subluxated lens removal by phacoaspiration using irrigation-aspiration cannula via limbal approach. (b) Kelman Multiflex flexible loop ACIOL implanted after subluxated lens removal by pars plana lensectomy and vitrectomy

RESULTS

The mean age of the patients in Group A and Group B was 13.10 ± 4.2 years and 12.50 ± 2.99 years, respectively. The diagnosis included trauma in eight eyes (40%), MFS in four eyes (20%), and myopia in four eyes (20%), inherited lens dislocation without any other medical conditions in one eye (5%) and three eyes (15%) had idiopathic subluxation. The mean amount of subluxation in clock hours was 5 ± 1.247 and 5.4 ± 1.174 in Groups A and B, respectively. For statistical analysis, Snellen's visual acuity was converted to log MAR value. In Group A, pre-operative BCVA ranged from 1.7782 to 0.602 with a mean of 1.1873 ± 0.526 and in Group B, BCVA ranged from 1.7782 to 0.602 with a mean of 1.249 ± 0.472 . In Group A, the pre-operative specular count ranged from 2938 to 3693.2/mm² with a mean specular count of 3377.97 ± 229.7 /mm². In Group B, the pre-operative count ranged from 3210 to 3721/mm² with a mean specular count of 3412.60 ± 145.15 /mm². The pre-operative anterior chamber depth in Group A ranged from 2.9 to 3.54 mm, with a mean of 3.32 mm. In Group B, the anterior chamber depth ranged from 3 to 3.96 mm with a mean of 3.53mm. In Group A, the axial length ranged from 22.21 mm to 27.9 mm with a mean of 24.228 ± 2.325 mm. The axial length in group B ranged from 21.46 mm to 28.86 mm with a mean axial length of 22.798 ± 2.219 mm. A normal fundus was noted preoperatively in both Groups A and B in seven eyes each. Fundus could not be visualized in five eyes due to significant cataract (three in Group A and two in Group B). Hypoplastic disk was noted in one case in Group B.

Intraoperative outcome

The surgeon faced various problems with the two procedures. In Group A, it was difficult to puncture the capsule and to make a central capsulorhexis as it was lax

and crumpled. Iris retractors were used to stabilize the capsulorhexis in few of the eyes. It was also difficult to perform irrigation and aspiration, as it increased the stress on the zonules. There was vitreous presentation in one of the eyes, for which anterior vitrectomy was done. The intraoperative time taken in Group A ranged from 50 min to 90 min with a mean value of 68 ± 16.19 min. The intraoperative time in Group B ranged from 20 min to 50 min with a mean value of 30 ± 12.9 min. There was statistically significant difference in the operating time between the two groups.

In Group B, there was lens fragment drop in the vitreous cavity in two eyes during the procedure. Lensectomy also proved to be difficult in eyes with large subluxation, requiring scleral indentation intraoperatively for adequate visualization of the subluxated lens. ACIOL implantation necessitates a large corneoscleral wound requiring more sutures and producing a higher corneal astigmatism.

Visual outcome

The difference between pre-operative and post-operative visual acuity at 3 months in both the groups was found to be statistically highly significant ($P < 0.001$ in Group A and $P = 0.001$ in Group B). However, there was no statistically significant difference in visual acuity between Group A and Group B at the end of 3 months (Tables 1 and 2).

Post-operative specular count

In Group A, endothelial cell density (ECD) decreased from pre-operative mean of 3377 ± 229 /mm² to post-operative mean of 3114 ± 220 /mm². In Group B, ECD decreased from pre-operative mean of 3412 ± 145 /mm² to post-operative mean of 3091.25 ± 448 /mm². The difference was not statistically significant between two groups at end of 3 months ($P = 0.885$) (Table 3).

Table 1: Mean pre-operative and post-operative visual acuities of both groups

Visit	Group A (Log MAR)	Group B (Log MAR)	P-value
Pre-operative	1.187±0.526	1.249±0.472	0.633
Post-operative day 1	0.906±0.764	1.046±0.895	0.562
Post-operative week 1	0.335±0.278	0.628±0.509	0.194
Post-operative 1 month	0.184±0.136	0.376±0.230	0.083
Post-operative 3 months	0.250±0.189	0.328±0.203	0.453

Table 2: Pre-operative and post-operative BCVA at 3 months

Best corrected visual acuity (log MAR)	Snellen's equivalent	Pre-operative		Post-operative at 3 months	
		Group A (%)	Group B (%)	Group A (%)	Group B (%)
0-0.18	6/6-6/9	0	0	50	40
0.30-0.48	6/12-6/18	0	0	40	40
0.6-1	6/24-6/60	60	60	10	20
>1	<6/60	40	40	0	0
Total		100	100	100	100

Post-operative complications

Table 4 shows the post-operative complications. Posterior capsular opacification (PCO) was the most common complication in Group A. Five eyes in Group A developed early Visual Axis Opacification (VAO) and one eye had visually significant VAO for which Nd: YAG laser capsulotomy was done. In Group B, two eyes had raised IOPs which were controlled on medications. All other complications were treated conservatively. No cases of retinal detachment or endophthalmitis occurred.

DISCUSSION

The implantation of the PCIOL with the help of Cionni ring is the procedure of choice for subluxated lenses. Cionni ring with PCIOL implantation has many advantages including retention of the natural capsular bag enabling placement of the PCIOL. It acts as a mechanical barrier against the movement of the vitreous. The problems associated with this standard procedure in subluxated lenses are extension of zonular dialysis, vitreous loss, aspiration of the capsular bag, decentration of the intraocular lens (IOL), prolonged intraoperative time, suture erosion, endophthalmitis, and posterior dislocation of bag and IOL.

PPL/PPV with ACIOL implantation is technically easier and less time consuming. The role of ACIOL in subluxated lenses in children is debatable. It is important to note that majority of the adverse events such as glaucoma, PBK (pseudophakic bullous keratopathy), and hyphema were associated with the older closed-loop ACIOLs. Modern open-loop and vaulted ACIOLs have been designed to prevent these complications.²⁻⁴

There are no comparative studies available for assessing the surgical outcome of Cionni ring with PCIOL versus PPL/

PPV with ACIOL in subluxated lenses in children. Both the approaches were compared in our study with respect to various intraoperative and post-operative parameters. The surgical technique of PPL/PPV with ACIOL implantation was found to be technically less demanding. The mean operating time in Group A and Group B was (68±16.19 min) and (30±12.47 min), respectively. The operating time in Group B was significantly lower than Group A (Cionni Ring with PCIOL implantation). In Group B, in two eyes, there were lens droppings in the vitreous during the procedure. Lensectomy also proved to be difficult in cases with large subluxation, requiring scleral indentation intraoperatively for tackling the extreme periphery of the subluxated lens. ACIOL implantation necessitates a large corneoscleral wound requiring more sutures and producing a resultant higher corneal astigmatism. PPL/PPV also disturbs the natural physiological barrier between the anterior and the posterior chamber.

In Group A, the Cionni ring facilitated preservation of the posterior capsule and implantation of the PCIOL. Difficulty in several steps contributed to the increase in the operating time. It was difficult to make the initial puncture and a central capsulorhexis. Iris retractors were used in two cases to temporarily support and stabilize the capsular bag. In a study by Praveen et al.,⁵ the authors aborted the implantation of capsular tension ring (CTR) in two eyes due to extension of anterior capsular tear. In the present study, we did not encounter similar problems. In our series, bimanual irrigation aspiration was performed to maintain a closed chamber using a low aspiration flow rate (12–15 ml/min), low vacuum (12–15 mm Hg), and reduced bottle height (35–50 cm). Viscoelastic was injected before removing any instrument to prevent posterior capsule from moving forward. In our series, we used Cionni modified single eyelet CTR after lens removal. Ahmed et al.,⁶ found that to minimize further zonular stress and capsular destabilization, the ideal timing for Cionni ring implantation is after lens extraction and decompression of the capsular bag. Implanting the Cionni ring before complete lens removal may trap cortex against the capsular bag, making cortex removal difficult.^{7,8}

In the present study, nine out of ten (90%) eyes in Group A and eight out of ten (80%) eyes in Group B had a final visual acuity of 6/18 or better at the end of 3 month follow-up. The visual acuity in remaining patients did not improve beyond 6/18 due to amblyopia in both Group A and B patients. It was found that the difference in visual acuities between the two groups at each visit was not statistically significant.

The average decrease in ECD in Group A was 263/mm² that is (7.78%) and in Group B was 321/mm² that is (9.4%).

Table 3: Mean pre-operative and post-operative endothelial cell density

Mean ECD	Group A	Group B
Pre-operative	3377±229/mm ²	3412±145/mm ²
Post-operative	3114±220/mm ²	3091.25±448/mm ²
Average decrease	262/mm ²	321/mm ²

Table 4: Post-operative complications

Complications	Group A	Group B	P-value
Visual axis opacification	6	0	0.011
Cystoid macular edema	0	1	1
Vitreous hemorrhage	1	1	1
Raised IOP	0	2	0.128
lens decentration	1	0	1
Vitreous Prolapse	1	0	1

IOP: Intraocular pressure

The decrease in ECD was not statistically significant at the end of 3 months ($P=0.885$). Hirashima *et al.*,⁹ took a total of 31 eyes of 16 patients with a mean age of 25 years with subluxated lens associated with MFS, to study the outcome of iris claw anterior chamber versus iris fixated foldable PCIOL. They found that there was comparable loss in ECD being 8% and 10% in iris claw ACIOL and iris sutured PCIOL, respectively.

VAO is the most common long-term complication of pediatric cataract surgery. PCO is almost inevitable when cataract surgery is performed without a posterior capsulorhexis and anterior vitrectomy in young children.¹⁰ In eyes with zonular weakness, performing a posterior continuous curvilinear capsulorhexis is not only challenging but it can also be hazardous. Therefore, the posterior capsule is left intact at the time of primary surgery. In our series, all children were above 8 years of age. Five eyes in Group A developed early VAO and one eye had visually significant VAO, for which Nd: YAG laser capsulotomy was done. In Group B, there was no VAO in any of the eyes. Konradsen *et al.*,¹¹ managed 37 eyes with ectopia lentis of non-traumatic etiology in children with a Cionni-modified CTR (33 eyes) and conventional CTR (four eyes) and IOL with good long-term results. In their series, 26 eyes needed secondary surgery for VAO. Pranab *et al.*,¹² prospectively, studied 18 eyes of 15 children with subluxation of crystalline lenses (90° up to 210°). They were managed by phacoemulsification followed by CTR and IOL implantation. In their case series, nine eyes had visually significant PCO. In all eyes with PCO, Nd: YAG laser posterior capsulotomy was done to regain optimal visual outcome.

There was mild decentration of the IOL in one eye (10%) in Group A at the end of 3 months of follow-up. However, no intervention was required as IOL remained stable and decentration was evident only on full dilatation of the pupil.

Other complications of Group A included vitreous hemorrhage which occurred in one eye, which was probably due to direct trauma while passing the needle or wicking of extraocular blood into the eye along the suture. The vitreous hemorrhage resolved spontaneously in 1 month.

In Group B, two eyes had pupillary block, 1 eye had vitreous hemorrhage, and one of the eye had cystoid macular edema (CME). The incidence of CME following flexible open-loop ACIOL implantation has been reported to range from 1.2% to 10%.¹³ The pupillary block resolved after laser iridotomy. The vitreous hemorrhage also resolved spontaneously in 1 month. In our study, three eyes in Group A and five eyes in Group B developed post-operative inflammation which was successfully managed with topical steroids.

An important concern with implantation of Cionni ring is the long-term follow-up which is required. In cases with severe or progressive zonular dehiscence, there may be late IOL decentration and pseudophacodonesis and rarely the disastrous occurrence of complete dislocation of the bag, Cionni, and the IOL complex into the vitreous. In a study by Vasavada *et al.*,¹⁴ in three eyes (8.5%), there was dislocation of the bag Cionni IOL complex after a follow-up of 28 months. A question of the stability of the 10–0 polypropylene suture has also been raised; Cionni *et al.*, have reported nearly 10% incidence of suture breakage after a mean follow-up of 18 months, leading to their recommendation that suture stronger than prolene 10–0 should be used.¹⁵ In our series, we used 9–0 prolene sutures. Over long-term even well-buried prolene suture can become visible and can cause conjunctival erosion, possible suture induced infections, and rarely endophthalmitis.

Long-term complications of the ACIOL implantation include corneal decompensation, post-operative glaucoma, and iris damage. None of the patients in our series developed any of these complications. A longer follow-up in our series will give a better idea for development of any such complications.

Limitations of the study

Long term follow up is needed to look for possible complications in the future.

CONCLUSION

In cases of large subluxation with good pre-operative specular count, the implantation of a planned open loop ACIOL is a viable surgical Option. Pars PPL/PPV with ACIOL implantation in children with subluxated lenses provides improved visual acuity during a short follow-up period. However, long-term follow-up is needed to safeguard against the possibilities of complications, which may arise in the future.

ACKNOWLEDGMENT

We thank all the individuals included in this study.

REFERENCES

1. Nelson LB and Szmyel SM. Aphakic correction in ectopia lentis. *Ann Ophthalmol.* 1985;17(7):445-447.
2. Osher R and Cionni R. The torn posterior capsule: Its intraoperative behavior, surgical management and long term consequences. *J Cataract Refract Surg.* 1990;16(4):157-162. [https://doi.org/10.1016/s0886-3350\(13\)80805-x](https://doi.org/10.1016/s0886-3350(13)80805-x)
3. Hennig A, Evans JR, Pradhan D, Johnson GJ, Pokhrel RP, Gregson RM, et al. Randomised controlled trial of anterior-

- chamber intraocular lenses. *Lancet*. 1997;349(9059):1129-1133. [https://doi.org/10.1016/s0140-6736\(96\)11043-6](https://doi.org/10.1016/s0140-6736(96)11043-6)
4. Mamalis N, Crandall AS, Pulsipher MW, Follett S and Monson MC. Intraocular lens explantation and exchange. A review of lens styles, clinical indications, clinical results, and visual outcome. *J Cataract Refract Surg*. 1991;17(6):811-818. [https://doi.org/10.1016/s0886-3350\(13\)80416-6](https://doi.org/10.1016/s0886-3350(13)80416-6)
 5. Praveen MR, Vasavada AR and Singh R. Phacoemulsification in subluxated cataract. *Indian J Ophthalmol*. 2003;51(2):147-154.
 6. Ahmed K, Cionni RJ, Kranemann C and Crandall AS. Optimal timing of capsular tension ring implantation. *J Cataract Refract Surg*. 2005;31(9):1809-1813. <https://doi.org/10.1016/j.jcrs.2005.02.048>
 7. Cionni RJ and Osher RH. Management of profound zonular dialysis or weakness with a new endocapsular ring designed for scleral fixation. *J Cataract Refract Surg*. 1998;24(10):1299-1306. [https://doi.org/10.1016/s0886-3350\(98\)80218-6](https://doi.org/10.1016/s0886-3350(98)80218-6)
 8. Hara T, Hara T and Yamada Y. "Equator ring" for maintenance of the completely circular contour of the capsular bag equator after cataract removal. *Ophthalmic Surg*. 1991;22(6):358-359.
 9. Hirashima DE, Soriano ES, Meirelles RL, Alberti GN and Nosé W. Outcomes of iris-claw anterior chamber versus iris-fixed foldable intraocular lens in subluxated lens secondary to Marfan syndrome. *Ophthalmology*. 2010;117(8):1479-1485. <https://doi.org/10.1016/j.ophtha.2009.12.043>
 10. Kugelberg M and Zetterstrom C. Pediatric cataract surgery with or without anterior vitrectomy. *J Cataract Refract Surg*. 2002;28(10):1770-1773. [https://doi.org/10.1016/s0886-3350\(02\)01332-9](https://doi.org/10.1016/s0886-3350(02)01332-9)
 11. Konradsen T, Kugelberg M and Zetterstrom C. Visual outcomes and complications in surgery for ectopia lentis in children. *J Cataract Refract Surg*. 2007;33(5):819-824. <https://doi.org/10.1016/j.jcrs.2007.01.032>
 12. Das P, Ram J, Brar GS and Dogra MR. Results of intraocular lens implantation with capsular tension ring in subluxated crystalline or cataractous lenses in children. *Indian J Ophthalmol*. 2009;57(6):431-436. <https://doi.org/10.4103/0301-4738.57149>
 13. Ellerton CR, Rattigan SM, Chapman FM, Chitkara DK and Smerdon DL. Secondary implantation of open-loop, flexible, anterior chamber intraocular lenses. *J Cataract Refract Surg*. 1996;22(7):951-954. [https://doi.org/10.1016/s0886-3350\(96\)80197-0](https://doi.org/10.1016/s0886-3350(96)80197-0)
 14. Vasavada V, Vasavada VA, Hoffman RO, Spencer TS, Kumar RV and Crandall AS. Intraoperative performance and postoperative outcomes of endocapsular ring implantation in paediatric eyes. *J Cataract Refract Surg*. 2008;34(9):1499-1508. <https://doi.org/10.1016/j.jcrs.2008.04.044>
 15. Cionni RJ, Osher RH, Marques DM, Marques FF, Snyder ME and Shapiro S. Modified capsular tension ring for patients with congenital loss of zonular support. *J Cataract Refract Surg*. 2003;29(9):1668-1673. [https://doi.org/10.1016/s0886-3350\(03\)00238-4](https://doi.org/10.1016/s0886-3350(03)00238-4)

Authors Contribution:

SS- Prepared first draft of manuscript, interpreted the result, reviewed the literature, manuscript preparation, statistical analysis, and interpretation; **AR-** Concept and design of the study, surgical expertise; **JK-** Revision of the manuscript, statistical analysis, and interpretation; **VS-** Coordination.

Work attributed to:

Guru Nanak Eye Center, New Delhi, India.

Orcid ID:

Dr. Sweta Singh - <https://orcid.org/0000-0002-8507-7722>

Anju Rastogi - <https://orcid.org/0000-0002-0937-0601>

Dr. Jaidrath Kumar - <https://orcid.org/0000-0002-8616-0317>

Dr. Vartika Srivastava - <https://orcid.org/0000-0001-8476-8049>

Source of Support: Nil, **Conflict of Interest:** None declared.