

Evaluation of outcome in arc of motion of elbow after arthrolysis in post-traumatic stiff elbow through posterior triceps reflecting anconeus pedicle approach



Sai Phanindra Malladi¹, Pamarthi Srinivas², Raju Byshetty³

¹Assistant Professor, Department of Orthopaedics, NRI Institute of Medical Sciences, Visakhapatnam, Andhra Pradesh, India, ^{2,3}Assistant Professor, Department of Orthopaedics, Maheshwara Medical College and Hospital, Telangana, India

Submission: 04-07-2022

Revision: 03-10-2022

Publication: 01-11-2022

ABSTRACT

Background: The elbow is a synovial hinge joint, with a high chance of stiffness. A stiff elbow is an elbow with a loss of extension of $>30^\circ$ and flexion of $<120^\circ$ which can result due to post-traumatic events around elbow. Surgical intervention is required if conservative treatment fails. The arthrolysis of the elbow by posterior approach has been reported less widely. **Aims and Objectives:** This study aims at reporting the arc of motion of the elbow after arthrolysis by posterior approach by TRAP approach. **Material and Methods:** This study was done on 26 patients with post-traumatic elbow stiffness through posterior triceps reflecting anconeus pedicle graft approach. The mean age of patients in our study is 30.8, ranging from 15 to 54 years. After surgery, patients were reviewed to assess arc of motion and fixed flexion deformity (FFD) improvement, MAYO and oxford score. **Results:** Our study showed increase in arc of motion from 50.7° to 90.7° , FFD decrease from 31.3° to 18.2° and MAYO score which had a pre-operative mean of 77.3, increased to 90 postoperatively with excellent result in 18 cases (69.2%) and good in eight cases (30.8%). Oxford score had an improvement from 21.8 to 40.3 showing satisfactory result in 11 cases. **Conclusion:** The approach described in our study is ideal for posterior bony blocks with maintaining intact extensor mechanism and less chance of neurovascular damage. Stability of the joint is maintained with feasibility to do ulnar nerve transposition.

Key words: Arthrolysis; Elbow stiffness; Arc of Motion; Triceps reflecting anconeus pedicle approach

INTRODUCTION

The elbow is a highly constrained synovial hinge joint, with a high propensity for stiffness and degeneration. In 1981, Morrey et al.,¹ found the functional arc of elbow motion to be 100° for both flexion–extension (30° – 130°) and pronation–supination (50° in either direction). A stiff elbow has been defined as one with a loss of extension of $<30^\circ$ and flexion of $<120^\circ$.

Loss of motion of the elbow is a common complication after elbow trauma.² Etiological factors of stiff elbow are

multifactorial which includes post-traumatic stiffness (most common), heterotopic ossification of bone, inflammatory conditions like rheumatoid arthritis, infections around elbow, massage therapy to elbow following a soft-tissue insult, osteoarthritis of elbow, multiple hemarthrosis in hemophiliacs, and arthrogryposis congenita. Among these conditions, post-traumatic stiff elbow is most common cause and these cases are planned for surgery in our study.

Dynamic splints that apply a constant prolonged force to the tissues as additional motion is achieved are a popular alternative with satisfactory results reported.

Access this article online

Website:

<http://nepjol.info/index.php/AJMS>

DOI: 10.3126/ajms.v13i11.45216

E-ISSN: 2091-0576

P-ISSN: 2467-9100

Copyright (c) 2022 Asian Journal of Medical Sciences



This work is licensed under a Creative Commons Attribution-NonCommercial 4.0 International License.

Address for Correspondence:

Dr. Pamarthi Srinivas, Quarters No 124, Staff Quarters, Maheshwara Medical College, Chitkul, Isnapur, Patancheru, Sangareddy - 502 307, Telangana, India. **Mobile:** +91-7013564391. **E-mail:** srinupsg@gmail.com

If nonsurgical treatment fails to restore a functional arc of motion, surgical arthrolysis is to be considered.³ Other treatment modalities include radial head excision, arthroplasty, arthroscopic arthrolysis, and bone block excision. In our study, we are assessing the arc of motion after doing an open arthrolysis of elbow in post-traumatic stiff elbow.

The timing of surgery has been associated with the outcome. The longer the intervention is delayed, the more contracted muscles and tendons. Articular cartilage will also be involved particularly when there is complete ankylosis of the elbow. Patients treated within 1 year after the onset of stiffness has better functional results.

Surgeon can choose between medial, lateral, and anterior approaches according to plane of contracture, previous incisions, need for nerve decompression, and location of heterotopic ossification. Posterior midline incision along with separate medial and lateral incisions will give access to both posteromedial and posterolateral part of joint and access to the ulnar nerve and anterior elbow through deep lateral and medial approaches. Avoidance of injury to nerves is of utmost importance.

Interposition arthroplasty can be considered in younger patients and patients with excess articular incongruity. A total elbow arthroplasty may be considered in older patients with very stiff or ankylosed elbows with extensive articular involvement. Preservation of the lateral collateral ligaments and the anterior oblique band of the medial collateral ligament (MCL) is very important in any approach around the elbow.

This preservation helps in proper rehabilitation and eliminates the potential for post-operative instability. In very severe and long-standing cases, we may need a partial release of the anterior oblique band of the MCL and the lateral collateral ligaments.

The most common complications of open contracture release include neuropathies, infection, heterotopic ossification, and recurrence.

The arthrolysis of the elbow by posterior approach has been reported less widely. This study aims at reporting the arc of motion and functional outcome of the elbow after arthrolysis by posterior approach.

Aims and objectives

- 1) Evaluate the functional outcome of elbow ROM after arthrolysis for post traumatic stiff elbow by Posterior (TRAP) approach
- 2) Evaluate complications if any noted during this procedure.

MATERIALS AND METHODS

We had prospectively followed up on 26 cases of post-traumatic stiff elbow treated with elbow arthrolysis through the triceps reflecting anconeus pedicle (TRAP) approach from April 2019 to September 2021, after getting Institutional Ethical Clearance (IEC) in Maheshwara medical college and hospital and NRI institute of medical sciences with a minimum follow-up of 6 months and maximum follow-up to 1 year.

Inclusion and exclusion criteria are tabulated below in Table 1.

Procedure

After proper consent for surgery in our study, we used the posterior TRAP approach. All patients were operated in lateral decubitus position with the arm supported on pillows. A standard posterior midline incision curving medially at the tip of the olecranon was used. Soft tissues were cleared. The ulnar nerve is identified and protected with sterile glove.

The distal end of the anconeus was identified and the muscle along with the tendon of the triceps and the underlying periosteum was elevated from the subcutaneous border of the ulna in a medial to lateral direction. Extreme care was taken while lifting the insertion of the triceps and the underlying periosteum at the level of its insertion to the olecranon and proximal ulna. Soft-tissue clearance was done till bare bone (Figure 1).

Intra-articular adhesions were removed. Bony blocks obstructing joint movement as in the case of malunited fractures and myositis ossificans were cleared and the distal humerus was “delivered” out.

Table 1: Inclusion and exclusion criteria

<i>Inclusion criteria</i>	<i>Exclusion criteria</i>
1. Post-traumatic stiff elbow (arc of motion<100)	1. Poor general health
2. Heterotopic ossification confirmed by pre-op radiograph	2. Immature skeletal elbow
3. Skeletally mature elbow	3. Stiffness due to burns
4. Radiographic evidence of union of the earlier fracture site as assessed with X-ray and CT elbow in case of complex block which can't be assessed with X-ray.	4. Acute sudeck's dystrophy
5. Clinically stable joint	5. Inflammatory joint changes
6. Patient with good general health with a stiff elbow	6. Extensive destruction of all articular surfaces
	7. Joint stiffness is minimal and functionally compensated
	8. Stiff elbow accompanied by articular fractures
	9. Associated CNS injury
	10. Other causes of Stiff elbow are excluded

CT: Computed tomography, CNS: Central nervous system

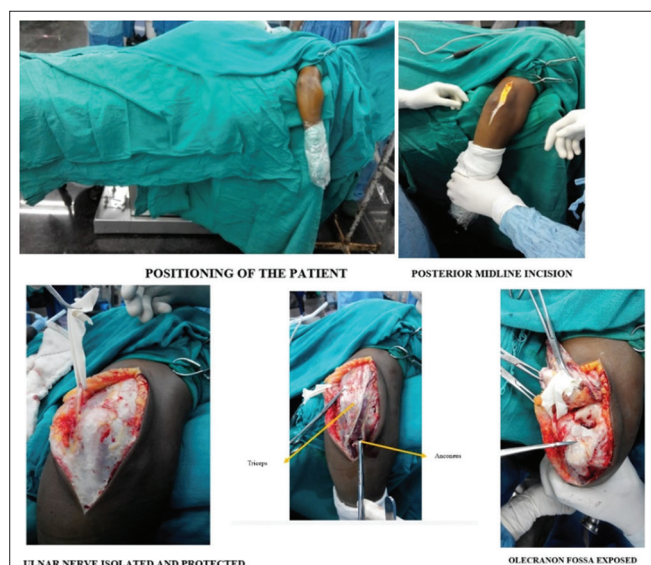


Figure 1: Steps of surgery to expose the elbow joint through posterior TRAP approach

Anterior bony blocks can be accessed by sublaxating the joint by hyperflexion. This can be achieved by incising the posterior oblique band of the MCL. The incised oblique band is sutured back after the removal of bony blocks anteriorly.

This allowed clearance on the anterior surface of the distal humerus as well without causing any damage to the anterior structures and without affecting the stability of the joint much.

At this point, the supination-pronation range was tested, and if there was any restriction, the release of the proximal radio-ulnar joint was done. In cases with a deformed radial head, the radial head was excised and left without prosthesis in two cases, excising the annular ligament, and suturing it back.

In case of very bad elbow fractures or in a case where there is ankylosis, the lower end of the humerus was refashioned into a notch and the proximal ulna was refashioned into a hook to provide an axis for flexion/extension to take place. This was done in one case.

After complete clearance of the joint, the triceps tendon with the periosteum was repositioned and transfixed to the bone with the help of drill holes sutured using ethibond (Figure 2).

Closure was done after checking the stability and range of motion and drain is kept. Crepe bandage dressing is done and the elbow is rested in an arm sling pouch. The patient was given NSAID's and enzymatic agents to decrease swelling for 5 days. Gentle wrist and finger mobilization

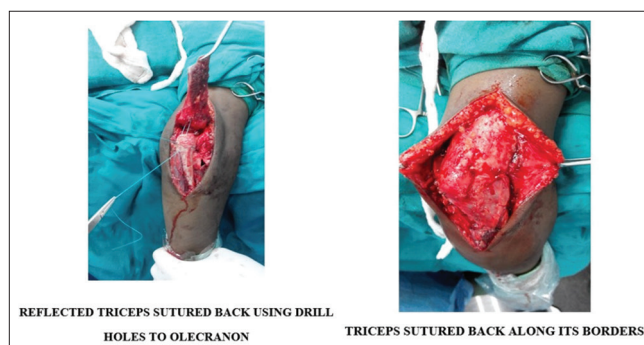


Figure 2: Suturing back of triceps with ethibond by making drill holes

exercises are allowed for the first 2 days. The patient is sent for physiotherapy for gentle mobilization exercises of the elbow. The patient is started on Indomethacin 25 mg 3 times a day from the second post-operative day till 4 weeks post-operative. Continuous passive mobilization (CPM) exercises to the elbow were started from the 5th post-operative day including active ROM exercises of flexion and extension, rotational movements. Gradual graded increase (5°/day) in CPM in both flexion and extension is allowed further from suture removal.

RESULTS

All 26 patients in the present study returned for clinical examination subsequently. Patients were reviewed after 3 weeks, 6 weeks, 12 weeks, and 24 weeks postoperatively.

The mean age of patients in our study is 30.8, ranging from 15 to 54 years. Majority of the patients are in the middle age group with high functional demands, among which females constitute 57.7% (15 cases) of our study, whereas male patients constitute 42.3% (11 cases).

In majority of the patients, the right side is involved most 15 cases (57.7%) which are the dominant hand. Trauma occurred to the elbow due to free fall (FF) in 65.4% of cases (17), while in 34.6% of cases (9) trauma occurred due to road traffic accidents.

In 73.1% (19) of cases, the stiffness is due to heterotopic mass, whereas, in 26.9% (7) of cases, it is due to malunion of the fracture caused to trauma

Most of the cases (15) were operated on within 6 months to 15 months after the development of stiffness which showed better improvement. In eight cases, stiffness was present for more than 15 months, and in three cases, it was seen for more than 20 months which showed less improvement in movement due to deformation of radial head or distal humerus.

Eighteen patients took native cast treatment before undergoing our procedure, and eight cases underwent surgery before our procedure. In 18 cases, the duration of immobilization was <4 weeks, whereas, in eight cases, the duration of immobilization was >4 weeks.

Among eight cases which underwent surgery, seven were distal humerus fractures which were treated with anatomical locking plates and one case had a posterior dislocation which was treated with K-wires after reduction.

In our study among 26 patients, mean pre-operative flexion in the elbow was 82.1°. It significantly increased in all the cases to a mean of 108.8° intraoperatively, 112.2° at 3 weeks of follow-up, and after that, it reduced to 111.7°, 106.7°, 106.7° at 6-week, 12 weeks, and 24 weeks follow-up, respectively.

The mean pre-operative fixed flexion deformity (FFD) at the elbow preoperatively was 31.3°. It significantly decreased in all the cases to a mean of 10.76° intraoperatively, 19.61°, 19.65°, 18.2°, 18.2° at 3-week, 6-week, 12-week, and 24-week follow-up, respectively.

The mean arc of motion at the elbow preoperatively was 50.7°. It significantly increased in all the cases to a mean of 97.7° intraoperatively and then gradually decreased to 92.2°, 91.1°, 89.3°, 89.3° at 3-week, 6-week, 12-week, and 24-week follow-up, respectively (Figure 3).

In our study, the mean pre-operative supination was 67° and pronation was 50°. It increased to 69° and 53°, respectively, postoperatively. There is no significant improvement in pronation or supination movements through this approach as proximal radio ulnar joint is not exposed in majority of cases to prevent instability.

In our study, the pre-operative mean MAYO score was 77.3. It significantly increased to 90 (mean) postoperatively

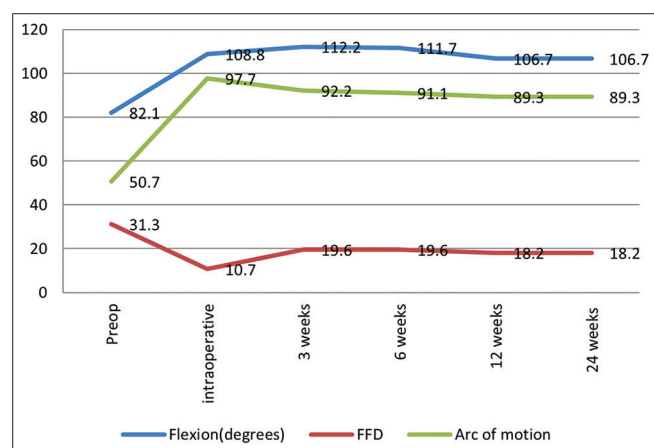


Figure 3: Graphical representation of results in flexion, fixed flexion deformity, and arc of motion

with excellent results in 18 cases (69.2%) and good in eight cases (30.8%).

In our study, the pre-operative mean oxford score was 21.8. It significantly increased to 40.3 (mean) postoperatively with a satisfactory result in 11 cases (42.3) and mild deformity in 15 cases (57.7%).

In six cases (23.1%), patients presented with pain in the elbow till the last follow-up which did not affect the function of the elbow joint. One case developed superficial skin infection which was effectively treated with broad-spectrum antibiotics. Two cases developed neuropraxia due to tourniquet which recovered later with splints and medications.

We used the student paired t-test to check for significance for variables (a) FFD, (b) flexion of elbow, (c) arc of motion, (d) MAYO score, and (e) oxford score (Table 2).

DISCUSSION

Ours is a prospective study comprising 26 cases who presented to us with post-traumatic elbow stiffness which is comparable to studies done by Chantelot et al.,⁴ who did a retrospective study of open elbow arthrolysis from 1984 to 1997 in 26 patients, Sharma and Rymaszewski² who did a retrospective study of 25 patients by open arthrolysis of the elbow for post-traumatic stiffness, Kulkarni et al.,⁵ who did a retrospective study in 26 patients, Park et al.,⁶ who did a study on surgical treatment of post-traumatic stiffness of the elbow in 27 patients with post-traumatic stiffness, and Swaroop et al.,⁷ study of assessment of results of open arthrolysis in post-traumatic stiff elbow in 25 cases of elbow stiffness due to various types of injuries.

The mean age of all the patients in our study was 30.8 (18–51 years.) This is comparable to the studies done by Ayadi et al.,⁸ study between 1990 and 2005 in 30 adult patients with a mean age of 30.8 years, Kulkarni et al.,⁵ retrospective study in 26 patients (15 males and 11 females) with a mean age of 30 years (12–60), and Parihar et al.,⁹ who did a retrospective study of 6 patients treated with elbow arthrolysis by TRAP approach in 2011 with a mean age of 30 years (15–56).

The average pre-operative flexion at the elbow in our study is 82.1°. This has increased to average post-operative flexion of 106.7°. There is a gain of 24.6° in the flexion which is comparable to Cikes et al.,¹⁰ which reported a gain of 14° and Swaroop et al.,⁷ who reported a gain of 30.2°.

The mean FFD in our study had improved from 31.3 to 18.2°. There is a gain of 13.1° in the FFD of the elbow. This is comparable to a study done by Kulkarni et al.,⁵ who

Table 2: Statistical analysis of various variables in our study showing significance

Variable	FFD	Flexion of elbow	Arc of motion	MAYO	Oxford
t-test value	5.425	-5.812	-8.832	-5.03	-14.7
P-value	0.0012	0.00012	0.006	0	0.0008
Result	Significant	Significant	Significant	Significant	Significant

FFD: Fixed flexion deformity

Table 3 : Tabulation of comparison between previous studies and our study done regarding arthrolysis of elbow

Variable	Our study	Kulkarni et al.	Swaroop et al.	Parihar et al.	Ayadi et al.	Cikes et al.	Breborowicz et al.
Age	30.8	30	20.6	30	30.8	-	-
Arc of motion improvement	38.6	102.4	58.4	42	51	40	36
Flexion improvement	24.6	55	30.2	26	-	14	-
FFD improvement	13.1	16.8	-	15.2	-	16	-
MAYO improvement	12.7	44	29.4	13.2	-	-	-

FFD: Fixed flexion deformity

reported a mean FFD improvement of 16.8° and Cikes et al., who reported 16° improvement.

The mean pre-operative arc of motion (50.7°) significantly increased by 38.6° to a post-operative value of 89.3°. This improvement in the arc of motion of the elbow can be compared to studies done by Heirweg and De Smet,¹¹ who reported improvement by 40°, Degreef and De Smet¹² who did a retrospective study in 12 patients with arthroscopic arthrolysis, reported a 38° gain in the range of motion, Higgs et al.,¹³ and his colleagues, reporting range of movement (ROM) improvement by 40° (from 69° to 109°), Breborowicz et al.,¹⁴ showed an average arc of motion had increased significantly at the follow-up 36°, and Cikes et al.,¹⁰ who reported a mean total increase in range of motion of 40° (13–112°) in their study.

The mean post-operative MAYO score in our study was 90. This is comparable to studies done by Hart et al.,¹⁵ who did a retrospective study in 2011. The average MEPS score increased from 45.0 points (range, 30–65 points) to 87.9 points (75–100 points).

In 2 (7.7%) patients, radial head excision was done, where there is a restriction in the supination at the elbow. This resulted in free rotations at the elbow without causing instability.

In our study, 18 (69.2%) patients showed excellent results and in eight patients (30.8%) good results postoperatively are seen as per the MAYO score.

In our study, 11 patients showed satisfactory joint and 15 cases showed mild-to-moderate joint postoperatively as per the oxford scoring system. Comparison between different studies with our study are tabulated below (Table 3).

The reason for getting different results in different patients is patient-related. Compliant patients who had undergone meticulous physiotherapy had better results compared to the other patients. Associated bony procedures like corrective osteotomies are done as a second stage procedure in selected patients for attaining a full range of motion.

Limitations of the study

The limitation of our study is that we did not include infected elbow stiffness and we had not compared with results of arthroscopic elbow arthrolysis. We have not compared any of our groups due to a small sample size and a lot of variables; we have only analyzed the results of individual groups and their end result.

CONCLUSION

The risk of neurovascular damage is minimal in this approach with no affection to extensor mechanism resulting in no loss of stability. There is a provision to do anterior transposition of ulnar nerve in cases of ulnar nerve entrapment.

This approach is ideal for patients with posterior bony blocks in the olecranon fossa which is preventing full extension at the elbow which will improve the movements without affecting stability. Although there is no significant improvement in pronation and supination as per our study as we did not encounter many cases involving proximal radioulnar joint, this may be beneficial in these cases also.

The aim of treatment should not be a full range of motion with resulting instability but rather a helpful functional range of motion of 100°, with acceptable degree of

stability which is better in this study. This study shows posterior TRAP approach for elbow arthrolysis improves functional arc of motion, facilitates early rehabilitation, and decreases flexion contracture without compromising on stability.

ACKNOWLEDGMENT

The authors would like thanks to all the patients who had participated in the study and our institutions.

REFERENCES

- Morrey BF, Askew LJ and Chao EY. A biomechanical study of normal functional elbow motion. *J Bone Joint Surg Am.* 1981;63(6):872-877.
- Sharma S and Rymaszewski LA. Open arthrolysis for post-traumatic stiffness of the elbow: Results are durable over the medium term. *J Bone Joint Surg Br.* 2007;89(6):778-81. <https://doi.org/10.1302/0301-620X.89B6.18772>
- Liu S, Fan CY, Ruan HJ, Li FF and Tian J. Combination of arthrolysis by lateral and medial approaches and hinged external fixation in the treatment of stiff elbow. *J Trauma.* 2011;70(2):373-376. <https://doi.org/10.1097/TA.0b013e3181e4f5e3>
- Chantelot C, Fontaine C, Migaud H, Remy F, Chapnikoff D and Duquenois AS. Retrospective study of 23 arthrolyses of the elbow for post-traumatic stiffness: Result predicting factors. *Rev Chir Orthop Réparatrice Appar Mot.* 1999;85(8):823-827.
- Kulkarni GS, Kulkarni VS, Shyam AK, Kulkarni RM, Kulkarni MG and Nayak P Management of severe extra-articular contracture of the elbow by open arthrolysis and a monolateral hinged external fixator. *J Bone Joint Surg Br.* 2010;92(1):92-97. <https://doi.org/10.1302/0301-620X.92B1.22241>
- Park MJ, Kim HG and Lee JY. Surgical treatment of post-traumatic stiffness of the elbow. *J Bone Joint Surg Br.* 2004;86(8):1158-1162. <https://doi.org/10.1302/0301-620X.86B8.14962>
- Swaroop A, Avasthi S, Yadav M, Kumar S, Bharti A and Sengar G. Assessment Of results of open arthrolysis in post-traumatic stiff elbows. *Internet J Orthop Surg.* 2008;11(2):6714.
- Ayadi D, Etienne P, Burny F and Schuind F. Results of open arthrolysis for elbow stiffness. A series of 22 cases. *Acta Orthop Belg.* 2011;77(4):453-457.
- Parihar M, Veliath D, Mechoor K and Ahuja D. Preliminary results of arthrolysis of the elbow utilizing the TRAP approach. *J Maharashtra Orthop Assoc.* 2011;6(1):115-19.
- Cikes A, Jolles BM and Farron A. Open elbow arthrolysis for posttraumatic elbow stiffness. *J Orthop Trauma.* 2006;20(6):405-9. <https://doi.org/10.1097/00005131-200607000-00007>.
- Heirweg S and De Smet L. Operative treatment of elbow stiffness: Evaluation and outcome. *Acta Orthop Belg.* 2003;69(1):18-22.
- Degreef I and De Smet L. Elbow arthrolysis for traumatic arthrofibrosis a shift towards minimally invasive surgery. *Acta Orthop Belg.* 2011;77(6):758-764.
- Higgs ZC, Danks BA, Sibinski M and Rymaszewski LA. Outcomes of open arthrolysis of the elbow without post-operative passive stretching. *J Bone Joint Surg Br.* 2012;94(3):348-352. <https://doi.org/10.1302/0301-620X.94B3.27278>
- Breborowicz M, Lubiatowski P, Dlugosz J, Ogrodowicz P, Wojtaszek M, Lisiewicz E, et al. The outcome of open elbow arthrolysis: Comparison of four different approaches based on one hundred cases. *Int Orthop.* 2014;38(3):561-567. <https://doi.org/10.1007/s00264-013-2172-2>
- Hart R, Janeček M, Kozák T and Okál F. Posterior extensile approach to release a post-traumatic stiffness of the elbow. *Acta Chir Orthop Traumatol Cech.* 2011;78(2):114-119.

Authors' Contributions:

SP- Conceptualization, methodology, formal analysis, writing – original draft, writing – reviewing and editing; **SM**- Data curation, writing – reviewing and editing; **RB**- Investigation, formal analysis.

Work attributed to:

To all the patients who had participated in the study and our institutions.

Orcid ID:

Dr. Sai Phanindra Malladi - <https://orcid.org/0000-0003-3210-8545>

Dr. Pamarthi Srinivas - <https://orcid.org/0000-0002-4675-5850>

Dr. Raju Byshetty - <https://orcid.org/0000-0002-1446-9067>

Source of Support: Nil, **Conflicts of Interest:** None declared.