

Histological changes of lower lip from its cutaneous to mucosa region in males



Swati Saxena¹, Arvind Kumar Pankaj², Kanchan Bisht³, Anita Rani⁴, Jyoti Chopra⁵, Sachin Panwar⁶, Archana Rani⁷

^{1,3}Post Graduate Scholar, ²Professor Junior Grade, ^{4,5,7}Professor, Department of Anatomy, ⁶Post Graduate Scholar, Department of Pharmacology, King George's Medical University, Lucknow, Uttar Pradesh, India

Submission: 13-04-2022

Revision: 27-09-2022

Publication: 01-11-2022

ABSTRACT

Background: The morphology of the epithelium of oral lips comprised of keratinized external epithelium (anteriorly) and non-keratinized or sometimes parakeratinized mucous membrane epithelium (posteriorly). **Aims and Objectives:** Knowledge of morphometry of lip lining helps in deciding the best site for choosing graft for its better uptake during several dermal grafting procedures following trauma or tumor excision following craniofacial cancers or cosmetic procedures. It also proves useful in dermatopharmacokinetics, in which we monitor the effect of drugs acting on connective tissue by trans labial route and lip augmentation surgeries (esthetic surgery), where care is to be given for dermal fillers not to be injected in muscle core of lip. **Materials and Methods:** Ten human male cadavers were procured in the Department of Anatomy, King George Medical University, Lucknow, Uttar Pradesh. The rectangle-shaped skin specimen through lower lip which included skin, mucocutaneous junction, and mucosa was stained with hematoxylin and eosin stain. Total of 30 slides were prepared. Thus, readings were obtained for three regions, respectively, with the help of CatCam E-series HD cameras which were installed in light microscope. The following conclusions were drawn for various parameters. **Results:** Thickness of skin (epidermis + dermis) of lip ranged from 880 μm to 1171 μm among males. Epidermal thickness increases on moving from cutaneous region to mucosa region of lip. Lowest contribution of stratum corneum in thickness of epidermis was observed in vermilion region, while highest contribution was observed in skin region. It was found to be absent in mucosa region of lip. Rete pegs at dermo epidermal junction was found to be maximum in vermilion region and minimum in skin region. Its depth increased as we move from skin to mucosa region of lip. Pattern of rete pegs also showed a characteristic feature in every region of lip. In cutaneous part of lip, rete pegs were shorter and blunt. In vermilion region, they were narrow, long, and slender, while they were longest with blunt end in mucosa region. Depth of dermis was found to be maximum in skin region while minimum in vermilion region. It ranged between 707 μm and 1100 μm . **Conclusion:** Care should be taken while using dermal fillers in lip augmentation surgeries, especially in vermilion region due to its close proximity to musculature in core of lip.

Key words: Dermoepidermal junction; Mucocutaneous junction; Mucosa; Rete pegs; Vermillion

INTRODUCTION

The lips are important for verbal and non-verbal communication, mastication, and maintaining an oral seal and are seen as an important factor in facial and sexual attractiveness. A mucocutaneous junction (MCJ) is defined as a transition zone, where the oral and skin epithelial

surfaces meet, for example, the lip contains the vermilion, which is a transitional zone between the stratified squamous epithelia of the skin and oral mucosa.¹ The skin of the lip ends at the vermilion border which does not contain hair or sweat glands, although in approximately 50% of persons after adolescence sebaceous glands may be found. Its epithelium is characterized by thin and non-keratinized

Access this article online

Website:

<http://nepjol.info/index.php/AJMS>

DOI: 10.3126/ajms.v13i11.44371

E-ISSN: 2091-0576

P-ISSN: 2467-9100

Copyright (c) 2022 Asian Journal of Medical Sciences



This work is licensed under a Creative Commons Attribution-NonCommercial 4.0 International License.

Address for Correspondence:

Arvind Kumar Pankaj, Professor Junior Grade, Department of Anatomy, King George's Medical University, Lucknow, Uttar Pradesh, India.
Mobile: +91-8004872858/+91-9335813287. **E-mail:** drarvindpankajcsmmu@yahoo.com

tissue.² It is often the site of an arterial anastomosis, a watershed area of venous and lymphatic drainage, and sensory (but not motor) nerve overlap. This boundary is credited as an erogenous zone, where nerve endings rise closer to the surface.³ The lower lip (*Labium inferioris*) extends from the superior free vermilion edge superiorly, to the commissures laterally, and to the mandible inferiorly.⁴ Cutaneo-vermillion junction line presents between skin and vermilion called as “white skin roll” by Millard.⁵ According to Ham, red free margin of lip is covered with a modified skin which represents a transition from skin to mucous membrane.⁶ The junctional line between vermilion and mucosa also called as Muco vermilion border parallel the “white skin roll” described as “red line”.⁷ Knowledge of anatomical and histological descriptions of lip provides a reference data which are necessary to surgeons and orthodontists treating dentofacial deformities. In contemporary western society, not only are the number of aged persons increasing but also clinical treatments (surgical, medical, and dental) and forensic investigations are currently being requested by people with a wider age range than before, thus needing new reference data that should be collected on each ethnic group. In today’s world with the evolution of microsurgical technique, several dermal grafting procedures are done at lip to restore tissue loss following trauma or tumor excision following craniofacial cancers or cosmetic procedures.⁸ Hence, as plastic surgeons understanding thorough knowledge of quantitative and qualitative aspects of lip skin parameters allows for improved reconstructive outcomes while matching donor and recipient tissues for its proper uptake. This study also proves useful in dermatopharmacokinetics, in which we monitor the effect of drugs acting on connective tissue by translabial route and investigation of various metabolic and endocrine diseases of lip.⁹ Stratum corneum (SC) is the principal barrier to drug absorption. Knowledge of its thickness is required to normalize drug penetration profiles during dermatopharmacokinetic studies. Data of drug passage through this layer can be related to bioavailability in target tissue.¹⁰ Measurement of skin thickness, SC, and dermal thickness can also prove useful in esthetic surgery (lip augmentation surgery) as it is suggested that dermal fillers used in these surgeries should not be injected so deep because if it enters the muscle core of lip, it can cause granuloma or necrosis due to being highly viscous in nature.¹¹ Literature survey, in the present study, was carried out to formulate a basic background of regional differences which can set a standard to compare pathological and chronologically changes. Dimond et al., had done histological analysis of lips using hematoxyline, periodic acid schiff, and acetylcholine esterase stains on scanning electron microscope. The study included four males’ subjects (aged 20, 22, 25, and 65 years) and one

female subjects (aged 30 years). The study found the dermis of vermilion border to be 0.5 mm thick due to its close proximity with musculature of lip. The study found that epithelium of labial mucosa measured 0.7 mm thick and its lamina propria (LP) was found similar in thickness to dermis of cutaneous part of lip.¹²

Aims and objectives

This study was morphometry of lip lining help in deciding the best site for choosing graft.

MATERIALS AND METHODS

The present observational study was carried out in the Department of Anatomy in collaboration with Department of Forensic Medicine and Toxicology, King George’s Medical University, Uttar Pradesh, Lucknow from the period of September 2018 to August 2019. Ethical clearance was obtained from the Institutional Ethics Committee, King George’s Medical University, Lucknow through (Ref. code: 93rd ECM II B -Thesis/P7).

For the present study, ten human male cadavers were procured. Out of ten samples of male lip, six samples were taken from fresh male donated body received in the department of Anatomy 4–5 h after death, next four samples were collected from forensic medicine 5–6 h after death. Age of male cadavers ranged between 5 and 75 years (mean age 45.5 years). The rectangle-shaped skin specimen measuring 1 cm long was taken through right commissure of lip which included skin, MCJ, and mucosa. Thus, readings from three fields per slide were obtained for three regions, respectively (skin, MCJ or vermilion, and mucosa region).

The cutaneous area presents with abrasions, breech and infections such as boils, crusting, blackening of skin, and hemorrhaged sites which were not taken for study. Care was taken for the specimen, not to have any kind of image artifacts from movement or orthodontic material.

For each lip specimen, three slides were prepared. Slides were stained with hematoxylin and eosin stain. Each of the slide contained horizontal sections of tissue covering the total skin thickness including skin, MCJ or vermilion, and mucosa region of lip. Hence, total of 30 slides were prepared.

Parameters such as epithelium thickness, depth, number and pattern of rete pegs at dermoepidermal junction, and thickness of dermis/LP were taken in $\times 10$ magnification except thickness of SC which was observed in $\times 40$ magnification. Each parameter was determined at two

different locations in the same region per slide and then averaged to one data set to avoid the chance of error.

The above-mentioned parameters were measured with the help of CatCam E-series HD cameras which were installed in light microscope after removing eyepiece as relay lens is built into the camera itself. Catyimage software was installed in my personal laptop and scales were calibrated at $\times 4$, $\times 10$, $\times 40$, $\times 100$. Camera was connected to USB 2.0 port on my laptop. U S B 2.0 high quality images were captured. Field of every zone, that is, skin, MCJ, and mucosa for every slide was read carefully, and various parameters (thickness) were measured using scale.

Value of each parameter in micrometer was entered into word excel sheet. For each parameter, three values were taken from three slides stained with hematoxylin and eosin as stated above and the mean value was calculated to reduce the chance of error. The mean value of each parameter was entered in tabulated form. The 21st version of SPSS software was used to analyze statistical changes.

The microphotography was done with the help of device incorporated within software. The device was installed in a laptop and connected with microscope and the photograph was clicked which was focused on the screen.

RESULTS

Among male subjects, thickness of epidermis increases from skin to mucosa region of lip. Its mean value ranged from 71.63 μm to 173.14 μm . On the other hand, thickness of SC decreases from skin to vermilion region, while found to be absent in mucosa region. Mean value ranged between 10.73 μm and 11.75 μm . Thickness of dermis decreases from skin to mucosa region. Mean value ranged from 707.10 μm to 1100.10 μm . Total thickness of skin is calculated by adding epidermis and dermis. Number of rete pegs per field was found to be maximum in vermilion region; however, its depth was

found to be maximum in mucosa region. Total dermis of lower lip and total skin thickness was found to be comparable at skin, vermilion, and mucosa region. Thickness of epidermis was found to be significantly higher in mucosa region as compared to skin and vermilion region. Number of rete pegs/field was found to be significantly higher in vermilion region as compared to skin and mucosa region.

DISCUSSION

Depth of epithelium of lower lip, while moving from skin to mucosa, was found to be thickest at mucosa (Figure 1) and exhibited statistically significant difference at all regions (skin, vermilion and mucosa) (Table 1 and Figures 1-3). In the light microscopic study on 10 human lips in Argentina conducted by Lanfranchi et al., they found mean thickness of epithelium at cutaneous part of lip as 70 μm which is found to be in consensus with findings of lower lip in our present study (Table 1). However, comparison cannot be justified as sex, age, and site of lip are not mentioned in the article.¹³ Jacobi et al., in a histological study of lip epithelium of German subjects described its depth to be 74–148 μm . They did not mention the gender, age, or even site of lip.¹⁴ Despite this, our observations were coinciding with the values at skin and vermilion region of lower lip (Table 1). Although they did not mention the epithelial thickness of mucosa of lip, our values were more than the range of depth they mentioned (Table 1), suggesting that at mucosa the epithelial lining is thickest. Satheesh et al., reported in their review article, mean epithelial thickness of skin, vermilion, and oral mucosa as 46 μm , 97 μm , and 218 μm , respectively.⁴

Thickness of SC

Likewise, epidermis, SC also exhibited regional variations at lower lip. Highest depth of SC was observed in skin region (Table 1). It was found to be absent in the mucosa region of lip (Figure 1). Jacobie et al., in their light microscopic study observed the thickness of SC of lip in eight human

Table 1: Region wise comparison of different parameters of lower lip among male subjects

S. No.	Parameters (μm)	Skin region			Vermillion region			Mucosa region			ANOVA	
		n	Mean	SD	N	Mean	SD	n	Mean	SD	F	P
1.	Thickness of epidermis	10	71.63	37.33	10	119.35	51.65	10	173.14	60.13	10.079	0.001
2.	Thickness of Stratum corneum	10	11.75	5.69	10	10.73	4.30				0.205	0.656
3.	Edp: Sc ratio	10	6.86	3.47	10	12.51	6.14				6.418	0.021
4.	No. of Rete pegs/field	10	3.50	0.71	10	7.50	1.08	10	3.80	0.79	65.053	<0.001
5.	Depth of Rete pegs	10	97.70	55.71	10	175.80	60.86	10	230.60	85.05	9.531	0.001
6.	Thickness of dermis	10	1100.1	430.46	10	882.40	596.01	10	707.10	212.03	1.986	0.157
7.	Total skin thickness	10	1171.7	424.2	10	1001.8	616.5	10	880.2	210.8	1.064	0.359

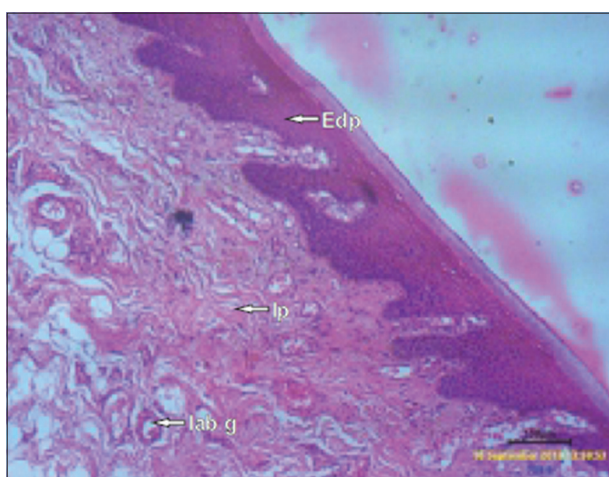
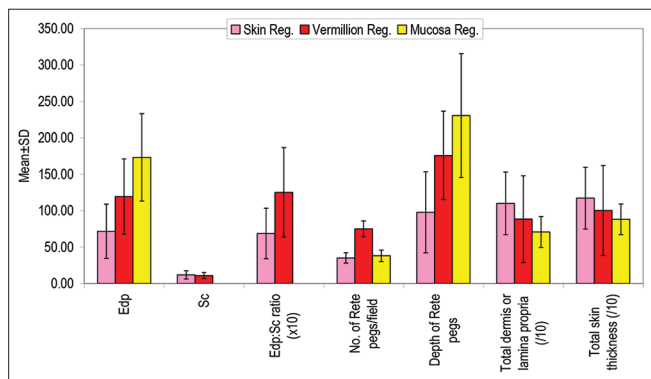


Figure 1: Microphotograph of cross section through the mucosa of lower lip at x4 showing epidermis and lamina propria

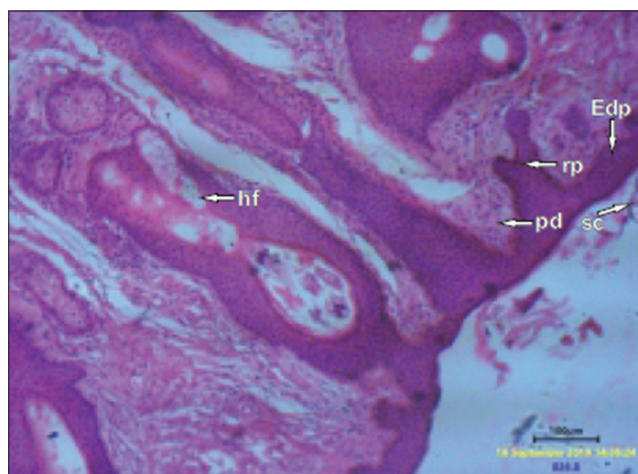


Figure 2: Microphotograph of cross section through the skin of lower lip at x4, showing epidermis, stratum corneum, papillary dermis, reticular dermis, muscularis mucosa, and hair follicle

subjects native of Germany, as 13–28 μm thick.¹⁴ In our study, values of SC thickness were little less than this range (Table 1). Although, it does not exhibit statistically significant difference at all regions.

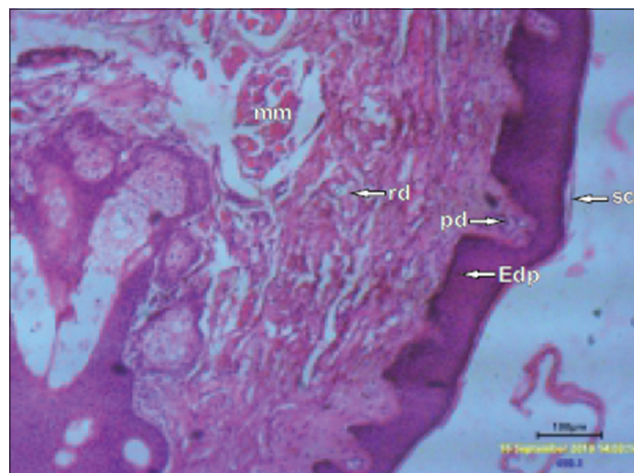


Figure 3: Microphotograph of cross section through the vermilion of lower lip at x4 showing epidermis, stratum corneum, papillary dermis, reticular dermis, and muscularis mucosa

Edp: SC ratio also exhibited regional differences. Highest contribution of SC in epidermis was seen in skin region, while lowest contribution of SC in vermilion region (Table 1 and Figure 3). As SC acts as a protection against frictional forces, which is assumed to be thicker at places, where such forces are relatively more. This hypothesis was proved right in our study. because cutaneous part of the lip among males is an area of moustache and is repeatedly shaved hence subjected to greater frictional force. Therefore, stratum corneum found to be more in this region among males as compared to vermilion region

Rete pegs: Number and depth

Number of rete pegs per field showed a remarkable regional difference. They were found maximum in vermilion region while minimum in skin region of lower lip (Figures 1-3). Depth of rete pegs was found maximum in mucosa region while minimum in skin region of lip (Table 1). Number and depth of rete pegs ensure stronger adherence between dermis and epidermis of lip. Furthermore, greater number of rete pegs ensures increase in number of basal germinative cells and greater surface area for superficial dermal capillary plexus for exchange of nutrients. Jacobie et al., observed the thickness of rete ridges of lip in eight human native of Germany using light microscope, approximated 150–300 μm thick¹⁴ which were found to be in consensus with the values in vermilion region and mucosa region of lower lip (Table 1); however, values at skin region were relatively in lower range. Comparison cannot be justified as the site of lip and sex of subjects are not mentioned in the article.

Dermis

Total dermis was found to be more in skin region of lower lip (Table 1). In the microscopic study of Dimond et al., on four male subjects (aged 20, 22, 25, and 65 years) and one

female subject (aged 30 years) found dermis of vermillion border to be 0.5 mm thick and LP of mucosa was found to be similar in thickness to dermis of its cutaneous part.¹² Findings of above study do not find to be in consensus with our findings (Table 1). We found insignificant differences in its depth. Explanations are not plausible for above discrepancies. Although, age, gender, and ethnic variations may play some role.

It is very clear from the ongoing discussion that factors such as method, criteria of measurement of depth of layer, ethnicity, age, gender, site, and region play important role in morphometrical analysis of lip. These variables have to be considered before any surgical or dermatological procedures are to be performed.

Limitations of the study

There were certain lacunae present in the study. Samples taken for the study has a wide range of age and also study sample was small enough to come to conclusions.

CONCLUSION

The present observational study was undertaken to assess the region-specific differences in lip histology on approaching MCJ at lower lip in males. The measurement of epidermis and dermis was considered for evaluating skin thickness. The following conclusions were drawn for various parameters.

Thickness of skin (epidermis+dermis) of lip ranged from 880 μm to 1171 μm among males. Epidermal thickness increases on moving from cutaneous region to mucosa region of lip. The lowest contribution of SC in thickness of epidermis was observed in vermillion region, while highest contribution was observed in skin region, thereby increasing translucency of vermillion region which helps in imparting red coloration of underlying vessels. It is absent in mucosa region of lip; therefore, it can be considered as best site for giving drugs through trans labial route as the SC is the principal barrier in percutaneous absorption.

Number of rete pegs at dermo epidermal junction was found to be maximum in vermillion region and minimum in skin region per field. Its depth increases as we move from skin to mucosa region of lip. Pattern of rete pegs also shows a characteristic feature in every region of lip. In cutaneous part of lip, rete pegs were shorter and blunt. In vermillion region, they were narrow, long, and slender, while they were longest with blunt end in mucosa region.

Depth of dermis was found to be maximum in skin region while minimum in mucosa region. It ranged between

707 μm and 1100 μm . Care should be taken while using dermal fillers in lip augmentation surgeries, especially in vermillion region due to its close proximity to musculature in core of lip.

This study tried to create a base line comparison to establish the presence of regional variation in lip morphometry, which will help in deciding the best site for choosing graft for its better uptake. *In vivo* measurements should be performed to assess the depth of dermis and epidermis or corresponding areas of mucosa for proper match of donor and recipient tissue.

ACKNOWLEDGMENT

Foremost acknowledgement is the gratefulness to god for generosity in getting my research done. I am grateful to Dr Sachin Panwar, Dr Navneet Chauhan, Dr Anita Rani, Dr Jyoti Chopra and Dr Arvind Kumar Pankaj and for their expertise and guidance in improving my research work.

REFERENCES

1. Bayar GR, Kuo S, Marcelo CL and Feinberg SE. *In vitro* development of a mucocutaneous junction for lip reconstruction. *J Oral Maxillofac Surg.* 2016;74(11):2317-2326. <https://doi.org/10.1016/j.joms.2016.04.002>
2. Kobayashi H and Tagami H. Functional properties of the surface of the vermillion border of the lips are distinct from those of the facial skin. *Br J Dermatol.* 2004;150(3):563-567. <https://doi.org/10.1046/j.1365-2133.2003.05741.x>
3. Winkelmann RK. The erogenous zones, their nerve supply and significance. *Proc Staff Mayo Clin Proc.* 1959;34(2):39-47.
4. Satheesh MN and Yadav AP. Lip: An impressive and idealistic platform for drug delivery. *J Pharm Res.* 2011;4(4):1060-1062.
5. Millard DR Jr. Refinements in rotation-advancement cleft lip technique. *Plast Reconstr Surg.* 1964;33:26-38. <https://doi.org/10.1097/00006534-196401000-00003>
6. Ham AW. *Histology.* 5th ed. Philadelphia: Lippincott; 1965. p. 647-648.
7. Shafer WG, Hone MK and Levy BM. *A Textbook of Oral Pathology.* 2nd. Philadelphia: Saunders; 1964. p. 11.
8. Kinikoglu B, Damour O and Hasirci V. Tissue engineering of oral mucosa: A shared concept of skin. *J Artif Organs.* 2014;18(1):8-19. <https://doi.org/10.1007/s10047-014-0798-5>
9. Shuster SA, Black MM and Mcvitie EV. The influence of age and sex on skin thickness, skin collagen and density. *Br J Dermatol.* 1975;93(6):639-643. <https://doi.org/10.1111/j.1365-2133.1975.tb05113.x>
10. Alberti I, Kalia YN, Naik A and Guy RH. Assessment and prediction of the cutaneous bioavailability of topical terbinafine, *in vivo*, in man. *Pharm Res.* 2001;18(10):1472-1475. <https://doi.org/10.1023/a:1012217209228>
11. Sánchez-Carpintero I, Candelas D and Ruiz-Rodríguez R. Dermal fillers: Types, indications, and complications. *Actas*

- Dermo-Sifiliogr. 2010;101(5):381-393.
[https://doi.org/10.1016/s1578-2190\(10\)70660-0](https://doi.org/10.1016/s1578-2190(10)70660-0)
12. Dimond RL and Montagna W. Histology and cytochemistry of human skin: XXXVI. The nose and lips. Arch Dermatol. 1976;112(9):1235-1244.
<https://doi.org/10.1001/archderm.1976.01630330005001>
13. Lanfranchi HE and De Rey BM. Comparative morphometric analysis of vermillion border epithelium and lip epidermis. Cells Tissues Organs. 1978;101(2):187-191.
<https://doi.org/10.1159/000144965>
14. Jacobi U, Toll R, Audring H, Sterry W and Lademann J. The porcine snout an *in vitro* model for human lips? Exp Dermatol. 2005;14(2):96-102.
<https://doi.org/10.1111/j.0906-6705.2005.00223.x>

Authors' Contributions:

SS and AKP- Concept and design of study, prepared first draft of manuscript; **KB and AnR**- Interpreted the result: Reviewd the literature and manuscript preparation; **JC, ArR and SP**-Concept, coordination, statistical analysis and interpretation, preparation of manuscript and revision of manuscript.

Work attributed to:

King George Medical University, Lucknow - 226 003, Uttar Pradesh, India.

Orcid ID:

Swati Saxena - <https://orcid.org/0000-0002-4082-2733>
Arvind Kumar Pankaj - <https://orcid.org/0000-0002-4270-0756>
Kanchan Bisht - <https://orcid.org/0000-0002-4615-1352>
Anita Rani - <https://orcid.org/0000-0001-9832-8781>
Jyoti Chopra - <https://orcid.org/0000-0002-3418-8617>
Archana Rani - <https://orcid.org/0000-0003-3057-7743>

Source of Support: Nil, **Conflicts of Interest:** None declared.