

# Cooccurrence of anti-N-methyl-D-aspartate receptor encephalitis and COVID-19 infection – Case series of two patients with a brief review of literature



Joydeep Mukherjee<sup>1</sup>, Sheetal Goyal<sup>1</sup>, Faheem Arshad<sup>2</sup>, Saraswati Nashi<sup>2</sup>, Srijithesh PR<sup>3</sup>, Girish Baburao Kulkarni<sup>3</sup>, Suvarna Alladi<sup>4</sup>

<sup>1</sup>Senior Resident, <sup>2</sup>Assistant Professor, <sup>3</sup>Professor, <sup>4</sup>Professor and Head, Department of Neurology, National Institute of Mental Health and Neuro Sciences, Bengaluru, Karnataka, India

Submission: 26-03-2022

Revision: 26-07-2022

Publication: 01-08-2022

## ABSTRACT

Anti-N-methyl-D-aspartate receptor (NMDAR) encephalitis is a clinical condition characterized by a myriad of psychiatric symptoms, abnormal movements, autonomic instability, seizures, and encephalopathy. Coronavirus disease-19 (COVID-19) infection is infrequently present with altered mental status. As the days of the COVID-19 pandemic pass, more and more awareness of its different types of immunological reactions are unveiled. A wide spectrum of clinical, pathological, and radiological manifestations has been reported. However, there have only been a few cases where anti-NMDAR antibodies have been found in people who have COVID-19. Herein, we reported two cases with simultaneous anti-NMDAR antibody and COVID-19 infection detection. Both cases clinically responded after treatment with an immunomodulator, showing significant improvement, and were discharged in a conscious and ambulatory state. Autoimmune encephalitis should be thought about if there are neurological symptoms associated with SARS-CoV-2 infection, and immunomodulators should be given to such patients.

**Key words:** Corona-virus disease-19; Anti-N-methyl-D-aspartate receptor antibodies; Encephalitis; India

### Access this article online

**Website:**

<http://nepjol.info/index.php/AJMS>

**DOI:** 10.3126/ajms.v13i8.44089

**E-ISSN:** 2091-0576

**P-ISSN:** 2467-9100

Copyright (c) 2022 Asian Journal of Medical Sciences



This work is licensed under a Creative Commons Attribution-NonCommercial 4.0 International License.

## INTRODUCTION

Coronavirus disease 2019 (COVID-19) is a disease with a wide range of phenotypic presentations and clinical syndromes ranging from acute respiratory distress syndrome (ARDS), severe metabolic syndromes, thromboembolic syndrome, severe acute tubular necrosis, various neurologic abnormalities, and cardiac events, including myocarditis and arrhythmias to acute viral encephalitis, infectious, toxic encephalopathy, and acute cerebrovascular disease, and possible epileptogenicity along with multiple organ dysfunction.<sup>1,2</sup> Mechanisms of SARS-CoV-2 neurologic manifestations noted in the literature are: Direct infection injury through the blood circulation and neuronal pathways,

hypoxic injury, immune-mediated injury, and angiotensin-converting enzyme II receptor-mediated injury, among others.<sup>1,3</sup> Immune-mediated neurological manifestations known to date include Guillain-Barré and Miller-Fisher syndromes, polyneuritis cranialis, and acute demyelinating encephalomyelitis.<sup>4</sup>

Anti-NMDAR encephalitis typically presents with cognitive and behavioral dysfunction, speech dysfunction, seizures, movement disorders, decreased level of consciousness, and autonomic instability. A paraneoplastic association with ovarian teratoma is also known.<sup>5</sup> However, atypical manifestations in the form of the demyelinating syndrome, post-herpes virus encephalitis, and isolated epileptic

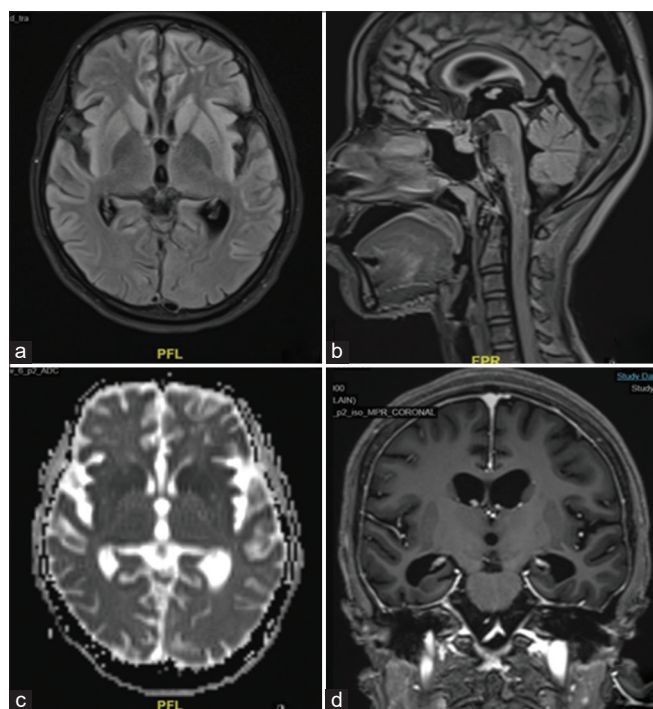
### Address for Correspondence:

Joydeep Mukherjee, Flat no 302, Block B, Madhumalancha Housing Complex, Pulin Avenue, Kolkata - 700 081, West Bengal, India.

**Mobile:** +91-9836510228. **E-mail:** joydeepdoc@gmail.com

syndrome are also described.<sup>5</sup> In addition, it was reported that anti-NMDAR antibody-positive patients very often do not fulfill the probable diagnostic criteria.<sup>5,6</sup>

We describe two patients with grey and white matter abnormalities suggestive of an inflammatory-demyelinating process associated with a prolonged hypoactive encephalopathy related to COVID-19 infection.



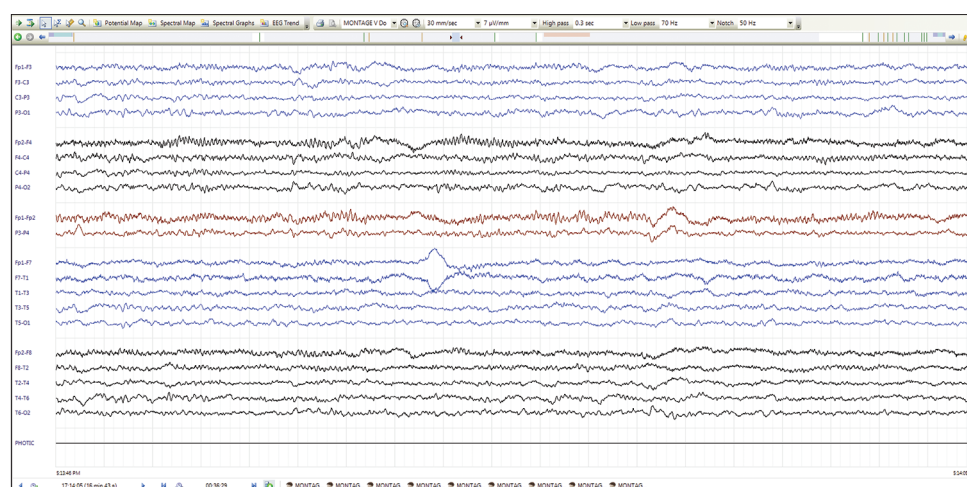
**Figure 1:** Magnetic resource imaging brain of the first patient – T2-FLAIR hyperintensity noted involving bilateral caudate, putamen, bilateral frontal, and parietal, insular, temporal lobe cortices (1A). Enhancement of the pituitary stalk noted (1B)-mild diffusion restriction and sparing of the motor cortex (1C). Diffuse pachymeningeal enhancement was noted in the postcontrast study (1D). No areas of any blooming were noted

## CASE SERIES

### Case 1

A 21-year-old lady was presented with headaches, giddiness, and imbalance while walking for 5 days and decreased speech output for 4 days. She also had a fever and new-onset right focal seizures 1 day before admission, followed by persistent confusion, altered sleep, visual hallucinations, and mutism. On examination, she was tachypneic (RR-24/min), the temperature was 100.1°F, and oxygen saturation was 92% on room air. She was disoriented, had no sense of time, place, or person, and could not follow simple commands. In addition, she had terminal neck rigidity with a lack of movement in the right upper and lower limbs.

A nasopharyngeal swab for COVID-19 rapid antigen tested positive which was later verified with real-time polymerase chain reaction (RT-PCR) test. Her HRCT chest had right middle and lower lobe consolidation. Serum and cerebrospinal fluid (CSF) autoimmune encephalitis profiles showed an anti-NMDAR antibody strongly positive (Indirect immunofluorescence assay on transfected cell lines for qualitative determination). Ultrasonography of the abdomen and pelvis was normal. The patient had a normal metabolic panel, including thyroid profile, serum electrolytes, liver, and renal function tests, serum glucose, homocysteine, Vitamin B12, and folate. The CSF had one cell (lymphocyte), normal protein (16.2 mg/dL), and normal glucose (99 mg/dL). Septic workup showed high D-dimer, ESR, and CRP, with negative blood and urine cultures. Other workups, such as CSF for other viral and bacterial panels, were negative. T2-FLAIR hyperintensity was observed on magnetic resonance imaging (MRI) brain, involving bilateral caudate, putamen, frontal and parietal, insular, and temporal lobe cortices, with mild diffusion restriction and motor cortex sparing. Diffuse



**Figure 2:** Electroencephalography of the first patient – bipolar montage showing intermittent theta slowing in bilateral temporal regions

pachymeningeal enhancement was noted in the post-contrast study. Enhancement of the pituitary stalk was noted (Figure 1). Electroencephalography (EEG) showed intermittent theta slowing in bilateral temporal regions (Figure 2).

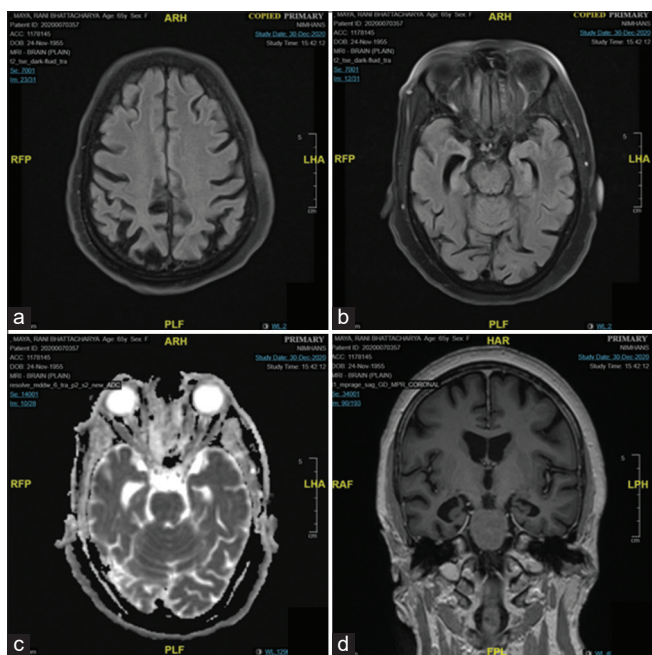
She was started empirically on antibiotics (acyclovir, ceftriaxone, and ampicillin). She also received remdesivir and phenytoin. During her hospital stay, she developed dystonic posturing of all four limbs, which improved on baclofen and trihexyphenidyl. She was treated with ten

cycles of small volume plasmapheresis. The patient had a slow clinical recovery with improved consciousness and no further seizures. After 10 days of treatment, the COVID-19 test was negative, but the NMDA test remained strongly positive.

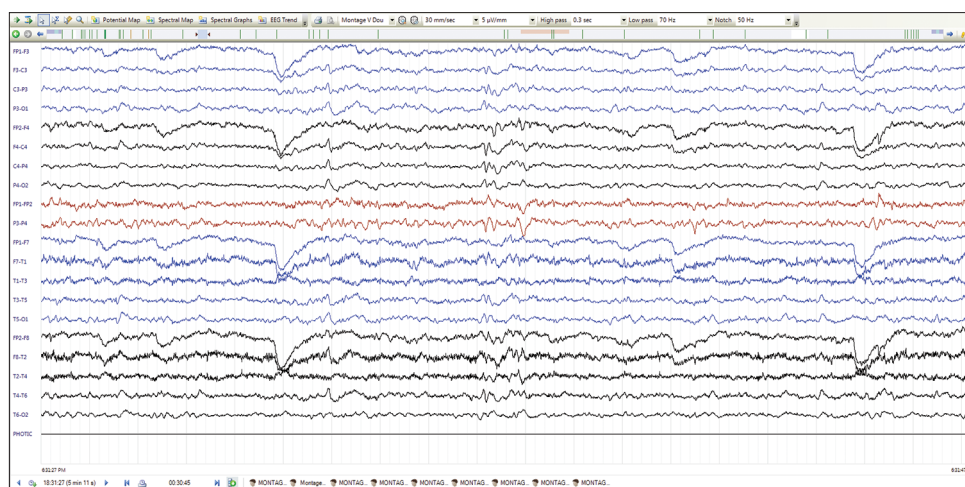
**Case 2**

This 65-year-old lady was presented with a 5-year history of slowly progressive recent episodic memory impairment for verbal and visual, a visuospatial deficit from the past 4 years, and a rapid worsening of these symptoms for the past 1 month. On examination, her vitals were normal. The patient appeared to be slightly disoriented in terms of time, place, and person. She had impaired attention, episodic memory, and visuospatial abilities with relatively normal language, praxis, and behavior. She had asymmetrical rigidity (left > right) with normal power, sensory, cerebellar functions and reflexes.

The nasopharyngeal swab COVID-19 RT-PCR test was positive, with HRCT chest being normal. The serum autoimmune encephalitis profile showed anti-NMDAR antibody positivity. Ultrasonography of the abdomen and pelvis was normal. A normal metabolic panel, including thyroid profile, serum electrolytes, liver and renal function tests, serum glucose, homocysteine, Vitamin B12, and folate. The CSF contained no cells and had normal protein (24.3 mg/dL) and glucose (69 mg/dL); the anti-NMDAR antibody in the CSF was negative. The CSF for other viral and bacterial panels was negative. MRI showed bilateral cerebral atrophy predominantly affecting parietotemporal regions. The cortical sulci and Sylvian fissures are prominent. Multiple discrete foci of T2/FLAIR hyperintensities are noted in the bilateral subcortical, deep, and periventricular white matter (Figure 3). The EEG showed sharp waves in the right-sided posterior head region (Figure 4).



**Figure 3:** Magnetic resource imaging brain of the second patient - Bilateral cerebral atrophy predominantly affecting parietotemporal regions (2A). Multiple discrete foci of T2/FLAIR hyperintensities are noted in the bilateral subcortical, deep, and periventricular white matter (2B). No diffusion restriction (2C), enhancement, and blooming were noted. The cortical sulci and Sylvian fissures are prominent (2D)



**Figure 4:** Electroencephalography of the second patient – bipolar montage showing the right temporoparietal spike

She was treated with injectable methylprednisolone for 3 days and an acetylcholinesterase inhibitor, donepezil, for long-standing memory disturbances, along with remdesivir. She improved partially in cognition with a full improvement in rigidity. On repeat, the COVID-19 RT-PCR test and serum anti-NMDAR antibody became negative.

We followed up with the patients for the next 5 months and found clinical improvement in both.

## DISCUSSION

We described two cases of COVID-19 infection associated with anti-NMDAR antibody positivity (table 1). Although the second patient had a background of possible Alzheimer's dementia, her unusual deterioration in the clinical course can be explained by COVID-19 infection with anti-NMDAR encephalitis. Both our patients showed significant recovery following immunotherapy with steroids and plasmapheresis.

**Table 1: Review of literature of COVID-19 infection and NMDA encephalitis cooccurrence**

Author	Study type	Age	Sex	Country	Neurological symptoms associated	Autoimmune panel	Imaging	Treatment	Outcome
Burr et al., 2020 <sup>10</sup>	CR	23	F	USA	Encephalopathy, hyperkinetic movement of arms, legs, and head	NMDAR-IgG positivity in the serum (1:640)	Normal	IV steroids and IVIG	Baseline state after 2 weeks
Fakhri et al., 2021 <sup>11</sup>	CR	18	F	Iran	GTCS. Mood change as depression and anhedonia, lack of concentration,	CSF IIFT-NMDA positive	Generalized brain edema	IV steroids and IVIG	2 months-full recovery
Monti et al., 2020 <sup>12</sup>	CR	50	M	Italy	Psychiatric symptoms (confabulations and delirious ideas), focal motor seizures with impaired awareness, and orofacial dyskinesia/ automatism	CSF- NMDA positive	Normal	IV steroids, IVIG, and plasmapheresis	4 months-full recovery
Adelaide Panariello et al., 2020 <sup>13</sup>	CR	23	M	Italy	psychomotor agitation, anxiety, thought disorganization, persecutory delusions, auditory hallucinations commanding voices, global insomnia	CSF- NMDA positive	NA	IV steroids and IVIG	Improved
Sarigecili et al., 2021 <sup>14</sup>	CR	7	M	Turkey	dysphagia, dyskinesia, and autonomic instabilities	CSF NMDA-positive	Normal	IV steroids, IVIG and plasmapheresis	discharged with mild ataxia
Our study case one	CR	21	F	India	Unsteady gait, somnolence, seizures, choreiform movements in the hands and feet, tongue protrusion, bruxism, lip smacking, agitation, catatonia, and echolalia.	Serum and CSF NMDA positive	T2/FLAIR hyperintensity bilateral frontal, temporal, parietal, striatum, and insula	Plasmapheresis	Improved
Our study case two	CR	65	F	India	Encephalopathy, unsteady gait, altered sleep, visual hallucination, and mutism	Rapidly worsening dementia	Multiple T2/FLAIR hyperintensity in bilateral subcortical, deep and periventricular white matter	IV steroid	Improved

CR: Case report, CSF: Cerebrospinal fluid, IV: Intravenous, IVIG: Intravenous immunoglobulin, M: Male, F: Female

MRI diffusion images did not display diffusion restriction, rendering ischemia secondary to respiratory involvement due to COVID-19 infection unlikely. Studies have shown a significant role of elevated interleukin-6 (IL-6) in the pathogenesis of the complicated COVID-19 patients,<sup>7</sup> similar to the anti-NMDAR antibody disease<sup>8,9</sup> favoring similar immunopathogenesis. Additional mechanisms of indirect pathogenesis, such as molecular mimicry in which a viral epitope is structurally identical to an NMDAR epitope, could be another possible explanation of their cooccurrence(A). Few cases in the world of “COVID-19 infection with NMDA” reported to date are summarized in Table 1. Due to financial constraints, IL-6 was not measured in either of the patients. This was a limitation in our study.

To the best of our knowledge, this is the first report of anti-NMDAR encephalitis associated with a recent SARS-CoV-2 infection in Indian populations.

## CONCLUSION

COVID-19 can affect both the central and peripheral nervous systems, despite being a respiratory pathogen. Anti-NMDAR encephalitis is a treatable entity. Understanding the rare association between COVID-19 infection and NMDA seropositivity can open up new avenues for fighting the virus and should be considered as a possibility during unexplained neurological worsening of COVID-19 infection.

## REFERENCES

1. Wu Y, Xu X, Chen Z, Duan J, Hashimoto K, Yan L, et al. Nervous system involvement after infection with COVID-19 and other coronaviruses. *Brain Behav Immun*. 2020;87:18-22. <https://doi.org/10.1016/j.bbi.2020.03.031>
2. Liu K, Chen Y, Lin R and Han K. Clinical features of COVID-19 in elderly patients: A comparison with young and middle-aged patients. *J Infect*. 2020;80(6):e14-e18. <https://doi.org/10.1016/j.jinf.2020.03.005>
3. Baig AM, Khaleeq A, Ali U and Syeda H. Evidence of the COVID-19 virus targeting the CNS: Tissue distribution, host-virus interaction, and proposed neurotropic mechanisms. *ACS Chem Neurosci*. 2020;11(7):995-998. <https://doi.org/10.1021/acschemneuro.0c00122>
4. Lopes CC, Brucki SM, Passos Neto CE, Corazza LA, Baima JP, Fiorentino D, et al. Acute disseminated encephalomyelitis in COVID-19: Presentation of two cases and review of the literature. *Arq Neuropsiquiatr*. 2020;78(12):805-810. <https://doi.org/10.1590/0004-282x20200186>
5. Kaneko A, Kaneko J, Tominaga N, Kanazawa N, Hattori K, Ugawa Y, et al. Pitfalls in clinical diagnosis of anti-NMDA receptor encephalitis. *J Neurol*. 2018;265(3):586-596. <https://doi.org/10.1007/s00415-018-8749-3>
6. Graus F, Titulaer MJ, Balu R, Benseler S, Bien CG, Cellucci T, et al. A clinical approach to diagnosis of autoimmune encephalitis. *Lancet Neurol*. 2016;15(4):391-404. [https://doi.org/10.1016/S1474-4422\(15\)00401-9](https://doi.org/10.1016/S1474-4422(15)00401-9)
7. Coomes EA and Haghbayan H. Interleukin-6 in Covid-19: A systematic review and meta-analysis. *Rev Med Virol*. 2020;30(26):1-9. <https://doi.org/10.1002/rmv.2141>
8. Ding H, Jian Z, Stary CM, Yi W and Xiong X. Molecular pathogenesis of Anti-NMDAR encephalitis. *BioMed Res Int*. 2015;2015:643409. <https://doi.org/10.1155/2015/643409>
9. Byun JI, Lee ST, Moon J, Jung KH, Sunwoo JS, Lim JA, et al. Distinct intrathecal interleukin-17/interleukin-6 activation in anti-N-methyl-D-aspartate receptor encephalitis. *J Neuroimmunol*. 2016;297:141-147. <https://doi.org/10.1016/j.jneuroim.2016.05.023>
10. Burr T, Barton C, Doll E, Lakhotia A and Sweeney M. N-methyl-D-aspartate receptor encephalitis associated with COVID-19 infection in a toddler. *Pediatr Neurol*. 2021;114:75-76. <https://doi.org/10.1016/j.pediatrneurol.2020.10.002>
11. Allahyari F, Hosseinzadeh R, Nejad JH, Heiat M and Ranjbar R. A case report of simultaneous autoimmune and COVID-19 encephalitis. *J Neurovirol*. 2021;27(3):504-506. <https://doi.org/10.1007/s13365-021-00978-w>
12. Monti G, Giovannini G, Marudi A, Bedin R, Melegari A, Simone AM, et al. Anti-NMDA receptor encephalitis presenting as new onset refractory status epilepticus in COVID-19. *Seizure*. 2020;81:18-20. <https://doi.org/10.1016/j.seizure.2020.07.006>
13. Panariello A, Bassetti R, Radice A, Rossotti R, Puoti M, Corradin M, et al. Anti-NMDA receptor encephalitis in a psychiatric Covid-19 patient: A case report. *Brain Behav Immun*. 2020;87:179-181. <https://doi.org/10.1016/j.bbi.2020.05.054>
14. Sarigecili E, Arslan I, Ucar HK and Celik U. Pediatric anti-NMDA receptor encephalitis associated with COVID-19. *Childs Nerv Syst*. 2021;37(12):3919-3922. <https://doi.org/10.1007/s00381-021-05155-2>

### Authors Contribution:

**JM and SG-** Concept, data acquisition, and manuscript writing; **FA and SN-** Manuscript writing and literature review; and **PRS, GBK, and SA-** Manuscript editing and manuscript review.

### Work attributed to:

Department of Neurology, National Institute of Mental Health and Neuro Sciences, Bengaluru, Karnataka, India.

### Orcid ID:

Joydeep Mukherjee - <https://orcid.org/0000-0003-0056-1150>  
 Sheetal Goyal - <https://orcid.org/0000-0003-2785-7584>  
 Faheem Arshad - <https://orcid.org/0000-0002-2102-7937>  
 Saraswati Nashi - <https://orcid.org/0000-0002-3184-2345>  
 Srijithesh PR - <https://orcid.org/0000-0003-4979-1862>  
 Girish Baburao Kulkarni - <https://orcid.org/0000-0001-5527-2642>  
 Suvarna Alladi - <https://orcid.org/0000-0002-0372-9572>

**Source of Funding:** None, **Conflicts of Interest:** None.