

# Teratogenic effects of Propylthiouracil on Swiss albino mice fetuses – A gross study



Samta Tiwari<sup>1</sup>, S K Pandey<sup>2</sup>, Anand Mishra<sup>3</sup>

<sup>1</sup>Assistant Professor, Department of Anatomy, Shri Ram Murti Smarak Institute of Medical Sciences, Bareilly, Uttar Pradesh, India, <sup>2</sup>Professor and Head, Department of Anatomy, Heritage Institute of Medical Sciences, Varanasi, Uttar Pradesh, India, <sup>3</sup>Professor, Department of Anatomy, Institute of Medical Sciences, Banaras Hindu University, Varanasi, Uttar Pradesh, India.

Submission: 22-03-2022

Revision: 23-06-2022

Publication: 01-08-2022

## ABSTRACT

**Background:** Propylthiouracil is an antithyroid drug used to treat hyperthyroidism in pregnancy, as euthyroid state is necessary for optimal pregnancy outcome. Few reports of fetal anomalies are associated with propylthiouracil use as compared to other antithyroid drugs, having severe teratogenic profile. **Aims and Objectives:** The present study has been conducted to divulge the teratogenic profile of propylthiouracil by observing its gross effects on mice fetuses, as limited data are available despite extensive usage of drug in pregnancy. **Materials and Methods:** A 100 mg/kg body weight/day of propylthiouracil was orally administered to pregnant Swiss albino mice on the 6<sup>th</sup>, 7<sup>th</sup>, and 8<sup>th</sup> days of gestation (treated group), while distilled water was given orally to pregnant dams of the control group (same volume and for same duration). The fetuses were collected, weighed, and studied for gross abnormalities after sacrificing the pregnant dams on the 18<sup>th</sup> day of conception. **Results:** In the present study, the treated group shows reduction in various growth parameters (mean body weight, mean crown-rump length, etc.) depicting growth retardation, in comparison to the control group. On examination, engorged cutaneous vessels, external hemorrhage, and omphalocele were also observed in the treated group. **Conclusion:** As propylthiouracil is observed to have teratogenic outcome, hyperthyroidism during the first trimester must be treated with minimum effective dose of the drug.

**Key words:** Propylthiouracil; Hyperthyroidism; Teratogenic profile; Growth parameters

### Access this article online

**Website:**

<http://nepjol.info/index.php/AJMS>

**DOI:** 10.3126/ajms.v13i8.43947

**E-ISSN:** 2091-0576

**P-ISSN:** 2467-9100

Copyright (c) 2022 Asian Journal of Medical Sciences



This work is licensed under a Creative Commons Attribution-NonCommercial 4.0 International License.

## INTRODUCTION

Teratology is the science which deals with the study of anomalous growth and differentiation causing congenital malformations in fetus when a female is exposed to certain exogenous agents during pregnancy. Documentation of teratogenic potential of these agents is essential as they are producing huge burden on health expenditure and is a poor health indicator for any country, worldwide. Awareness about these agents would facilitate medical professionals and expecting mothers to curtail the fetal exposure, which help in reducing congenital abnormalities.<sup>1</sup>

Propylthiouracil is an antithyroid thioureyline drug, belonging to the family of thionamides. Propylthiouracil and methimazole/carbimazole are the antithyroid drugs

used for the treatment of hyperthyroidism in pregnancy. Propylthiouracil presently is considered the safest drug to treat hyperthyroidism during early pregnancy.<sup>2</sup> The most common cause of pregnancy-associated hyperthyroidism is Graves' disease.<sup>3</sup> The pathogenesis of Graves' disease is the formation of autoantibodies against thyrotropin receptor resulting in excessive thyroid hormone secretion and goiter.<sup>4,5</sup> Graves' disease during pregnancy must be treated effectively, as it is crucial for desirable pregnancy results. Hyperthyroidism during pregnancy may cause concomitant increased maternal and fetal complications such as miscarriage, prematurity, low birth weight, fetal death, pre-eclampsia, and thyroid storm.<sup>6,7</sup>

Conventionally, propylthiouracil has been preferred over methimazole because transplacental passage was thought to be lower.<sup>8</sup> For the reason that, a limited number of

### Address for Correspondence:

Dr. Samta Tiwari, Assistant Professor, Department of Anatomy, Shri Ram Murti Smarak Institute of Medical Sciences, Bareilly - 243 202, Uttar Pradesh, India. **Mobile:** +91-7052305965. **E-mail:** doctorsamta@gmail.com

cases of fetal anomalies are related with antenatal use of propylthiouracil, it has been presumed to have favorable teratogenic profile than methimazole and hence acclaimed its usage in pregnancy.<sup>6,9</sup> However, propylthiouracil antenatal use is also been associated with birth defects, though small, since its introduction.<sup>10-12</sup> Thus, it has been advised to restrict propylthiouracil use to the first trimester of pregnancy and later changed to methimazole, to abate maternal and fetal risks.<sup>7,13-15</sup> Hence, the present study aims to discover out convincing data regarding its teratogenic profile by observing fetal gross abnormalities when drug is given during early period of organogenesis.

### Aims and objectives

The present study has been conducted to divulge the teratogenic profile of propylthiouracil by observing its gross effects on mice fetuses, as limited data are available despite extensive usage of drug in pregnancy.

## MATERIALS AND METHODS

After the prior approval of the Institute Animal Ethical Committee (No. Dean/2015/CAEC/989, dated January 19, 2015), the study was conducted in the Teratology laboratory of the Department of Anatomy, Institute of Medical Sciences, Banaras Hindu University, Varanasi, Uttar Pradesh, India.

Twenty-one adult female Swiss albino mice with average body weight of 20–25 g were studied. The animals were housed individually in departmental animal house under optimal conditions for breeding. To facilitate mating, female mice were shifted to the cages containing male mice of same stock in the evening (two male per female). The presence of vaginal plug on the following morning indicates pregnancy and was considered as “Day 0” of gestation.

The pregnant dams were allocated two separate groups, one “control” and another, “treated.” Propylthiouracil is commercially available as tablet, containing 50 mg of the drug. Average weight of mice was 20 g and the average dose was worked out per mice to be 100 mg/kg body weight/day, as higher doses were lethal to mice. The stock solution of propylthiouracil was prepared under sterile conditions by pounding the drug (50 mg tablet) and dissolving it in 5 ml of distilled water. Hence, 1 ml of stock solution contains 10 mg of drug. Therefore, the amount of stock solution calculated per mice was 0.2 ml which contains 2 mg of propylthiouracil. The treated group was given 2 mg (100 mg/kg body wt./day) of the drug (orally) from the stock solution (0.2 ml) while the control mice were given 0.2 ml distilled water (orally) on the 6<sup>th</sup>, 7<sup>th</sup>, and 8<sup>th</sup> day of gestation.

The pregnancy was terminated by sacrificing dams near term by cervical dislocation. A midline laparotomy was done to exteriorize the uterine horns. The photographs of uterine horns with its content were taken and the sacs were inspected for resorption sites. The fetuses of both groups were collected, blotted dry with blotting paper, and weighed. The crown-rump length (CRL) and tail length of the fetuses of both groups were recorded with the help of graph paper.

All collected fetuses of both groups were photographed for their general appearance and gross malformations. Each fetus of both the groups was photographed in the right lateral, left lateral and ventral views. Data for both groups were recorded for various fetal parameters, that is, body weight, CRL, tail length. The independent t-test, considering  $P < 0.05$  significant, was used for statistical analysis with the help of SPSS, version 23.

## RESULTS

There was no significant difference of weight gain in treated mother mice as compared to the control. The resorption in the treated group was found to be six out of 71 implantations (8.62%), whereas no resorption was observed in the control group (Table 1).

The difference between various growth parameters such as mean weight, mean CRL, and mean tail length of fetuses of the control and treated group was found to be statistically significant, as shown in Table 2.

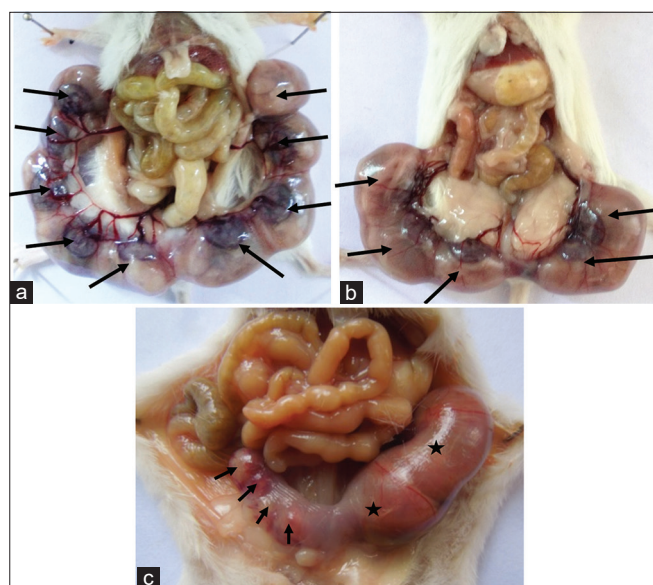
The gross inspection of uterine horns in mother mice showed decreased number of fetuses in the treated group (Figure 1b) as compared to the control (Figure 1a). Resorption sites were observed in the uterine horns of treated mice (Figure 1c). On gross examination, the fetuses of the treated group showed growth retardation and engorged cutaneous vessels. There were engorged cutaneous vessels on trunk and dorsal aspect of forelimb, seen in the right lateral view of three treated cases (Figure 2a). In two cases, the engorged cutaneous vessels had been observed on dorsal aspect of the left forelimb. The generalized hemorrhagic areas were observed on the left lateral view, in four cases (Figure 2b). Similar findings had been found on the right lateral and ventral parts in

**Table 1: Pregnancy outcomes of both the control and treated groups**

	Control	Treated
Total number of mother mice	6	15
Implantation	35	71
Resorption	0	6
Live fetuses	35	65

	Group	n	Mean	SD	S.E.	P-value
Fetal weight	Control	35	1.42915	0.070838	0.011973	<0.005
	Treated	65	1.31530	0.230277	0.028562	
Crown-rump length	Control	35	2.38289	0.682560	0.115373	<0.001
	Treated	65	2.25538	1.862716	0.231041	
Tail length	Control	35	1.24653	0.48449	0.081886	<0.001
	Treated	65	1.17076	0.947415	0.117512	

P<0.005 significant. N: No. of fetuses, SD: Standard deviation, S.E.: Standard error



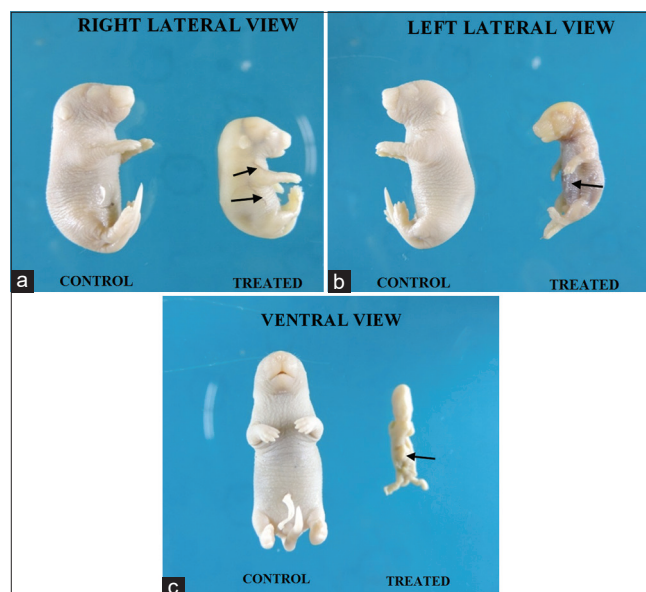
**Figure 1:** Photographs of uterine horns (mother mice) in the control and treated groups. (a) Control uterine horns showing five fetuses (→) in the right and four fetuses (←) in the left uterine horns. (b) Treated uterine horns showing three fetuses (→) in the right and two fetuses (←) in the left uterine horns. (c) Treated uterine horns showing four resorption sites (→) on the right and two fetuses in the left horns (★)

same four cases. In one treated case, the ventral view showed absence of anterior abdominal wall (omphalocele) (Figure 2c). No such abnormalities were seen in the control group.

## DISCUSSION

Propylthiouracil, a thionamide-derived antithyroid drug, has been used in the treatment of hyperthyroidism, in early period of pregnancy. As the reports from the previous studies were inconclusive regarding teratogenic effects of propylthiouracil, so this study was intended to see its teratogenic effect on pregnancy and fetus. In the present study, 100 mg/kg body weight of propylthiouracil was given to the pregnant Swiss albino mice during early period of organogenesis.

The present study showed that the propylthiouracil exposure during embryogenesis was associated with fetal loss, similar to a previous study.<sup>2</sup> The present study



**Figure 2:** Gross photographs of fetuses of the control and treated groups. (a) The right lateral view of control and treated fetuses. The treated fetus shows growth retardation with engorged cutaneous vessels on trunk and forelimb as compared to the control (→). (b) The left lateral view of control and treated fetuses. The treated fetus shows growth retardation and generalized hemorrhagic areas on trunk (←). (c) Ventral view of control and treated fetuses. The treated fetus shows the absence of anterior abdominal wall (omphalocele) (←)

also revealed decrease in litter size in more than 90% of cases and resorption was observed in 8.62% of cases in the treated group, differing from a previous study which showed no effect on litter size and resorption rates.<sup>16</sup>

In a case–control study, increased risk of intrauterine growth retardation in women treated with propylthiouracil during pregnancy was observed.<sup>17</sup> The fetuses of the treated group in the present study showed growth retardation as the fetal body weight and CRL was found to be decreased significantly. In the study done by Mallela et al.<sup>16</sup> there were 2 experimental animals (mice and rat) and study of different doses for different antithyroid drugs and gestational age were done. In mice fetuses no abnormalities were observed while in rat fetuses abnormalities were found similar to present study. Similar study showed significant increase in CRL of mice fetuses when drug was given from gestation day 7–9, but significant decrease was observed when it was given from gestation day 3–7.<sup>2</sup>



A significant decrease in tail length of treated fetuses has also been observed in the present study, which was not revealed earlier, especially in mice fetuses. However, van Veenendaal et al.,<sup>18</sup> found wavy, short, and/or kinked tail in *Xenopus* embryo exposed to 1 mM of propylthiouracil. In the present study, engorged cutaneous vessels on forelimb and trunk of treated fetuses have been observed. Subcutaneous hemorrhages on trunk and hemorrhagic spots on snout and foot were also seen in treated mice fetuses. While in a previous study, subcutaneous hemorrhages on the trunk and leg along with focal hemorrhages at umbilicus and urinary bladder have been observed. In the same study, blood was found in various cavities such as nasal, oral, abdominal, and pleural cavities.<sup>16</sup>

Several researchers documented gross defects such as anencephaly, cleft lip or palate, defective ear lobe, aplasia cutis congenita, and pre-auricular cyst/sinus in children exposed antenatally to propylthiouracil,<sup>17,19-21</sup> while Korelitz et al.,<sup>22</sup> did not observe any of these birth defects. In the present study also, these birth defects were not found in mice fetuses exposed to propylthiouracil. Omphalocele was observed in children exposed to propylthiouracil during intrauterine period.<sup>19,20</sup> Similar finding was also observed in mice fetus of the treated group in the present study. Many workers<sup>17,20-22</sup> reported abnormalities of other systems such as cardiac, respiratory, and urogenital system in human study which was unreported in the present study.

Propylthiouracil can freely cross the placental barrier and may inhibit fetal thyroid function, which, in turn, may lead to intrauterine growth retardation, low birth weight, fetal hypothyroidism, and fetal thyroid dysfunction with or without goiter.<sup>6-8</sup> All antithyroid drugs may inhibit fetal thyroid function causing fetal hypothyroidism. Propylthiouracil-induced hypo- or hyperthyroidism may be the probable cause of congenital anomalies as seen in the present study.

Yu et al.,<sup>23</sup> proposed that propylthiouracil was associated with ANCA (anti-neutrophil cytoplasmic antibody)-positive vasculitis and the presence of AECA (anti-endothelial cell antibodies). In the initial phase of ANCA-positive vasculitis, endothelial damage is crucial phenomenon and AECA could induce endothelium damage by antibody-dependent cellular cytotoxicity. The damaged endothelium causes leakage of blood into intercellular spaces and engorged subcutaneous vessels. This may be correlated with the subcutaneous and focal hemorrhages found in the present study.

#### Limitations of the study

As this is an experimental animal study, the results cannot be directly extrapolated to human beings. Hence, there

is need of large randomized clinical trial to ascertain the teratogenic potential of Propylthiouracil.

## CONCLUSION

Propylthiouracil is used globally to treat pregnancy-associated hyperthyroidism, especially during the first trimester, as it has low toxicity profile compared to other available treatment modalities. However, the present study reported its teratogenic potential in developing fetus, especially in high dose.

Taking this result into consideration from present animal study, vigilant monitoring becomes obligatory for this drug. Based on various gross findings of the present study, propylthiouracil was found to be teratogenic at a dose of 100 mg/kg of body weight during early period of organogenesis. Propylthiouracil use cannot be completely evaded as treatment option in pregnant women with hyperthyroidism, though it is associated with increased risk of fetal malformations. Hence, until safety of propylthiouracil is established, pregnancy-associated hyperthyroidism must be treated with minimal effective dose. This study also raises the necessity for a large randomized clinical trial of propylthiouracil or the search of a newer and safer treatment modality.

## ACKNOWLEDGMENT

The authors would like to sincerely thank all the teaching and non-teaching faculty of Department of Anatomy, Institute of Medical Sciences, Banaras Hindu University for their support and pay homage to all the mice who lost their lives during the study in serving humanity.

## REFERENCES

1. Robert BL. Benedectin: Review of medical literature of a comprehensively studied human nonteratogen and the most prevalent tortogen-litigen. *Reprod Toxicol*. 1995;9(4):337-349. [https://doi.org/10.1016/0890-6238\(95\)00020-b](https://doi.org/10.1016/0890-6238(95)00020-b)
2. Benavides VC, Mallela MK, Booth CJ, Wendler CC and Rivkees SA. Propylthiouracil is teratogenic in murine embryos. *PLoS One*. 2012;7:e35213. <https://doi.org/10.1371/journal.pone.0035213>
3. Patil-Sisodia K and Mestman JH. Graves' hyperthyroidism and pregnancy: A clinical update. *Endocr Pract* 2010;16(1):118-129. <https://doi.org/10.4158/EP09233.RA>
4. Weetman AP. Graves' disease. *Horm Res*. 2003;59(Suppl 1):114-118. <https://doi.org/10.1159/000067837>
5. Cooper DS. Antithyroid drugs. *N Engl J Med*. 2005;352(9):905-917. <https://doi.org/10.1056/NEJMra042972>
6. Chan GW and Mandel SJ. Therapy insight: Management of Graves' disease during pregnancy. *Nat Clin Pract Endocrinol*

- Metab. 2007;3(6):470-478.  
<https://doi.org/10.1038/ncpendmet0508>
7. Bahn RS, Burch HS, Cooper DS, Garber JR, Greenlee CM, Klein IL, et al. The role of propylthiouracil in the management of Graves' disease in adults: Report of a meeting jointly sponsored by the American thyroid association and the food and drug administration. *Thyroid*. 2009;19(7):673-674.  
<https://doi.org/10.1089/thy.2009.0169>
  8. Mortimer RH, Cannell GR, Addison RS, Johnson LP, Roberts MS and Bernus I. Methimazole and propylthiouracil equally cross the perfused human term placental lobule. *J Clin Endocrinol Metab*. 1997;82(9):3099-3102.  
<https://doi.org/10.1210/jcem.82.9.4210>
  9. Mandel SJ and Cooper DS. The use of antithyroid drugs in pregnancy and lactation. *J Clin Endocrinol Metab*. 2001;86(6):2354-2359.  
<https://doi.org/10.1210/jcem.86.6.7573>
  10. Herbst AL and Selenkow HA. Hyperthyroidism during pregnancy. *N Engl J Med*. 1965;273:627-633.  
<https://doi.org/10.1056/NEJM196509162731203>
  11. Pearce SH. Spontaneous reporting of adverse reactions to Carbimazole and Propylthiouracil in the UK. *Clin Endocrinol (Oxf)*. 2004;61(5):589-594.  
<https://doi.org/10.1111/j.1365-2265.2004.02135.x>
  12. Briggs GG, Freeman RK and Yaffe SJ. Propylthiouracil. In: *Drugs in Pregnancy and Lactation*. 7<sup>th</sup> ed. Philadelphia, PA: Lippincott Williams and Wilkins; 2005. p. 1365-1370.
  13. Rivkees SA and Mattison DR. Ending propylthiouracil-induced liver failure in children. *N Engl J Med*. 2009;360(15):1574-1575.  
<https://doi.org/10.1056/NEJMc0809750>
  14. Abalovich M, Amino N, Barbour LA, Cobin RH, De Groot LJ, Glinoe D et al. Management of thyroid dysfunction during pregnancy and postpartum: An endocrine society clinical practice guideline. *J Clin Endocrinol Metab*. 2007;92:S1-S7.  
<https://doi.org/10.1210/jc.2007-0141>
  15. Hackmon R, Blichowski M and Koren G. The safety of methimazole and propylthiouracil in pregnancy: A systematic review. *J Obstet Gynaecol Can*. 2012;34(11):1077-1086.  
[https://doi.org/10.1016/S1701-2163\(16\)35438-X](https://doi.org/10.1016/S1701-2163(16)35438-X)
  16. Mallela MK, Strobl M, Poulsen RR, Wendler CC, Booth CJ and Rivkees SA. Evaluation of developmental toxicity of propylthiouracil and methimazole. *Birth Defects Res B Dev Reprod Toxicol*. 2014;101(4):300-307.  
<https://doi.org/10.1002%2Fbdrb.21113>
  17. Chen CH, Xirasagar S, Lin CC, Wang LH, Kou YR and Lin HC. Risk of adverse perinatal outcomes with antithyroid treatment during pregnancy: A nationwide population-based study. *BJOG*. 2011;118(11):1365-1373.  
<https://doi.org/10.1111/j.1471-0528.2011.03019.x>
  18. van Veenendaal NR, Ulmer B, Boskovski MT, Fang XF, Khokha MK, Wendler CC et al. Embryonic exposure to propylthiouracil disrupts left-right patterning in xenopus embryos. *FASEB J*. 2013;27(2):684-691.
  19. Momotani N, Ito K, Hamada N, Ban Y, Nishikawa Y and Mimura T. Maternal hyperthyroidism and congenital malformation in the offspring. *Clin Endocrinol (Oxf)*. 1984;20(6):695-700.  
<https://doi.org/10.1111/j.1365-2265.1984.tb00119.x>
  20. Yoshihara A, Noh J, Yamaguchi T, Ohye H, Sato S, Sekiya K, et al. Treatment of Graves' disease with antithyroid drugs in the first trimester of pregnancy and the prevalence of congenital malformation. *J Clin Endocrinol Metab*. 2012;97(7):2396-2403.  
<https://doi.org/10.1210/jc.2011-2860>
  21. Andersen SL, Olsen J, Wu CS and Laurberg P. Birth defects after early pregnancy use of antithyroid drugs: A Danish nationwide study. *J Clin Endocrinol Metab*. 2013;98(11):4373-4381.  
<https://doi.org/10.1210/jc.2013-2831>
  22. Korelitz JJ, McNally DL, Masters MN, Li SX, Xu Y and Rivkees SA. Prevalence of thyrotoxicosis, anti-thyroid medication use, complications among pregnant women in the United States. *Thyroid*. 2013;23(6):758-765.  
<https://doi.org/10.1089%2Fthy.2012.0488>
  23. Yu F, Zhao MH, Zhang YK, Zhang Y and Wang HY. Anti-endothelial cell antibodies (AECA) in patients with propylthiouracil (PTU) induced ANCA positive vasculitis are associated with disease activity. *Clin Exp Immunol*. 2005;139(3):569-574.  
<https://doi.org/10.1111/j.1365-2249.2005.02725.x>

**Authors Contribution:**

**ST-** Concept and design of the study, prepared first draft of manuscript, statistical analysis, and interpretation; **PSK-** Interpreted the result, concept, and coordination; and **AM** – Reviewed the literature and revision of manuscript.

**Work attributed to:**

Institute of Medical Sciences, Banaras Hindu University, Varanasi 221 005, Uttar Pradesh, India.

**Orcid ID:**

Dr. Samta Tiwari - <https://orcid.org/0000-0002-0275-0572>  
 Prof. S K Pandey - <https://orcid.org/0000-0003-0505-8052>  
 Prof. Anand Mishra - <https://orcid.org/0000-0003-4827-8581>

**Source of Support:** Nil, **Conflict of Interest:** None declared.