

# Pattern of ossicular chain involvement in chronic suppurative otitis media



Rakesh Sharma<sup>1</sup>, Sunil Kumar<sup>2</sup>

<sup>1</sup>Associate Professor, <sup>2</sup>Audiologist, Department of ENT, Government Medical College, Kathua, Jammu and Kashmir, India

Submission: 28-02-2022

Revision: 12-03-2022

Publication: 01-07-2022

## ABSTRACT

**Background:** Chronic suppurative otitis media has been acknowledged as a conspicuous pathology affecting the middle ear since times immemorial. **Aims and Objectives:** The aim of the study was to study the incidence of ossicular involvement and various patterns of its presentation in chronic suppurative otitis media. **Materials and Methods:** With the objective to study the incidence and pattern of ossicular involvement in chronic suppurative otitis media and also to correlate the various ossicular defects with the type and extent of the disease, we decided to take up this study at our institute. The study involved a total of 100 patients between February 2020 and June 2021. **Results:** Among the 100 patients included in this study, there were 56 males and 44 females. Among the 100 patients in this study, there were 54 tubotympanic and 46 atticoantral chronic suppurative otitis media patients. Among the tubotympanic cases, ossicular involvement was discovered in 18 cases while 36 cases were without any ossicular involvement. Among the atticoantral cases, 38 cases had ossicular involvement while eight cases had no ossicular disruption. Out of the 56 cases that showed ossicular involvement, incus was involved in 52 cases, malleus was involved in 14 cases, and stapes was involved in 10 cases. **Conclusion:** Ossicular involvement was seen in 53% of the operated cases of chronic suppurative otitis media. Atticoantral disease is 3 times more prone to having ossicular erosion than tubotympanic disease. Wet ears have 6 times more likelihood of having ossicular involvement in comparison to dry ears. Incus is the most common ossicle involved followed by malleus and stapes. Erosion of the incudal long process is the most common abnormality. Incus is invariably involved in atticoantral disease. Stapes involvement in the form of resorption of the arch of stapes is the most common pattern. An eroded long process along with stapes arch resorption is the most frequent ossicular chain defect.

**Key words:** Atticoantral; Chronic suppurative otitis media; Incus; Malleus; Ossicles; Stapes; Tubotympanic

## INTRODUCTION

Chronic suppurative otitis media has been acknowledged as a conspicuous pathology affecting the middle ear since times immemorial. It has also been acknowledged since ages that the ear ossicles are likely to get involved in chronic suppurative otitis media.

Schwartz (1893) observed ossicular caries especially in chronic suppurative otitis media involving the attic.<sup>1</sup>

Dingley and Zweifach (1954)<sup>2</sup> reported that incus involvement was more in attic cholesteatoma and malleus

was affected more often in other forms of chronic suppurative otitis media.

Austin (1971)<sup>3</sup> had highlighted ossicular involvement in half of the operated ears with chronic suppurative otitis media.

Openheimer and Harrison (1963)<sup>4</sup> had observed that the loss of lenticular process of incus was the most common pattern of disruption. They opined that its restoration resulted in maximum closure of the air bone gap.

Tos (1979)<sup>5</sup> had noticed similar ossicular erosions in 80% of discharging and 50% of dry ears. Tos had studied

### Access this article online

**Website:**

<http://nepjol.info/index.php/AJMS>

**DOI:** 10.3126/ajms.v13i7.43536

**E-ISSN:** 2091-0576

**P-ISSN:** 2467-9100

Copyright (c) 2022 Asian Journal of Medical Sciences



This work is licensed under a Creative Commons Attribution-NonCommercial 4.0 International License.

### Address for Correspondence:

Dr. Rakesh Sharma, Associate Professor, Department of ENT, Government Medical College, Kathua, Jammu and Kashmir, India.

**Mobile:** + 91-9419111447. **E-mail:** drrakishsharma@gmail.com

110 operated ears including 42 with cholesteatoma. He observed a significant differences in the pattern and incidence of ossicular defects. Defects of malleus head and incus were mostly observed in cholesteatomas. Defects of incus long process were observed in 74–88% of ears with cholesteatomas. Stapedial defects were seen in 47% of cases of sinus cholesteatomas. In chronic suppurative otitis media without cholesteatoma, the incidence of ossicular erosion was lesser with 57% having intact ossicles.

On the other hand, Sade and Berco (1981)<sup>6</sup> suggested that squamous epithelium did not cause bone erosion and in fact, they concluded that dry stratified squamous epithelium in absence of increased pressure was safe, thus confirming Baron's concepts (1977).<sup>7</sup>

Mathur et al., (1991)<sup>8</sup> reported long process of incus to be the most commonly affected structure in unsafe chronic suppurative otitis media.

Udaipurwala et al., (1994)<sup>9</sup> had reported involvement of more than one ossicle in majority of their patients.

Chronic suppurative otitis media happens to be one of the common ear pathologies presenting to an otologist. This certainly seems to be the scenario, in our part of the world. However, given the fact that a large section of society belongs to lower socioeconomic strata and as such take ear complaints more casually, thereby delaying medical consultation and hastening more extensive ossicular involvement.

Keeping this in mind, we decided to conduct the study titled "Pattern of ossicular chain involvement in chronic suppurative otitis media" in the Department of Otorhinolaryngology at Government Medical College, Kathua, Jammu, J and K. The study would also aid us in predicting the possible ossicular erosion patterns in chronic suppurative otitis media thereby enabling us to equip ourselves with various ossicular reconstruction tools and measures.

### Aims and objectives

The aim of the study was to study the incidence of ossicular involvement and various patterns of its presentation in chronic suppurative otitis media.

## MATERIALS AND METHODS

With the objective to study the pattern of ossicular involvement in chronic suppurative otitis media and also to correlate the various ossicular defects with the type and extent of the disease, we decided to take up this study at our institute. The study involved a total of 100 patients

between February 2020 and June 2021. The study was done at the Department of ENT at Government Medical College, Kathua, Jammu, J and K.

This was a prospective study and only those patients who were to be operated on for the 1<sup>st</sup> time were included in this study. Those patients with history of the previous ear surgery were excluded from the study as the ossicular lesions could be an outcome of the previous surgery.

An informed written consent was obtained from the patients. The ones who refused to sign the informed consent were excluded from the study.

The study involved 56 cases of tubotympanic chronic suppurative otitis media and 44 atticointral variety of chronic suppurative otitis media. A detailed history was recorded and a thorough local examination was performed which included examination under microscope. Routine investigations required for general or local anesthesia were carried out. All the patients had their X-ray mastoids and pure tone audiograms done. Pre-operative findings observed under the microscope were noted in detail. The pre-operative findings, approach used, cholesteatoma, granulations, retraction pockets, and other findings were also noted in detail. The status of ossicles was also examined in detail and their continuity confirmed. Whenever involved, the extent of ossicular erosions was thoroughly examined and recorded. The type of surgical technique used for disease clearance and ossicular reconstruction was also noted in detail.

## RESULTS

Among the 100 patients included in this study, there were 56 males and 44 females (Figure 1).

The most common age group being 15–30 years in both the genders (81%), followed by 10% belonging to 1–15 years age group, 6% belonging to above 30–45 years age group, and 3% patients belonged to 45–60 years age group (Figure 2).

The study group included 90 adults and 10 children.

About 70% patients were from a poor socioeconomic background.

The most common presenting complaint among the study group was otorrhea (92%), followed by reduced hearing ability (88 patients%). In 8% of the patients, there was no history of otorrhea and in 12% of our patients, there was no complaint of reduced hearing. Vertigo was present in 4% patients, headache was present in 1%, and tinnitus was present in 3% of the patients (Figure 3).

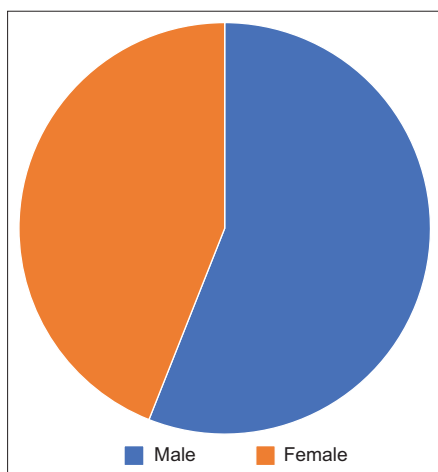


Figure 1: Gender distribution

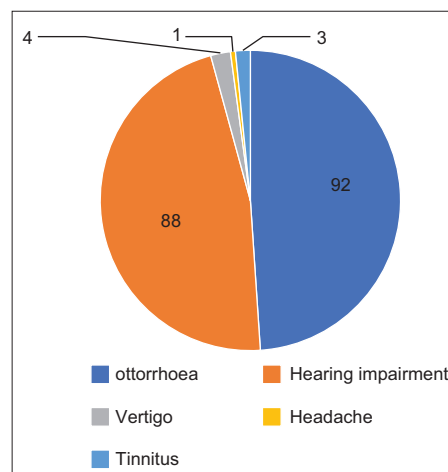


Figure 3: Incidence of various symptoms

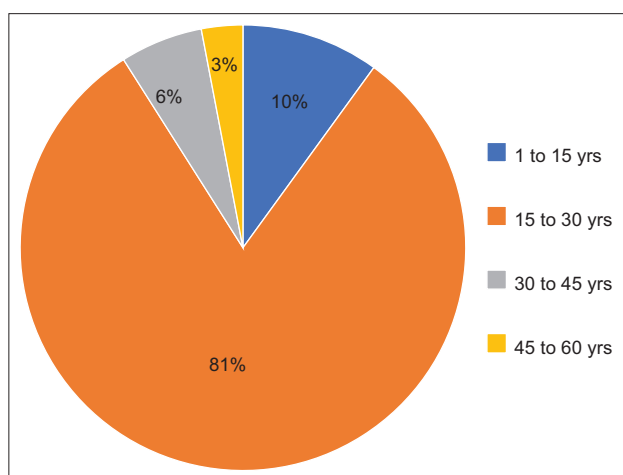


Figure 2: Age distribution

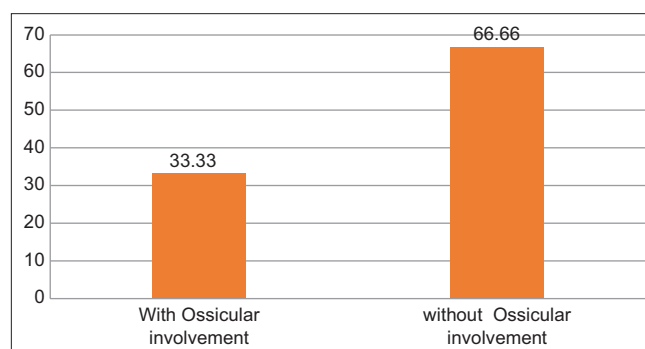


Figure 4: Ossicular involvement in TT type CSOM

Amongst the 100 patients in our study 54% of the patients had a wet ear while 46% were having a dry ear.

Among the 100 patients in this study, there were 54 tubotympanic and 46 atticoantral chronic suppurative otitis media patients.

Out of the 54 tubotympanic cases with a central perforation, 38 (70.3%) were with a large perforation, 7 (12.96%) with a moderate, 5 (9.25%) with small perforation, and 4 patients (7.40%) with a subtotal perforation.

Out of the 46 atticoantral cases, 36 (78.26%) were primary acquired variety and 10 cases (21.73%) were of secondary acquired variety.

Among the tubotympanic cases, ossicular involvement was discovered in 18 cases (33.33%) while 36 cases (66.66%) were without any ossicular involvement (Figure 4).

Among the atticoantral cases, 38 cases (82.6%) had ossicular involvement while 8 cases (17.3%) had no ossicular disruption (Figure 5).

Out of the 56 cases that showed ossicular involvement, incus was involved in 52 cases (92.8%), malleus was involved in 14 cases (25%), and stapes was involved in 10 cases (17.8%) (Figure 6).

Among the 52 cases of incus involvement, long process was eroded in 40 patients (76.92%), body was eroded in 3 cases (5.76%), and incus was missing in 9 patients (17.30%) (Figure 7).

Among the 14 cases of malleus involvement, handle was eroded in 6 cases (42.85%), handle was missing in 5 cases (35.71%), and malleus was missing in 3 cases (21.42%) (Figure 8).

Among the 10 cases of stapedial involvement, head was missing in 6 cases (60%), resorption of stapedial arch was seen on 3 cases (30%), and stapes was totally missing in one patient (10%) (Figure 9).

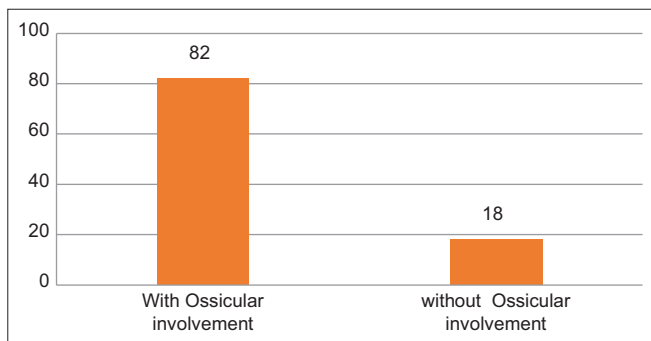


Figure 5: Ossicular involvement in AA type CSOM

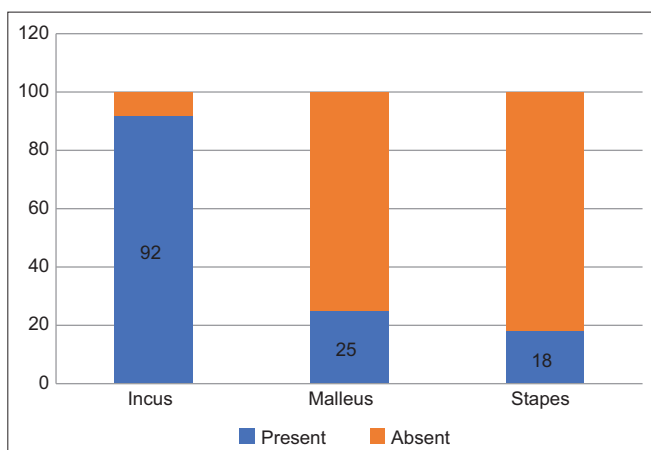


Figure 6: Relative incidence of ossicle involvement

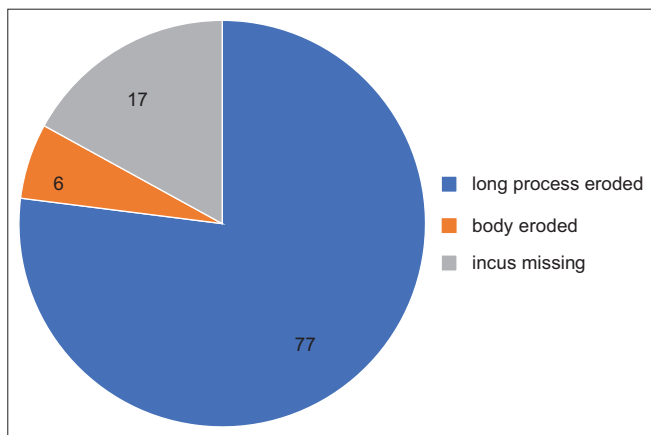


Figure 7: Incidence of involvement of different parts of incus

## DISCUSSION

As late as the later part of the 20<sup>th</sup> century, the ossicular erosion in the middle ear was thought primarily to be an outcome of pressure or some adverse effect of squamous epithelium.<sup>10</sup> However, in 1970's, certain studies sought to shift the focus on the fact that ossicular erosion was not just observed in cholesteatomatous ears and also that the squamous epithelium was not always accompanied by

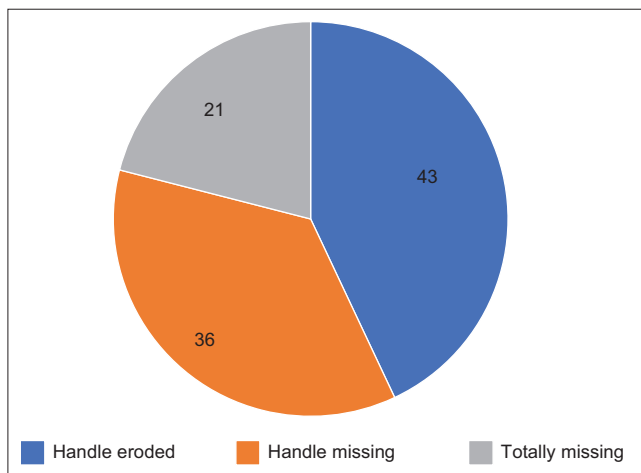


Figure 8: Incidence of involvement of different parts of malleus

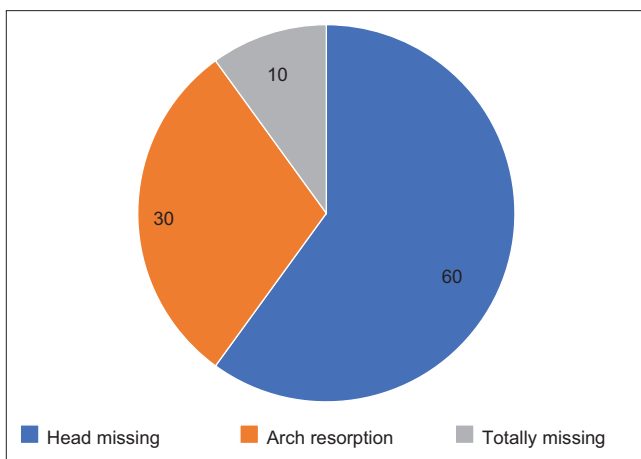


Figure 9: Incidence of involvement of different parts of stapes

erosion of bone. Furthermore, that inflammatory process was seen in all such ossicular erosions.<sup>11-13</sup>

As per Sade et al.,<sup>11</sup> the process of erosion of ear ossicles was multifactorial and that it was seemingly unrelated to the squamous epithelium.

Tos (1979)<sup>5</sup> had reported that squamous epithelium was present close to the eroded ossicles and that the squamous epithelium must have a significant influence on bone resorption.

Sade et al., (1981)<sup>6</sup> had reported a higher frequency of ossicular erosion in cases older than 30 years than in case of <30 years old. The basis could have been the duration of the presence of disease itself. On that premise, we expected more severe ossicular involvement given the delay in seeking medical opinion in our setting.

Keeping these factors in mind, the study was conducted by us wherein 100 patients with chronic suppurative otitis

media were operated on at our institute over a period of 1 year.

Among the 100 cases, the number of males was higher than the females. The majority of the cases were of 15–30 year age group. The most common presenting complaint among the study group was otorrhea (92 patients), followed by reduced hearing ability (88 patients). In eight patients, there was no history of otorrhea and in 12 of our patients, there was no complaint of reduced hearing. Vertigo was present in four patients, headache was present in one, and tinnitus was present in three patients.

The fact that among the 46 atticofacial cases, the absence of otorrhea in four cases does highlight the paucity of symptoms in such cases and warrants greater caution.

At the time of admissions, 46 patients had dry ear. This could be due to the fact that the patients had been given antibiotics both local and systemic as treatment before admission for surgery.

The various surgeries that the patients underwent included tympanoplasty (10 cases), cortical mastoidectomy (43 cases) with tympanoplasty, and modified radical mastoidectomy (47 cases).

The incidence of ossicular erosion was found to be 56. This was in sync with the observation of Austin (1971)<sup>3</sup> who had reported 50% involvement.

In our study, the incidence of ossicular involvement was higher in atticofacial variety (82%) in comparison to the tubotympanic variety (33%). Sade et al.,<sup>11</sup> found a similar incidence (84%) in atticofacial cases but they reported a higher incidence in tubotympanic cases (42%).

The incidence of ossicular involvement in atticofacial variety was reported as 82% by Sade et al., (1981) 80% by Sade et al.,<sup>11</sup> and Halevy and Sade (1974),<sup>14</sup> and 82.3% by Tos (1979),<sup>5</sup> respectively. This was more or less similar to our findings.

Sade et al., (1981)<sup>11</sup> had dedicated higher incidence of ossicular erosion in atticofacial disease to the granulation tissue being in firm contact with the ossicles and that the pocket formed was ideal for bacteria to thrive. Tos (1979)<sup>5</sup> on the contrary had concurred with the prior anoxia-necrosis leading to bone resorption in chronic suppurative otitis media.<sup>15,16</sup> This was premised on the direct pressure by the cholesteatoma sac on the bone.

The higher incidence of ossicular erosion in wet ears in comparison to the dry ears was found to be 6 times more.

Quite in line with the findings of Sade et al.,<sup>11</sup> who reported 5 times higher incidence in wet compared to dry ears.

In our study, the incidence of ossicular involvement was 53% in below 30 age group and 65% in higher age group. Similar reporting was done by Sheehy (1977)<sup>17</sup> and Sade et al., (1981).<sup>11</sup> They had concluded that the greater the time the inflammatory process lasted, more was the likelihood of ossicular damage.

In our study, we also observed that the incidence of ossicular involvement was higher in larger perforations. This was especially the case in the perforations that involved the posterosuperior quadrant. Sade et al., thought this to be an outcome of the location of the inflammatory process to the ossicular chain.

In our study, incus was the most common ossicle involved (53% of all cases). Malleus was involved in 14% and stapes in 9% of all cases. The destruction of the long process of incus was the most common anomaly found in the operated cases (41%). Tos (1979)<sup>5</sup> and Mathur et al., (1991)<sup>8</sup> had reported a higher incidence of incus long process involvement. This could be due to the reason that their study did not include safe chronic otitis media cases. Mathur et al., (1991) had related the finding to a rather precarious blood supply of the incudal long process.

Malleus involvement was seen in 21% cases of atticofacial and 7% cases of tubotympanic cases.

The most frequent combined ossicular chain deformity was long process along with resorption of the arch of stapes (4%). This was followed by absent incus along with resorption of arch of stapes (2%). Malleus head erosion in addition to erosion of long process of incus was also observed in 2% of the cases.

Austin (1971)<sup>3</sup> had reported the long process erosion as the most common defect (39% cases). We also observed in our study that in a patient undergoing tympanoplasty, the chances of encountering an eroded incus in isolation were higher than in those case who underwent mastoidectomy.

### Limitations of the study

Since majority of the patients in our study belong to 15-30 years age group, it might be challenging to generalize the observations to those beyond this age group.

## CONCLUSION

- Ossicular involvement was seen in 56% of the operated cases of chronic suppurative otitis media.

- Atticoantral disease is 3 times more prone to having ossicular erosion than tubotympanic disease.
- Wet ears have a 6 times more likelihood of having ossicular involvement in comparison to dry ears.
- Incus is the most common ossicle involved followed by malleus and stapes.
- Erosion of the incudal long process is the most common abnormality.
- Incus is invariably involved in atticoantral disease.
- Stapes involvement in the form of resorption of the arch of stapes is the most common pattern.
- An eroded long process along with stapes arch resorption is the most frequent ossicular chain defect.

## ACKNOWLEDGMENT

We offer our deepest regards and gratitude to Dr. Suleiman Choudhary, Principal, Govt. Medical College, Kathua, for providing excellent scientific guidance and moral support throughout our study.

We are also immensely grateful and indebted to our patients for their understanding and cooperation in making the study successful.

## REFERENCES

1. Schwartz H. Pathology of ossicles in chronic otitis media. *Arch Otolaryngol.* 1959; 70(4):421-435.
2. Dingley AR and Zweifach E. Pathology of ossicles in chronic otitis media. *Arch Otolaryngol.* 1959;70(4):421-435.
3. Austin DF. Ossicular reconstruction archives of otolaryngology. *Arch Otolaryngol.* 1971;94(6):525-535.  
<https://doi.org/10.1001/archotol.1971.00770070825007>
4. Openheimer P and Harrison W. The missing lenticular process. *Arch Otolaryngol.* 1963;78:143-150.
5. Tos M. Pathology of ossicular chain in various chronic middle ear diseases. *J Laryngol Otol.* 1979;93(8):769-780.  
<https://doi.org/10.1017/s0022215100087703>
6. Sade J and Berco E. Bone destruction in chronic otitis media. *J Laryngol Otol.* 1974;88(5):413-422.  
<https://doi.org/10.1017/s0022215100078889>
7. Baron SH. Experiences with surgery of aural cholesteatoma, a case of sudden deafness. In: *Proceedings of 1<sup>st</sup> International Conference on Cholesteatoma.* Brihingham, Alabama: Aesculapius Publication Company; 1977. p. 368-373.
8. Mathur NN, Kakkar P, Singh T and Sawhney KL. Ossicular pathology in unsafe chronic suppurative otitis media. *Indian J Otolaryngol.* 1991;43:9E12.
9. Udaipurwala IH, Iqbal K and Saqualin M. Pathological profile in chronic suppurative otitis media, the regional experience. *J Pak Med Assoc.* 1994;44(10):235-237.
10. Walsh TE, Covell WP, Ogura JH. Ossicular damage in chronic middle ear inflammations. *Acta Otolaryngol.* 1981;92(3-4):273-283.  
<https://doi.org/10.3109/00016488109133263>
11. Sade J, Berco E, Bugnover D and Brown M. Ossicular damage in chronic middle ear inflammations. *Acta Otolaryngol.* 1981;92(3-4):273-283.  
<https://doi.org/10.3109/00016488109133263>
12. Thomson J, Jorgensen MB, Bretlau P and Kristensen HK. Bone resorption in chronic otitis media. A histological and ultrastructural study. I. Ossicular necrosis. *J Laryngol Otol.* 1974;88(10):975.  
<https://doi.org/10.1017/s0022215100079639>
13. Tanaka K, Terayama Y and Hirai T. Electron microscopic study of bone lesions in cholesteatoma. *Arch Otorhinolaryngol.* 1980;226:85-92.
14. Halevy A and Sade J. The aetiology of bone destruction in chronic otitis media. *J Laryngol Otol.* 1974;88(2):139-143.  
<https://doi.org/10.1017/s0022215100078476>
15. Ruedi L. Pathogenesis and treatment of cholesteatoma in chronic suppuration of the temporal bone. *Ann Otorhinolaryngol.* 1957;66(2):283-305.
16. Tumarkin A. Bone resorption in chronic otitis media. *Acta Otolaryngol.* 1985;100(1-2):72-80.
17. Sheehy et al. Cholesteatoma Surgery: Residual and Recurrent Disease: A Review of 1,024 cases. *Annals of Otolaryngology, Rhinology & Laryngology,* 1977. July- Aug: 451-62  
<https://doi.org/10.3109/00016488509108590>

### Authors' Contributions:

**RS-** Prepared the concept and design of the study, first draft of manuscript, interpreted the results; reviewed the literature and manuscript preparation, statistical analysis and interpretation, and revision of the manuscript and **SK-** Data collection and investigations

### Work attributed to:

Government Medical College, Kathua, Jammu and Kashmir, India

### Orcid ID:

Dr. Rakesh Sharma - <https://orcid.org/0000-0002-7446-5471>

Mr. Sunil Kumar - <https://orcid.org/0000-0001-9142-6151>

**Source of Funding:** None, **Conflicts of Interest:** None.