

# Recurrent atraumatic subdural hematoma with pregnancy – An unusual case



Sibaji Dasgupta<sup>1</sup>, Sourabh Guria<sup>2</sup>

<sup>1</sup>Assistant Professor, <sup>2</sup>NSPDT, Bangur Institute of Neurosciences, IPGME and R and SSKM Hospital, Kolkata, West Bengal, India

Submission: 27-02-2022

Revision: 29-05-2022

Publication: 01-07-2022

## ABSTRACT

Atraumatic subdural hematoma (SDH) is a rare occurrence in neurosurgery practice. Such a case in pregnancy is also very rare. Here, we present a case of 33 weeks pregnant female presented with SDH which was operated and there was recurrence of similar hematoma in the same patient in the postpartum period. The primary cause in both the hematomas was unknown, but a pregnancy related or other risk factors may be responsible for causation of the hematomas in this case.

**Key words:** Atraumatic subdural hematoma; Pregnancy; Craniostomy

### Access this article online

**Website:**

<http://nepjol.info/index.php/AJMS>

**DOI:** 10.3126/ajms.v13i7.43408

**E-ISSN:** 2091-0576

**P-ISSN:** 2467-9100

Copyright (c) 2022 Asian Journal of Medical Sciences



This work is licensed under a Creative Commons Attribution-NonCommercial 4.0 International License.

## INTRODUCTION

Atraumatic subdural hematoma (SDH) is a rare finding. Limited case reports are available in the literature. Some described causes of atraumatic SDH include ruptured aneurysm, arteriovenous malformations, preeclampsia, cocaine abuse, and severe coagulopathy. Here, we have presented an interesting case of atraumatic SDH in the third trimester of pregnancy, along with recurrence in the postpartum period.

## CASE REPORT

A 34-year-old female, second gravida at 34 weeks of gestation with breech presentation, came to the emergency with sudden onset of severe right-sided headache along with several episodes of vomiting. There was no history of trauma, hypertension, pre-eclampsia, antiplatelet,

or anticoagulant therapy. She had history of papillary carcinoma of thyroid, for which total thyroidectomy was done 3 years back and was followed with regular thyroid hormone supplementation.

At the time of admission, her pulse rate, blood pressure, and respiratory parameters were within normal limits. Neurological examination showed presence of pronator drift on the left side of body. Plain magnetic resonance imaging (MRI) of brain (Figure 1) showed right frontotemporoparietal subacute SDH with mass effect. Blood parameters showed mild thrombocytopenia (80,000 per microliter). After proper counseling and taking consent right parietal, burr hole craniostomy and evacuation of SDH were done. Postoperatively, the patient had significant decrease in headache along with improvement in neurological sign. Post-operative MRI of brain (Figure 2) showed adequate evacuation of the right-sided SDH with

### Address for Correspondence:

Dr. Sourabh Guria, MS, NSPDT, Bangur Institute of Neurosciences, IPGME & R and SSKM Hospital, Kolkata - 700 020, West Bengal, India. **Phone:** +91-9439650561. **E-mail:** [sourabhguria@gmail.com](mailto:sourabhguria@gmail.com)

decrease in mass effect. She was discharged in a better state. Later, she delivered baby following caesarean section under epidural anesthesia.

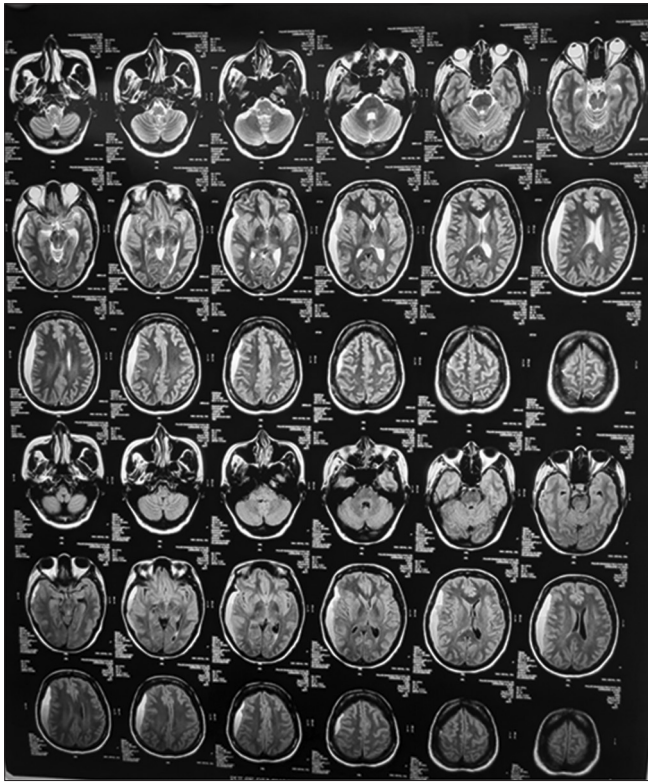


Figure 1: First occurrence of SDH

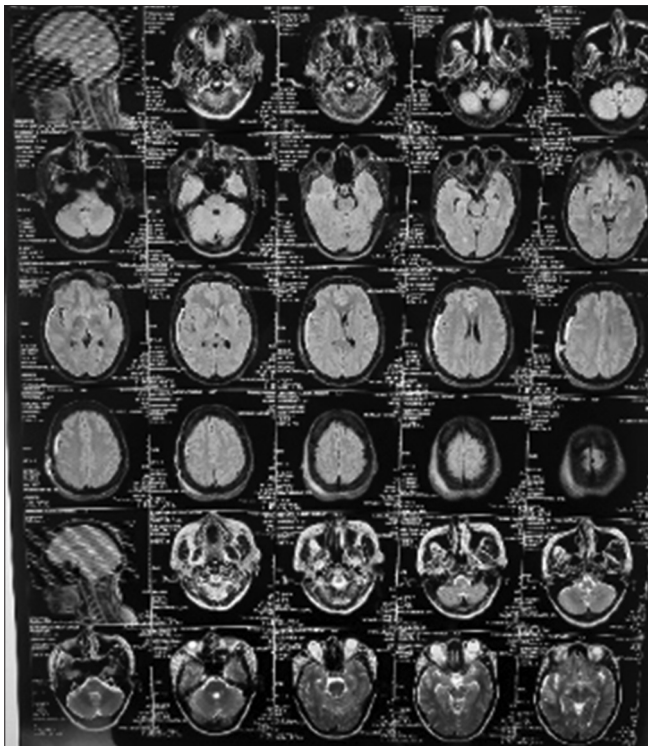


Figure 2: First post-operative magnetic resonance imaging

Approximately 7 days after delivery, she again came with sudden development of spontaneous severe headache for 4 days, along with vomiting. On examination, she presented with bradycardia, while other neurological parameters were normal. Blood reports showed no significant abnormality. Plain computed tomography (CT) scan of brain (Figure 3) showed recurrent subacute SDH over right frontotemporoparietal region with mass effect. Again counseling was done and consent for surgery was taken and she underwent right frontal burr hole craniostomy and evacuation of clot. With the subsidence of headache along with evidence of adequate evacuation of SDH in CT brain in the post-operative period, the patient was discharged in a better clinical condition.

## DISCUSSION

Intracranial hemorrhage occurs in 0.01–0.05% of pregnancies. The aneurysm or arteriovenous malformations are the most common causes of intracranial hemorrhage. Pregnancy-induced hypertension is also a factor of intra parenchymal hemorrhage.<sup>1</sup> In addition, the pregnant patient undergoes some physiological hormonally mediated changes in circulation, vascular tissue structure, and coagulability, all of which can contribute to further increased risk of stroke and bleeds.<sup>2,3</sup> Some cases subdural hematoma resulting from a head injury during pregnancy has been reported.<sup>4</sup> Other cases of subdural hematoma have been reported in postpartum in association with epidural anesthesia. The clinical symptoms described in these patients in postpartum presented by: headache, dizziness, disorientation, memory loss, ophthalmoplegia, papilledema, stupor, coma, and psychosis. The onset of these symptoms varies from the first to the 4<sup>th</sup> day after delivery.<sup>5</sup>

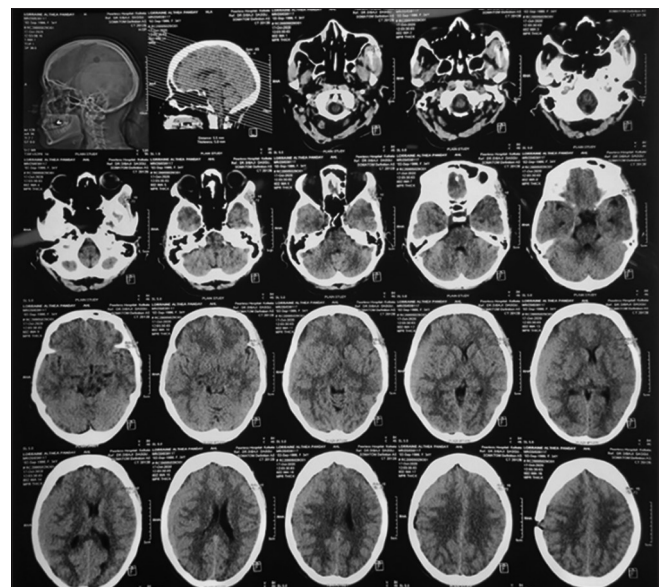


Figure 3: Recurrent SDH in postpartum period

In this case without any direct cause, the pregnancy-induced physiological changes and thrombocytopenia may be responsible for the first occurrence of SDH. A previous study has also been found, which supports such probability.<sup>6</sup> The recurrent SDH in the postpartum period can be possible as sequelae to epidural anesthesia during cesarean section.

## CONCLUSION

Although SDHs occur rarely in pregnancy or in the postpartum period, the clinician should always consider such possibility if a patient presents with the typical symptoms and signs or with probable above-discussed backgrounds. The absence of trauma does not exclude such possibility. As this situation can effect both mother and fetus, care must be taken to detect these early and treat them effectively.

## REFERENCES

1. Sharshar T, Lamy C and Mas JL. Incidence and causes of strokes associated with pregnancy and puerperium: A study in public hospitals of Ile de France. *Stroke in Pregnancy Study Group. Stroke.* 1995;26(6):930-936.  
<https://doi.org/10.1161/01.str.26.6.930>
2. Feske SK. Stroke in pregnancy. *Semin Neurol.* 2007; 27(5):442-452.  
<https://doi.org/10.1055/s-2007-991126>
3. Yokota H, Miyamoto K, Yokoyama K, Noguchi H, Uyama K and Oku M. Spontaneous acute subdural haematoma and intracerebral haemorrhage in patient with HELLP syndrome: Case report. *Acta Neurochir (Wien).* 2009;151(12):1689-1692.  
<https://doi.org/10.1007/s00701-009-0300-y>
4. Amias AG. Cerebral vascular disease in pregnancy. I. Haemorrhage. *J Obstet Gynaecol Br Commonw.* 1970;77(2):100-120.  
<https://doi.org/10.1111/j.1471-0528.1970.tb03487.x>
5. Vaughan DJ, Stirrup CA and Robinson PN. Cranial subdural haematoma associated with dural puncture in labour. *Br J Anaesth.* 2000;84(4):518-520.  
<https://doi.org/10.1093/oxfordjournals.bja.a013483>
6. Giannina G, Smith D, Belfort MA and Moise KJ Jr. Atraumatic subdural hematoma associated with pre-eclampsia. *J Matern Fetal Med.* 1997;6(2):93-95.  
[https://doi.org/10.1002/\(sici\)1520-6661\(199703/04\)6:2%3C93:aid-mfm5%3E3.0.co;2-k](https://doi.org/10.1002/(sici)1520-6661(199703/04)6:2%3C93:aid-mfm5%3E3.0.co;2-k)

### Authors' Contributions:

**SD-** Review of manuscript and treating neurosurgeon; **SG-** Manuscript preparation, revision of manuscript, concept and design, and resident in charge

### Work attributed to:

Bangur Institute of Neurosciences, IPGME & R and SSKM Hospital, Kolkata - 700 020, West Bengal, India

### Orcid ID:

Sibaji Dasgupta - <https://orcid.org/0000-0002-2275-3519>

Sourabh Guria - <https://orcid.org/0000-0001-7350-1808>

**Source of Support:** Nil, **Conflicts of Interest:** None declared.